A 46-year-old woman comes to the emergency department due to 3 days of persistent upper abdominal pain, nausea, and vomiting. The patient has had similar pain in the past, especially after fatty meals, which resolved spontaneously within several hours. Temperature is 38.6 C (101.5 F), blood pressure is 110/65 mm Hg, and pulse is 98/min. BMI is 33 kg/m^2. Physical examination is notable for severe right upper quadrant tenderness. Leukocyte count is 21,000/mm^3. Laparoscopic surgery is performed and reveals an erythematous, distended gallbladder with patchy necrosis. Which of the following events most likely initiated this patient's condition?

- A. Bacterial invasion of the gallbladder wall
- B. Cystic artery thrombosis
- C. Gallbladder outflow obstruction
- D. Ischemic disruption of the mucosal layer
- E. Lecithin hydrolysis and mucosal damage

Submit

A 46-year-old woman comes to the emergency department due to 3 days of persistent upper abdominal pain, nausea, and vomiting. The patient has had similar pain in the past, especially after fatty meals, which resolved spontaneously within several hours. Temperature is 38.6 C (101.5 F), blood pressure is 110/65 mm Hg, and pulse is 98/min. BMI is 33 kg/m^2. Physical examination is notable for severe right upper quadrant tenderness. Leukocyte count is 21,000/mm^3. Laparoscopic surgery is performed and reveals an erythematous, distended gallbladder with patchy necrosis. Which of the following events most likely initiated this patient's condition?

- A. Bacterial invasion of the gallbladder wall (11%)
- B. Cystic artery thrombosis (1%)
- ✓ C. Gallbladder outflow obstruction (81%)
- D. Ischemic disruption of the mucosal layer (4%)
- E. Lecithin hydrolysis and mucosal damage (1%)

Omitted
Correct answer
C

81%
Answered correctly

03 secs
Time Spent

05/20/2020
Last Updated

Explanation

This patient likely has **acute calculous cholecystitis**, an acute inflammation of the gallbladder initiated by **gallstone obstruction** of the **cystic duct**. Patients typically present with persistent right upper quadrant pain, fever, and leukocytosis. Examination classically shows Murphy sign, an inspiratory pause elicited by pain during deep palpation of the right upper quadrant. Symptoms are often preceded by transient episodes of abdominal pain and nausea after fatty meals due to temporary cystic duct obstruction (biliary colic).

Explanation

This patient likely has **acute calculous cholecystitis**, an acute inflammation of the gallbladder initiated by **gallstone obstruction** of the **cystic duct**. Patients typically present with persistent right upper quadrant pain, fever, and leukocytosis. Examination classically shows Murphy sign, an inspiratory pause elicited by pain during deep palpation of the right upper quadrant. Symptoms are often preceded by transient episodes of abdominal pain and nausea after fatty meals due to temporary cystic duct obstruction (biliary colic).

Persistent gallbladder outflow obstruction promotes hydrolysis of luminal lecithins to lysolecithins, which disrupts the protective mucus layer. The luminal epithelium is then exposed to the detergent action of the bile salts, resulting in chemical irritation and prostaglandin release. Inflammation of the mucosa and deeper tissues causes gallbladder hypomotility. The increasing distension and internal pressure within the gallbladder eventually result in ischemia. Finally, bacteria (eg, *Escherichia coli*, *Enterococcus*, *Klebsiella*, *Enterobacter*) invade the injured and necrotic gallbladder wall, causing an infection **(Choice A)**.

(Choices B and D) The gallbladder is vulnerable to ischemic injury as the cystic artery lacks collateral circulation. Although inflammation/edema of the gallbladder may compromise blood flow, ischemic disruption of the mucosal layer is usually the next to last step in the pathogenesis of acute calculous cholecystitis. Gallbladder ischemia is not typically caused by cystic artery thrombosis.

(Choice E) Lecithin hydrolysis and mucosal damage occur after gallbladder outflow obstruction in the pathogenesis of acute calculous cholecystitis.

Educational objective:
Acute calculous cholecystitis is an acute inflammation of the gallbladder initiated by gallstone obstruction of the cystic duct. Subsequent steps in pathogenesis include mucosal disruption by lysolecithins, bile salt irritation of the luminal epithelium, prostaglandin release with transmural inflammation, gallbladder hypomotility, increased intraluminal pressure causing ischemia, and bacterial invasion.

References

- Acute cholecystitis.

Pathology	Gastrointestinal & Nutrition	Cholecystitis
Subject	System	Topic

duct. Patients typically present with persistent right upper quadrant pain, fever, and leukocytosis. Examination classically shows Murphy sign, an inspiratory pause elicited by pain during deep palpation of the right upper quadrant. Symptoms are often preceded by transient episodes of abdominal pain and nausea after fatty meals due to temporary cystic duct obstruction (biliary colic).

Persistent gallbladder outflow obstruction promotes hydrolysis of luminal lecithins to lysolecithins, which disrupts the protective mucus layer. The luminal epithelium is then exposed to the detergent action of the bile salts, resulting in chemical irritation and prostaglandin release. Inflammation of the mucosa and deeper tissues causes gallbladder hypomotility. The increasing distension and internal pressure within the gallbladder eventually result in ischemia. Finally, bacteria (eg, *Escherichia coli*, *Enterococcus*, *Klebsiella*, *Enterobacter*) invade the injured and necrotic gallbladder wall, causing an infection **(Choice A)**.

(Choices B and D) The gallbladder is vulnerable to ischemic injury as the cystic artery lacks collateral circulation. Although inflammation/edema of the gallbladder may compromise blood flow, ischemic disruption of the mucosal layer is usually the next to last step in the pathogenesis of acute calculous cholecystitis. Gallbladder ischemia is not typically caused by cystic artery thrombosis.

(Choice E) Lecithin hydrolysis and mucosal damage occur after gallbladder outflow obstruction in the pathogenesis of acute calculous cholecystitis.

Educational objective:
Acute calculous cholecystitis is an acute inflammation of the gallbladder initiated by gallstone obstruction of the cystic duct. Subsequent steps in pathogenesis include mucosal disruption by lysolecithins, bile salt irritation of the luminal epithelium, prostaglandin release with transmural inflammation, gallbladder hypomotility, increased intraluminal pressure causing ischemia, and bacterial invasion.

References

- Acute cholecystitis.

Pathology	Gastrointestinal & Nutrition	Cholecystitis
Subject	System	Topic

Copyright © UWorld. All rights reserved.

A 46-year-old Caucasian male is being worked up for abdominal discomfort, loose stool and recent weight loss. Intestinal biopsy is performed and periodic acid-Schiff (PAS) reaction is used on the sample (see the slide below).

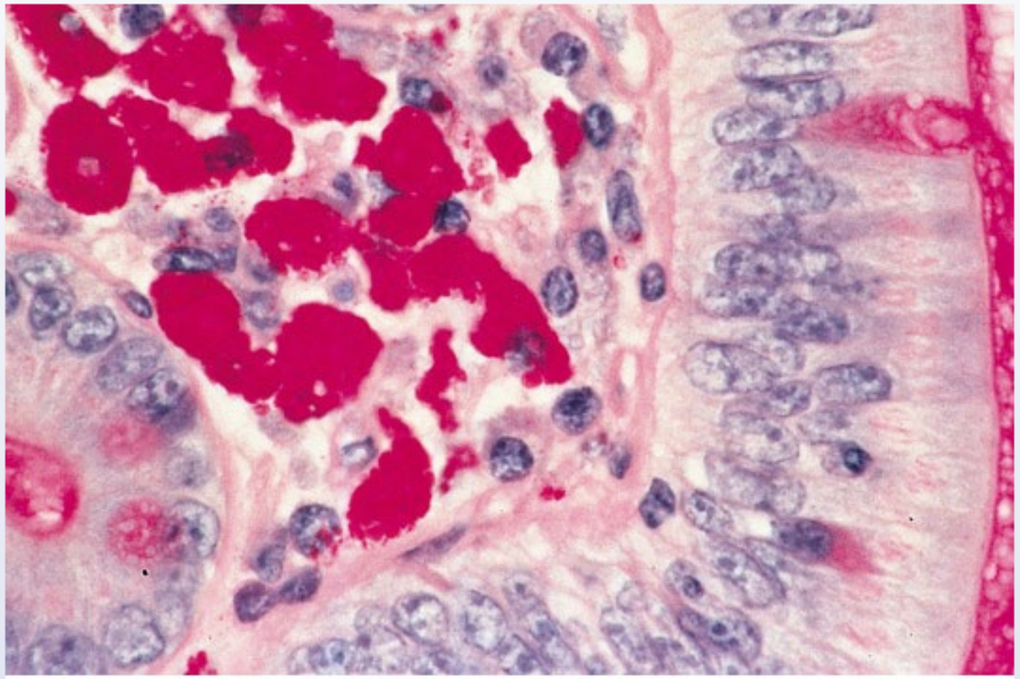

Displayed with permission from Springer Healthcare Ltd. © Copyright 1997, 2004 by Current Medicine

The intense pink discoloration demonstrated on the slide most likely indicates the presence of:

- A. Peroxidase
- B. Calcium
- C. Iron

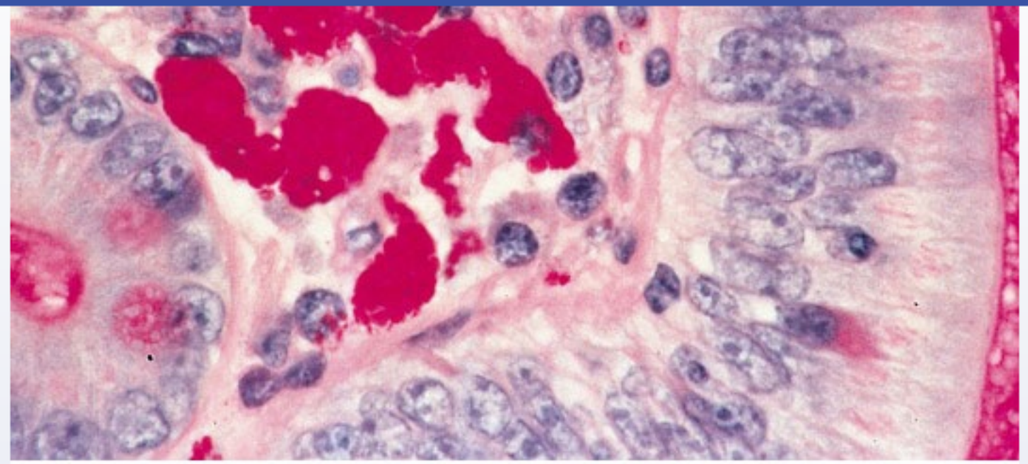

Displayed with permission from Springer Healthcare Ltd. © Copyright 1997, 2004 by Current Medicine

The intense pink discoloration demonstrated on the slide most likely indicates the presence of:

- A. Peroxidase
- B. Calcium
- C. Iron
- D. Neutral lipid
- E. Glycoprotein
- F. Alkaline phosphatase

Submit

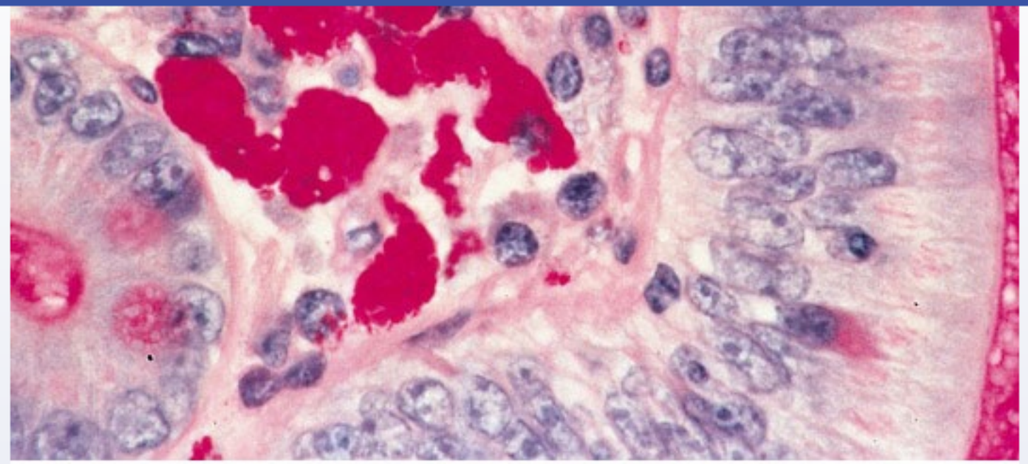

Displayed with permission from Springer Healthcare Ltd. © Copyright 1997, 2004 by Current Medicine

The intense pink discoloration demonstrated on the slide most likely indicates the presence of:

- A. Peroxidase (15%)
- B. Calcium (2%)
- C. Iron (6%)
- D. Neutral lipid (14%)
- ✓ E. Glycoprotein (57%)
- F. Alkaline phosphatase (3%)

Omitted
Correct answer

57%
Answered correctly

06 secs
Time Spent

02/03/2020
Last Updated

Explanation

The periodic acid-Schiff (PAS) reaction is used in histochemical staining because the periodic acid oxidizes carbon-carbon bonds, forming aldehydes that produce a brilliant magenta color upon reacting with the fuchsin-sulfurous acid. As a result, the PAS stain is particularly effective at highlighting polysaccharides of the fungal cell wall, mucosubstances secreted by epithelia, and basement membranes. Diastase can be used in conjunction with PAS to demonstrate glycogen, which is found in skin, liver, parathyroid, and skeletal/cardiac muscle. The diastase works by digesting glycogen to form maltose and glucose, two sugars that are easily washed from sections during processing (therefore giving a negative reaction).

The glycoprotein present in the cell walls of the gram-positive actinomycete *Tropheryma whippelii* appears magenta with PAS and is diastase-resistant, which makes this stain an excellent choice when microscopically evaluating small bowel mucosa for Whipple disease.

(Choice A) Peroxidase staining can be used to differentiate subtypes of acute leukemia, and horseradish peroxidase is useful in immunoblotting (eg, Western blot).

(Choice B) Calcium appears as a dark purple deposit on hematoxylin and eosin stain.

(Choice C) Iron appears blue with stains such as Prussian blue.

(Choice D) Neutral lipids can be identified with a multitude of stains, including Nile red or Sudan black (with the latter being useful for frozen sections).

(Choice F) Alkaline phosphatase is an enzyme marker of osteoblasts. Staining with this enzyme can be helpful in identifying bone tumors.

Educational Objective:
The glycoprotein in the cell walls of the actinomycete *Tropheryma whippelii* colors magenta with PAS and is diastase-resistant, making this stain an excellent choice in evaluating tissue for Whipple disease.

Pathology	Gastrointestinal & Nutrition	Whipple disease
Subject	System	Topic

Copyright © UWorld. All rights reserved.

A 6-year-old boy is brought to the ER due to confusion and intractable vomiting. These symptoms began a few hours ago and have been gradually worsening. The patient's mother tells you that the boy contracted a febrile illness from his younger brother two days ago. She states that she gave him "some over-the-counter pills" and it helped his fever. While you talk to the mother, the boy lapses into a coma. The light microscopy of his liver specimen will reveal:

- A. Apoptosis of hepatocytes
- B. Periportal inflammatory infiltration
- C. Microvesicular steatosis
- D. Centrilobular congestion
- E. Bile duct proliferation

Submit

A 6-year-old boy is brought to the ER due to confusion and intractable vomiting. These symptoms began a few hours ago and have been gradually worsening. The patient's mother tells you that the boy contracted a febrile illness from his younger brother two days ago. She states that she gave him "some over-the-counter pills" and it helped his fever. While you talk to the mother, the boy lapses into a coma. The light microscopy of his liver specimen will reveal:

A. Apoptosis of hepatocytes (25%)

B. Periportal inflammatory infiltration (15%)

✓ C. Microvesicular steatosis (46%)

D. Centrilobular congestion (12%)

E. Bile duct proliferation (0%)

Omitted
Correct answer
C

46%
Answered correctly

01 sec
Time Spent

04/02/2020
Last Updated

Explanation

Children with febrile illness treated with salicylates are at risk of developing Reye syndrome. Reye syndrome is characterized by hepatic failure and acute encephalopathy, and is most commonly associated with the use of **aspirin** in patients 5-14 years old. The febrile illness that preceeds Reye's syndrome is frequently an upper respiratory infection, influenza, measles, varicella or another viral disease. The pathogenesis of this condition is still unclear, but it is hypothesized that affected children have some inborn metabolic error that renders them sensitive to the toxic effects of salicylates. It is especially pronounced in viral-infected cells and causes mitochondrial dysfunction. The two components of Reye's syndrome include:

Explanation

Children with febrile illness treated with salicylates are at risk of developing Reye syndrome. Reye syndrome is characterized by hepatic failure and acute encephalopathy, and is most commonly associated with the use of **aspirin** in patients 5-14 years old. The febrile illness that preceeds Reye's syndrome is frequently an upper respiratory infection, influenza, measles, varicella or another viral disease. The pathogenesis of this condition is still unclear, but it is hypothesized that affected children have some inborn metabolic error that renders them sensitive to the toxic effects of salicylates. It is especially pronounced in viral-infected cells and causes mitochondrial dysfunction. The two components of Reye's syndrome include:

1. **Hepatic dysfunction** manifests with vomiting and hepatomegaly, but jaundice is rare. Liver function tests reveal increased levels of ALT, AST, ammonia, and bilirubin, and a prolonged PT and PTT. Light microscopy of a liver biopsy shows microvesicular steatosis, the presence of small fat vacuoles in the cytoplasm of hepatocytes **(Choice C)**. No necrosis or inflammation is present in the liver. Electron microscopy findings include swelling, a decreased number of mitochondria and glycogen depletion.

2. **Encephalopathy** of Reye syndrome is attributed to hepatic dysfunction and the toxic effect of hyperammonemia on the CNS leading to cerebral edema.

To avoid the possibility of inducing Reye syndrome, aspirin should not be administered to children under the age of sixteen except for very specific circumstances where it is indicated for the treatment of a serious illness such as in Kawasaki disease where salicylates are a mainstay of treatment.

(Choices A and B) Apoptosis of hepatocytes, acinar necrosis and periportal mononuclear inflammatory infiltration are the characteristic light microscopy findings of viral hepatitis caused by any of the hepatitis viruses.

(Choice D) Centrilobular congestion occurs in the liver of the patients with right-sided heart failure.

(Choice E) Primary biliary cirrhosis displays bile duct destruction, periductal granulomatous inflammation and bile duct proliferation.

Educational Objective:
Reye syndrome occurs in children with febrile illness treated with salicylates **(aspirin)**. It consists of hepatic failure and encephalopathy. The characteristic histological finding is microvesicular steatosis of hepatocytes without inflammation and cerebral edema.

effects of salicylates. It is especially pronounced in viral-infected cells and causes mitochondrial dysfunction. The two components of Reye's syndrome include:

1. **Hepatic dysfunction** manifests with vomiting and hepatomegaly, but jaundice is rare. Liver function tests reveal increased levels of ALT, AST, ammonia, and bilirubin, and a prolonged PT and PTT. Light microscopy of a liver biopsy shows microvesicular steatosis, the presence of small fat vacuoles in the cytoplasm of hepatocytes **(Choice C)**. No necrosis or inflammation is present in the liver. Electron microscopy findings include swelling, a decreased number of mitochondria and glycogen depletion.

2. **Encephalopathy** of Reye syndrome is attributed to hepatic dysfunction and the toxic effect of hyperammonemia on the CNS leading to cerebral edema.

To avoid the possibility of inducing Reye syndrome, aspirin should not be administered to children under the age of sixteen except for very specific circumstances where it is indicated for the treatment of a serious illness such as in Kawasaki disease where salicylates are a mainstay of treatment.

(Choices A and B) Apoptosis of hepatocytes, acinar necrosis and periportal mononuclear inflammatory infiltration are the characteristic light microscopy findings of viral hepatitis caused by any of the hepatitis viruses.

(Choice D) Centrilobular congestion occurs in the liver of the patients with right-sided heart failure.

(Choice E) Primary biliary cirrhosis displays bile duct destruction, periductal granulomatous inflammation and bile duct proliferation.

Educational Objective:
Reye syndrome occurs in children with febrile illness treated with salicylates **(aspirin)**. It consists of hepatic failure and encephalopathy. The characteristic histological finding is microvesicular steatosis of hepatocytes without inflammation and cerebral edema.

Pathology	Gastrointestinal & Nutrition	Reye syndrome
Subject	System	Topic

Copyright © UWorld. All rights reserved.

A 49-year-old man comes to the office for evaluation of a dry cough that occurs mainly at night. His symptoms have been present on and off for several years, but he has not been previously evaluated. The patient also reports a frequent sore throat and occasional epigastric discomfort. He has tried a variety of antihistamines and over-the-counter cough medications without relief. Past medical history is notable for obesity and diet-controlled type 2 diabetes mellitus. He does not smoke or drink alcohol. Cardiopulmonary and abdominal examinations are unremarkable. Chest x-ray reveals no abnormalities, and pulmonary function testing is normal. The patient undergoes upper gastrointestinal endoscopy with mucosal biopsies. Microscopic findings on lower esophageal biopsy are shown in the image below.

Settings

1
2
3
4
5
6
7
8
9
10
11
12
13
14
15
16
17
18
19
20
21
22
23
24
25
26
27
28
29
30

Item 4 of 38
Question Id: 282

Mark | Previous | Next | Full Screen | Tutorial | Lab Values | Notes | Calculator | Reverse Color | Text Zoom | Settings

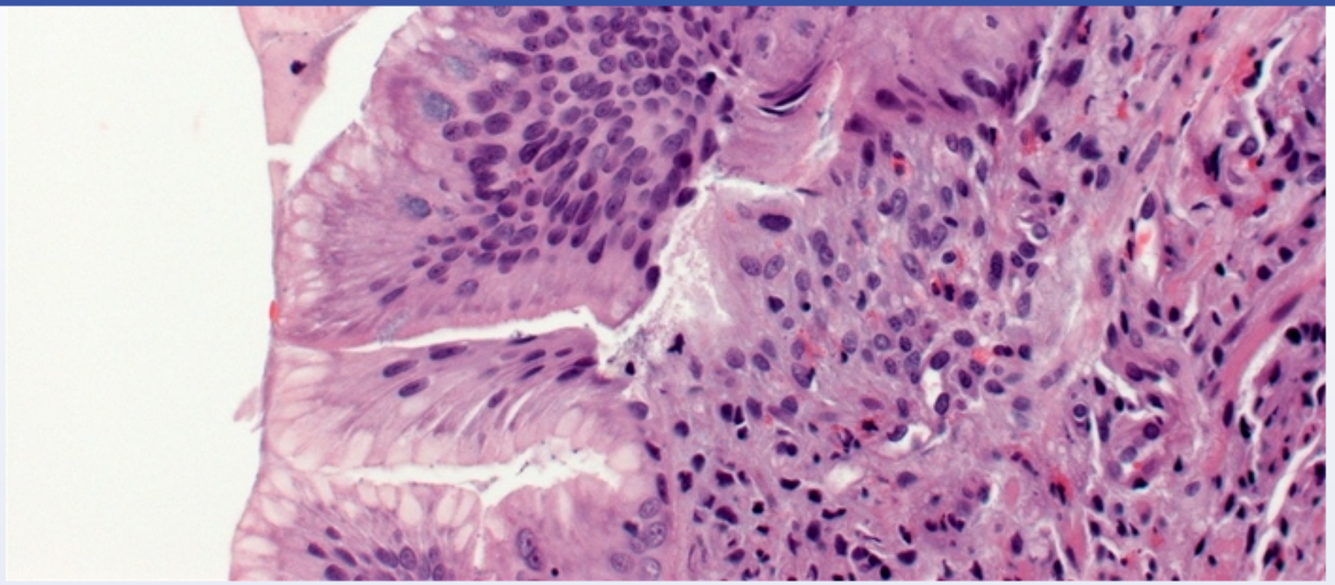

This patient is at highest risk of which of the following complications?

- A. Achalasia
- B. Adenocarcinoma
- C. Crohn disease
- D. Squamous cell carcinoma
- E. Variceal bleeding

Submit

Block Time Remaining: 00:00:12
TUTOR

5 | Feedback | Suspend | End Block

1 2 3 4 5 6 7 8 9 10 11 12 13 14 15 16 17 18 19 20 21 22 23 24 25 26 27 28 29 30

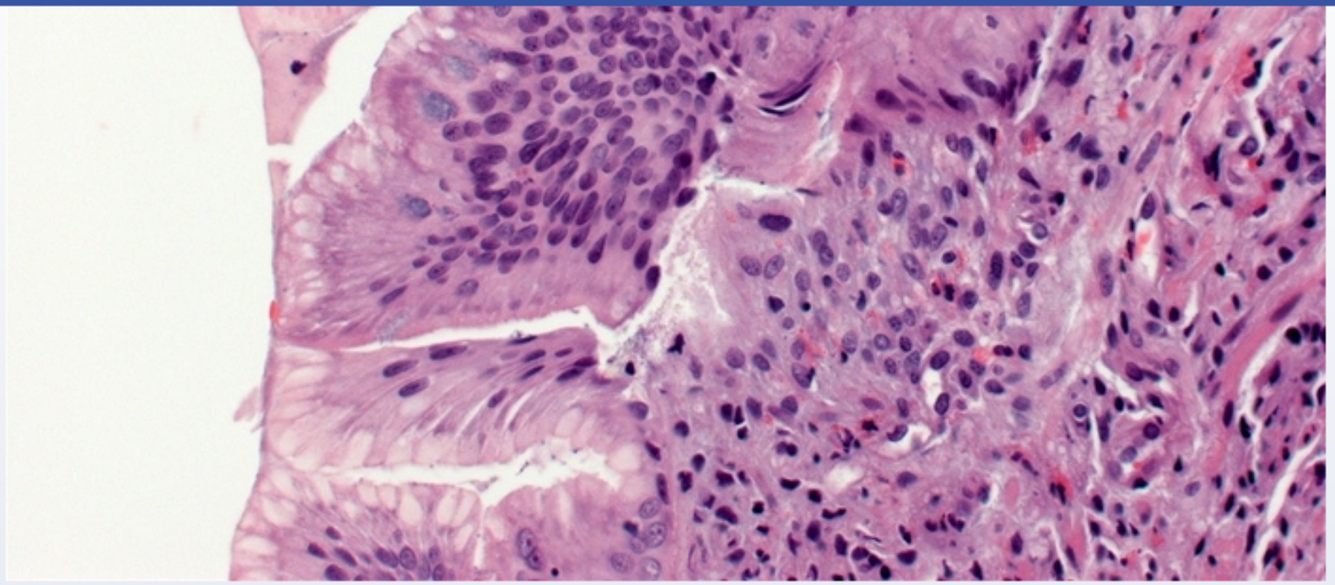

This patient is at highest risk of which of the following complications?

- A. Achalasia (1%)
- ✓ B. Adenocarcinoma (86%)
- C. Crohn disease (0%)
- D. Squamous cell carcinoma (9%)
- E. Variceal bleeding (0%)

Omitted
Correct answer

86%
Answered correctly

03 secs
Time Spent

01/17/2020
Last Updated

1
2
3
4
5
6
7
8
9
10
11
12
13
14
15
16
17
18
19
20
21
22
23
24
25
26
27
28
29
30

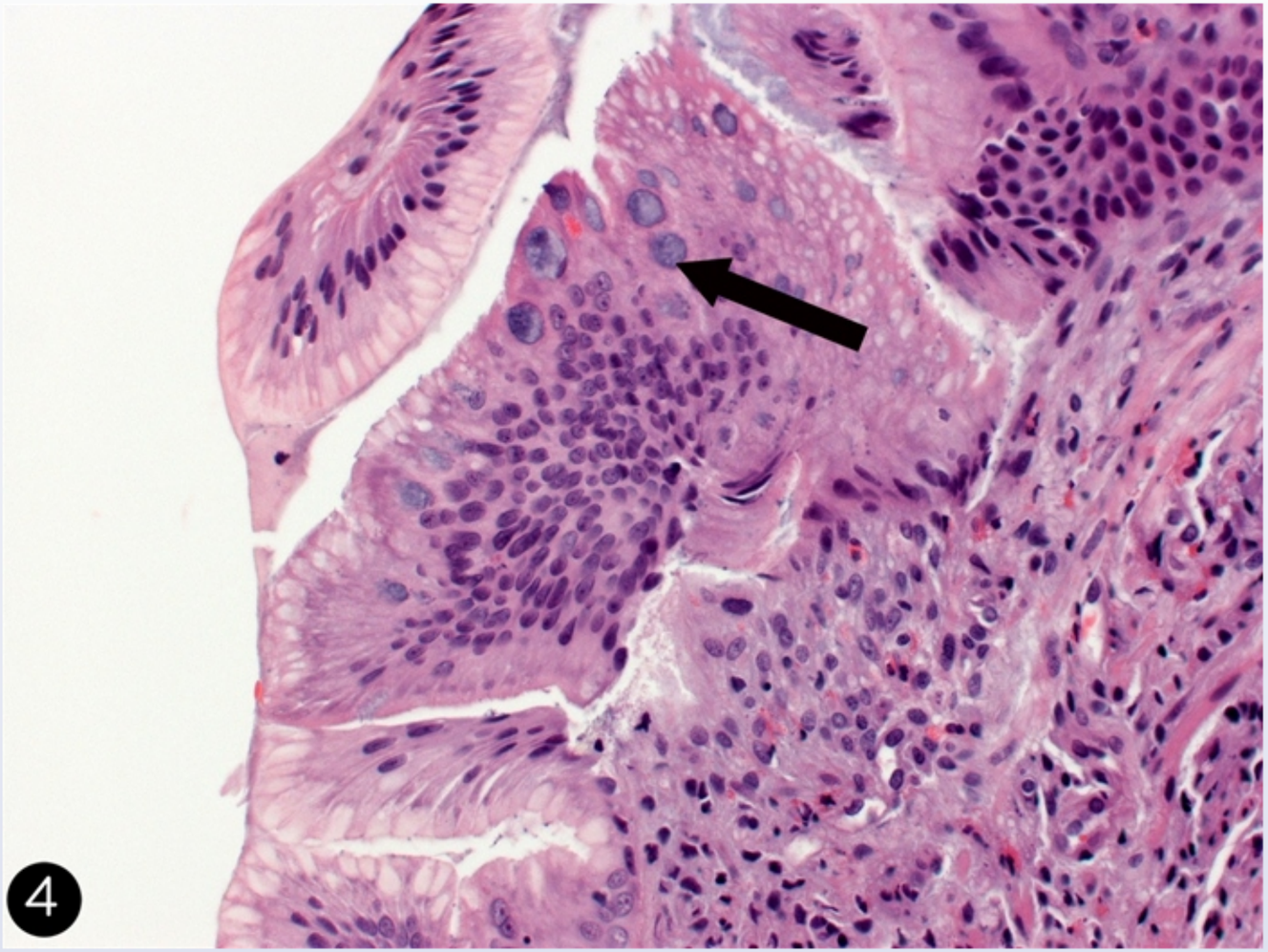

The esophageal biopsy in this patient shows intestinal-type columnar epithelium with goblet cells (arrow) where a normal esophagus would be lined by stratified squamous epithelium. This finding is diagnostic of **Barrett esophagus**, which is seen when acidic gastric contents enter the esophagus, causing inflammation and subsequent epithelial necrosis. Sustained epithelial damage promotes metaplastic replacement of the normal stratified squamous epithelium with **intestinal-type columnar cells**. The transition to columnar epithelium may be seen grossly on

The esophageal biopsy in this patient shows intestinal-type columnar epithelium with goblet cells (arrow) where a normal esophagus would be lined by stratified squamous epithelium. This finding is diagnostic of **Barrett esophagus**, which is seen when acidic gastric contents enter the esophagus, causing inflammation and subsequent epithelial necrosis. Sustained epithelial damage promotes metaplastic replacement of the normal stratified squamous epithelium with **intestinal-type columnar cells**. The transition to columnar epithelium may be seen grossly on endoscopy as tongues of beefy red mucosa extending above the lower esophageal sphincter into areas of normal pale pink squamous mucosa.

People with severe and long-standing **acid reflux** disease are most prone to Barrett esophagus. This metaplasia is hypothesized to be adaptive at first, as intestinal-type epithelium is more resistant to gastric acid. However, it is a major risk factor for **esophageal adenocarcinoma**, which typically develops from the metaplastic intestinal epithelium in the distal part of the esophagus.

(Choices A and D) The major risk factors for squamous cell carcinoma of the esophagus are cigarette smoking and alcohol use. Achalasia, an esophageal motility disorder caused by the loss of ganglion cells in the lower esophagus, also carries an increased risk of squamous carcinoma.

(Choices C and E) Crohn disease can affect the esophagus, typically causing patchy inflammation, erosions, ulcers, strictures, and fistulas. Esophageal varices develop in the context of high portal venous pressure, most often due to alcoholic or post-viral liver cirrhosis. These conditions are not associated with Barrett esophagus.

Educational objective:
Barrett esophagus is a metaplastic condition in which the normal squamous epithelium of the distal esophagus is replaced by intestinal-type columnar epithelium. It occurs most often in longstanding acid reflux and is associated with an increased risk of adenocarcinoma.

References

- Barrett's esophagus: recent insights into pathogenesis and cellular ontogeny.

Pathology	Gastrointestinal & Nutrition	Barretts esophagus
Subject	System	Topic

Copyright © UWorld. All rights reserved.

Settings

1
2
3
4
5
6
7
8
9
10
11
12
13
14
15
16
17
18
19
20
21
22
23
24
25
26
27
28
29
30

Item 4 of 38
Question Id: 282

Mark | Previous | Next | Full Screen | Tutorial | Lab Values | Notes | Calculator | Reverse Color | Text Zoom | Settings

Exhibit Display

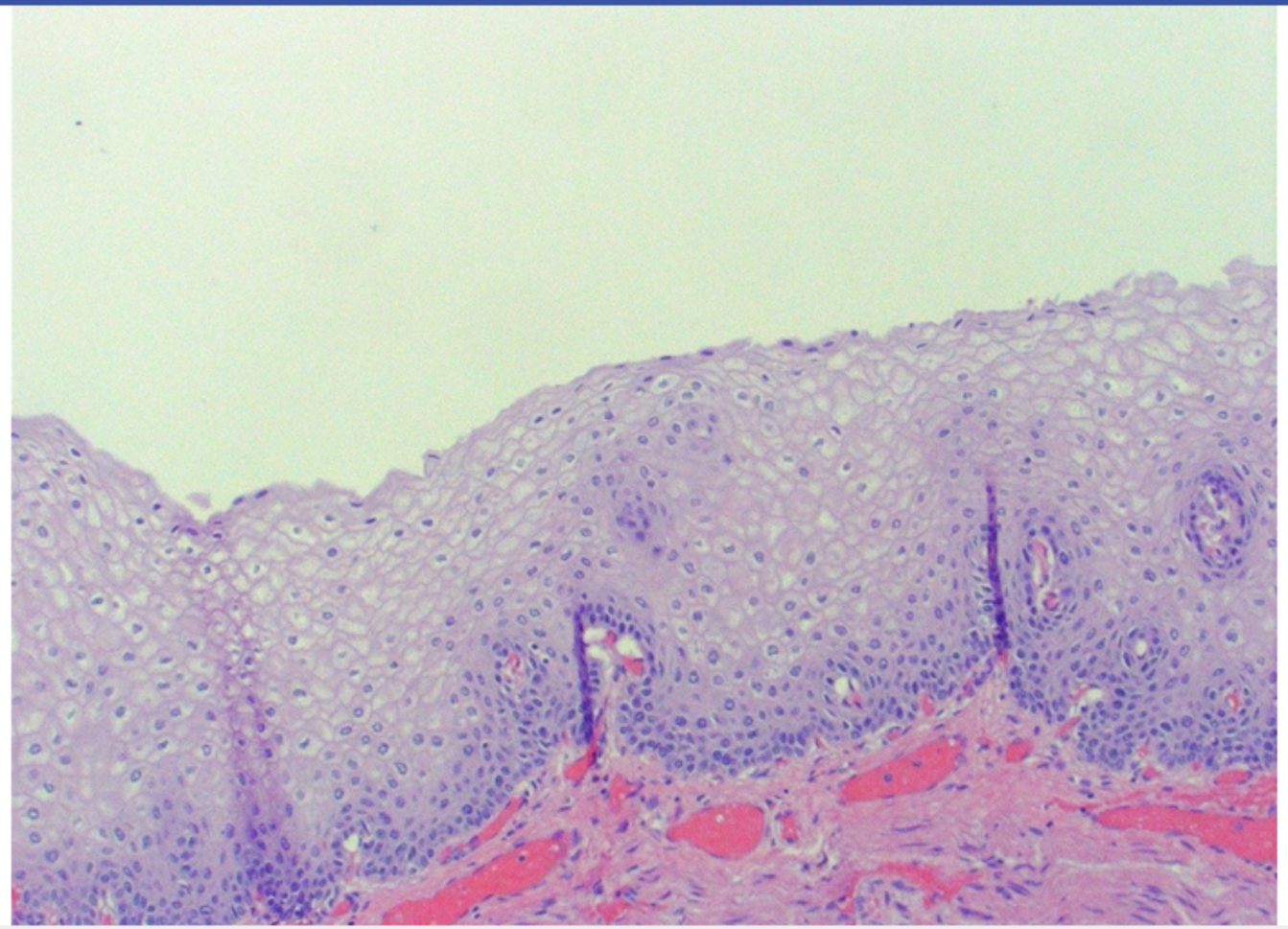

Zoom In | Zoom Out | Reset | Add To New Card | Existing Card

Block Time Remaining: 00:00:13
TUTOR

5 | Feedback | Suspend | End Block

Settings

1
2
3
4
5
6
7
8
9
10
11
12
13
14
15
16
17
18
19
20
21
22
23
24
25
26
27
28
29
30

Item 4 of 38
Question Id: 282

Mark | Previous | Next | Full Screen | Tutorial | Lab Values | Notes | Calculator | Reverse Color | Text Zoom | Settings

Exhibit Display

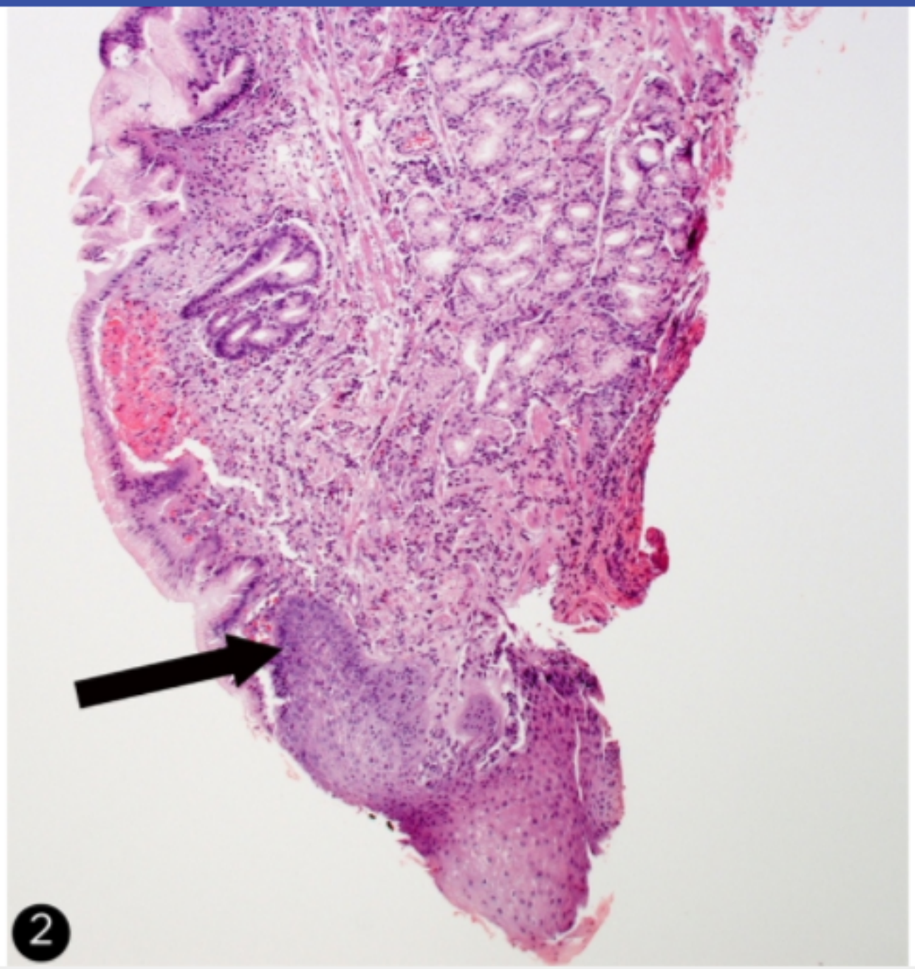

Zoom In | Zoom Out | Reset | Add To New Card | Existing Card

Block Time Remaining: 00:00:13
TUTOR

5 | Feedback | Suspend | End Block

Settings

1 2 3 4 5 6 7 8 9 10 11 12 13 14 15 16 17 18 19 20 21 22 23 24 25 26 27 28 29 30

Item 4 of 38
Question Id: 282

Mark | Previous | Next | Full Screen | Tutorial | Lab Values | Notes | Calculator | Reverse Color | Text Zoom | Settings

Exhibit Display

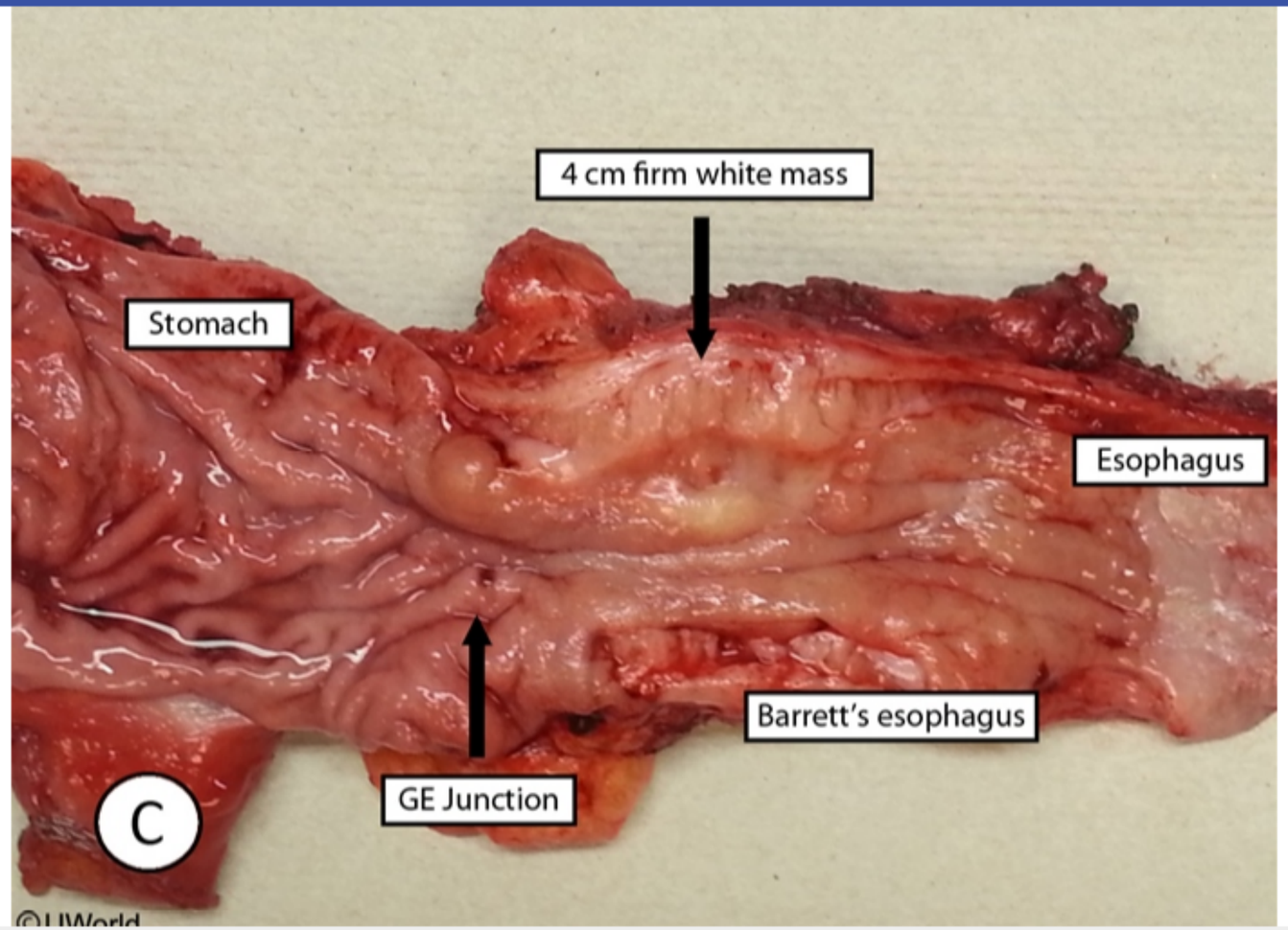

Zoom In | Zoom Out | Reset | Add To New Card | Existing Card

Block Time Remaining: 00:00:13
TUTOR

5 | Feedback | Suspend | End Block

A mass resected from the liver of a 32-year-old woman has the morphology demonstrated on the slide below.

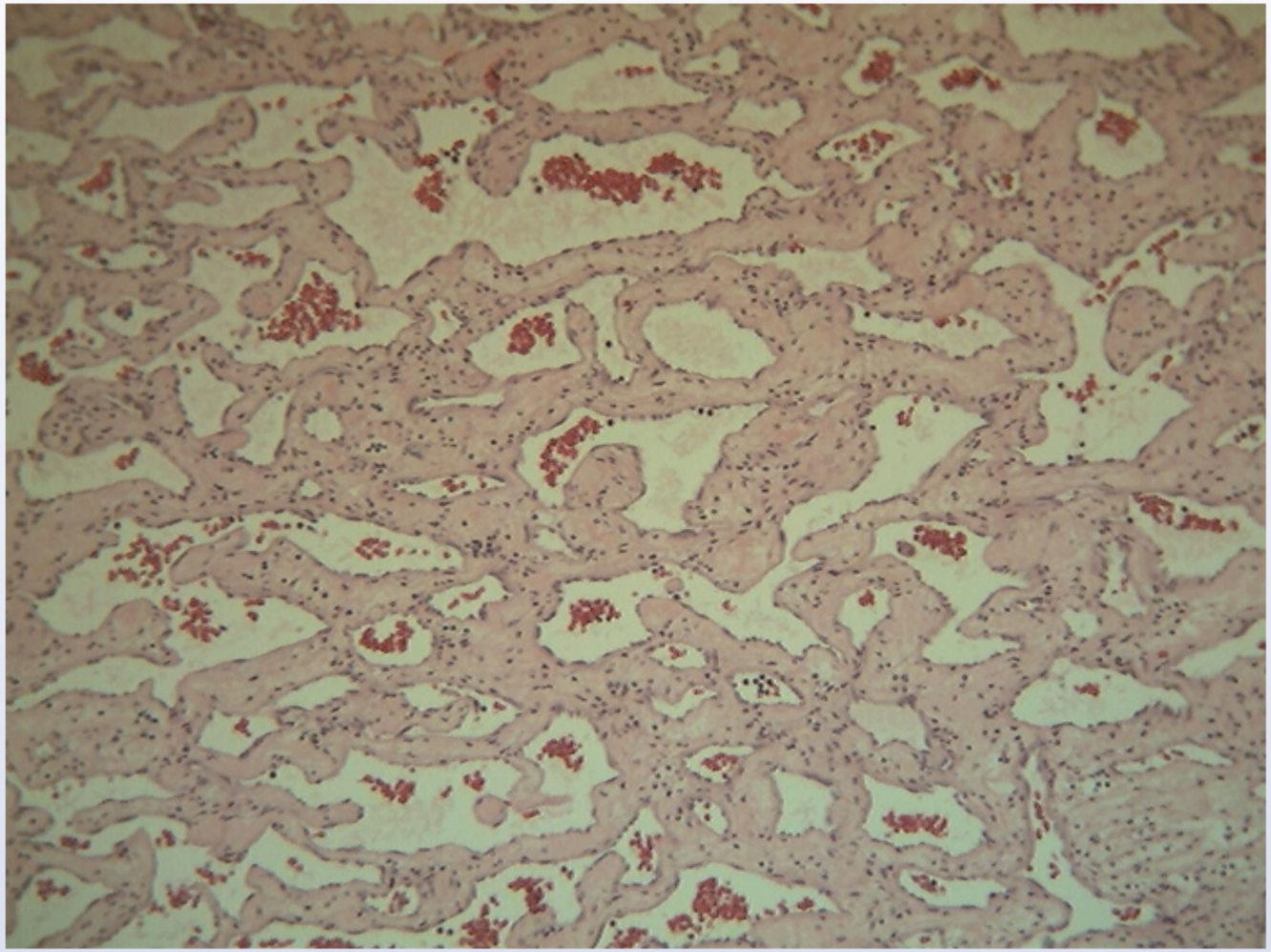

Which of the following is the most accurate statement concerning this patient's condition?

1 2 3 4 5 6 7 8 9 10 11 12 13 14 15 16 17 18 19 20 21 22 23 24 25 26 27 28 29 30

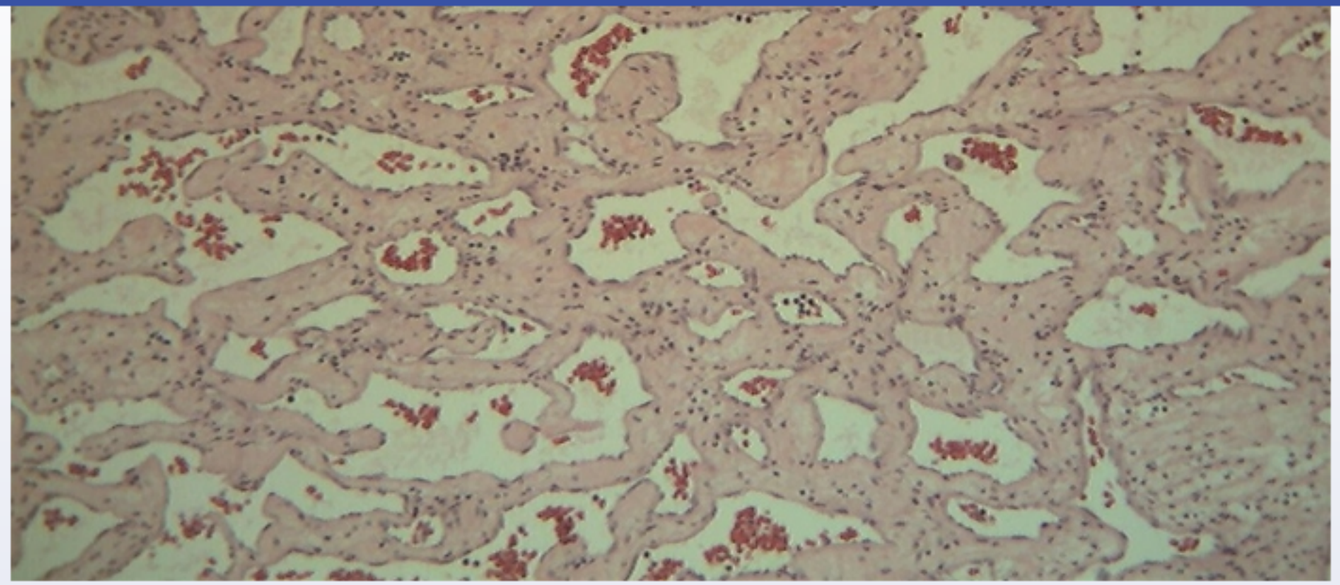

Which of the following is the most accurate statement concerning this patient's condition?

- A. Malignant transformation is a rule
- B. It is the most common benign liver tumor
- C. It can regress upon oral contraceptive discontinuation
- D. It is strongly associated with hemochromatosis
- E. Biopsy is indicated to confirm the diagnosis

Submit

1 2 3 4 5 6 7 8 9 10 11 12 13 14 15 16 17 18 19 20 21 22 23 24 25 26 27 28 29 30

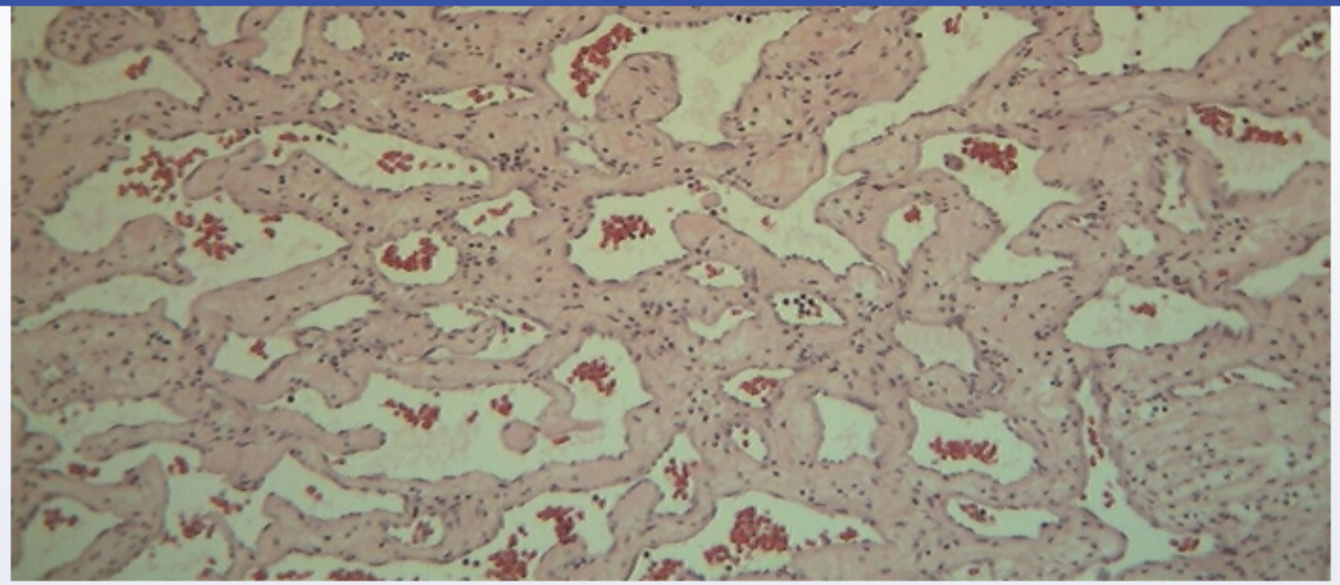

Which of the following is the most accurate statement concerning this patient's condition?

A. Malignant transformation is a rule (5%)

✓ B. It is the most common benign liver tumor (35%)

C. It can regress upon oral contraceptive discontinuation (32%)

D. It is strongly associated with hemochromatosis (16%)

E. Biopsy is indicated to confirm the diagnosis (10%)

Omitted
Correct answer

35%
Answered correctly

04 secs
Time Spent

04/02/2020
Last Updated

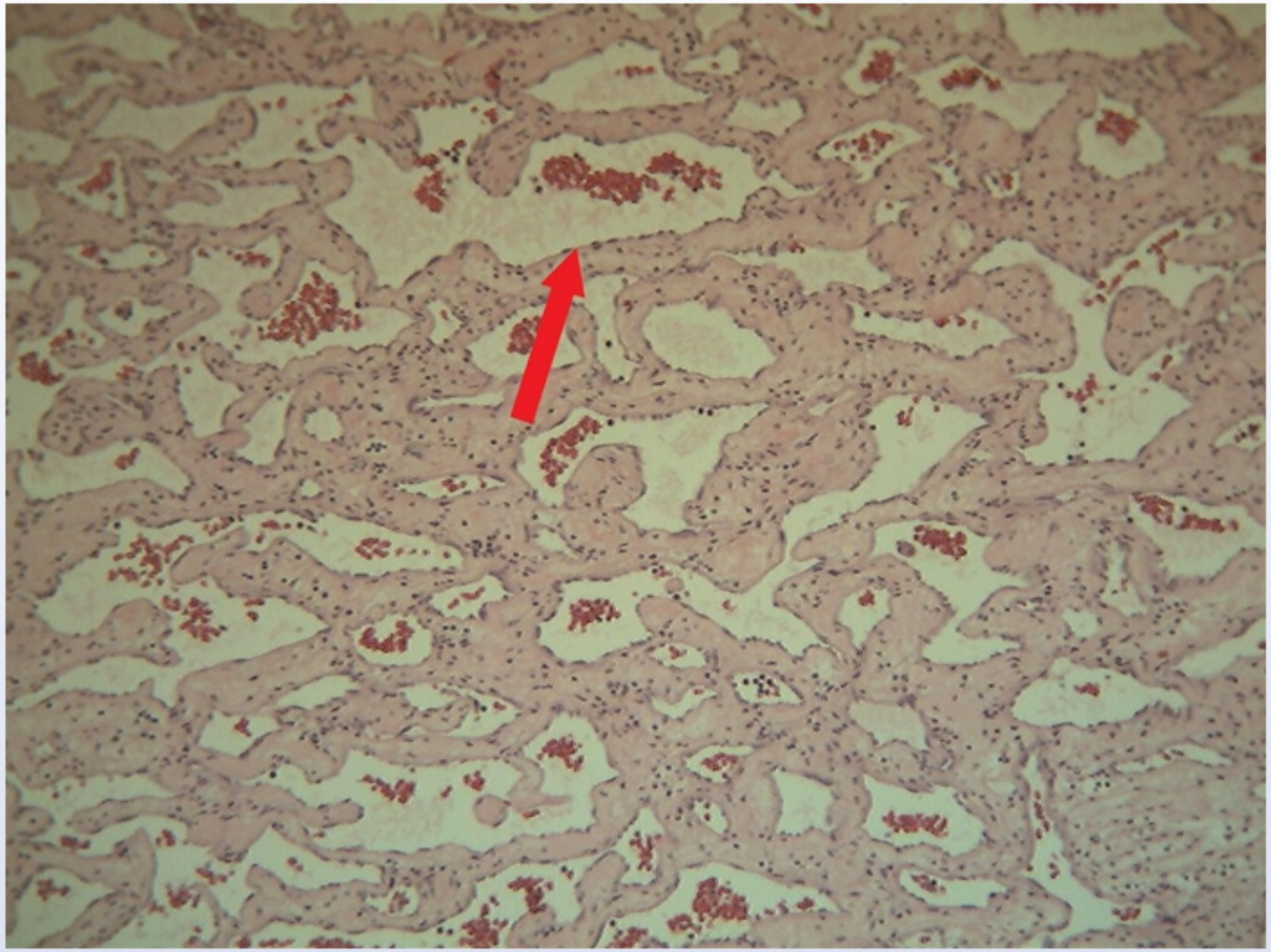

Cavernous hemangioma is the most common benign liver tumor, typically presenting in adults 30-50 years of age. These benign tumors are thought to be congenital malformations that enlarge by ectasia, not hyperplasia or hypertrophy. Hemangiomas may occur singly or in multiples and are well-circumscribed masses of spongy consistency, typically measuring less than 5 cm in width. Microscopically, these tumors consist of cavernous, blood-filled vascular spaces of variable size lined by a single epithelial layer (arrow). Collagenous scars or fibrous nodules may be

Cavernous hemangioma is the most common benign liver tumor, typically presenting in adults 30-50 years of age. These benign tumors are thought to be congenital malformations that enlarge by ectasia, not hyperplasia or hypertrophy. Hemangiomas may occur singly or in multiples and are well-circumscribed masses of spongy consistency, typically measuring less than 5 cm in width. Microscopically, these tumors consist of cavernous, blood-filled vascular spaces of variable size lined by a single epithelial layer (arrow). Collagenous scars or fibrous nodules may be seen in association with thrombosis. Most patients are asymptomatic, although some will complain of abdominal pain and right upper quadrant fullness. Prognosis is usually excellent, with surgical resection an option for those patients who are symptomatic or who have compression of adjacent structures.

(Choice A) On rare occasion, giant hemangiomas are found to be malignant vascular tumors. The vast majority of hemangiomas are benign lesions, however.

(Choice C) Hepatic adenomas can regress with the discontinuation of oral contraceptives, but hemangiomas are not similarly affected.

(Choice D) Hepatocellular carcinoma (not hemangioma) can be associated with hemochromatosis.

(Choice E) Biopsy of a suspected hemangioma is not advisable, as the procedure has been known to cause fatal hemorrhage and is of low diagnostic yield.

Educational objective:
Cavernous hemangioma is the most common benign liver tumor. Microscopically, these tumors consist of cavernous, blood-filled vascular spaces of variable size lined by a single epithelial layer. The biopsy of a suspected hemangioma is not advisable, as the procedure has been known to cause fatal hemorrhage and is of low diagnostic yield.

Pathology	Gastrointestinal & Nutrition	Hemangioma
Subject	System	Topic

Copyright © UWorld. All rights reserved.

Settings

1
2
3
4
5
6
7
8
9
10
11
12
13
14
15
16
17
18
19
20
21
22
23
24
25
26
27
28
29
30

Item 5 of 38
Question Id: 54

Mark | Previous | Next | Full Screen | Tutorial | Lab Values | Notes | Calculator | Reverse Color | Text Zoom | Settings

Exhibit Display

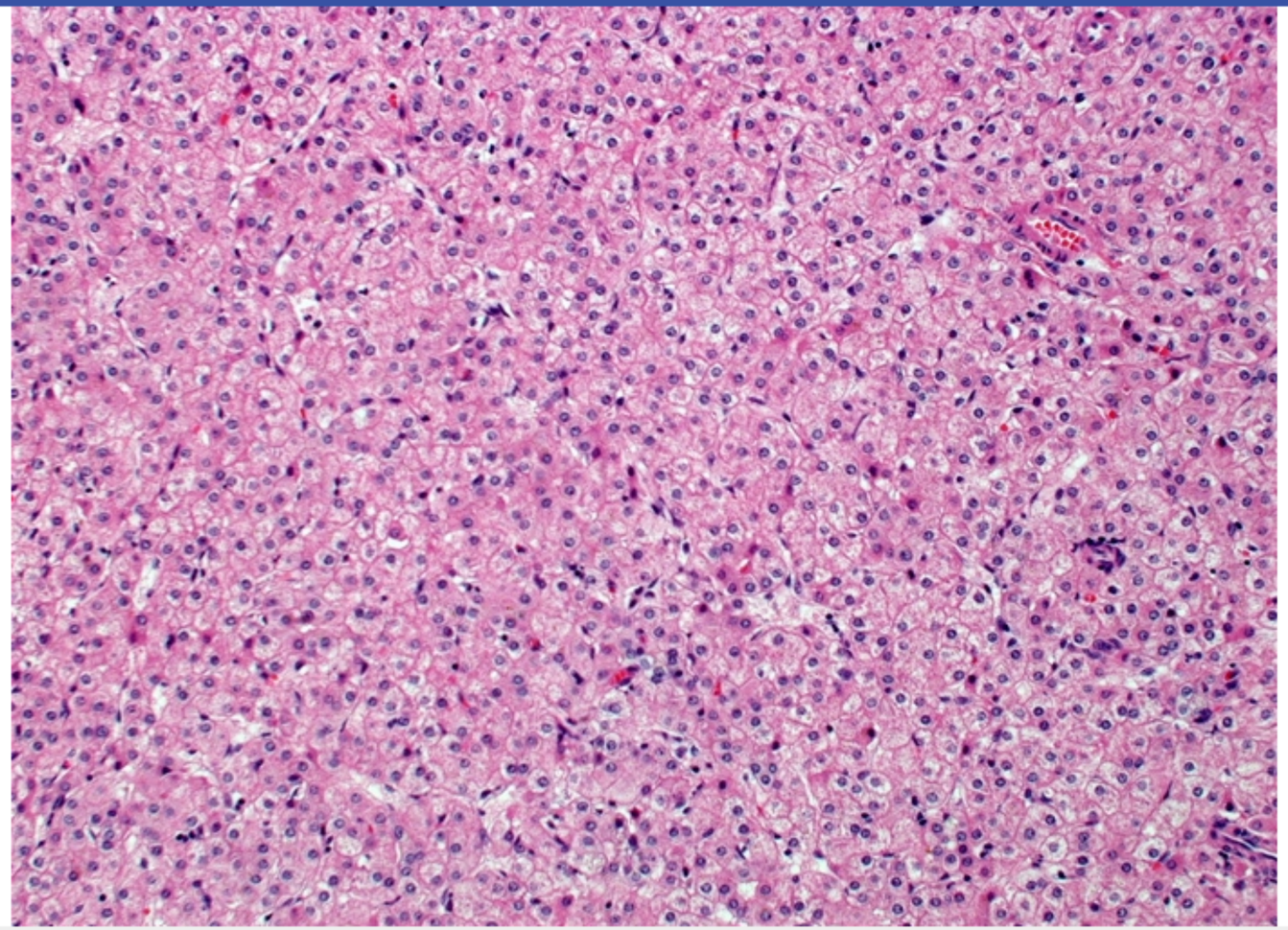

Zoom In | Zoom Out | Reset | Add To New Card | Existing Card

Block Time Remaining: 00:00:17
TUTOR

5 | Feedback | Suspend | End Block

Settings

1
2
3
4
5
6
7
8
9
10
11
12
13
14
15
16
17
18
19
20
21
22
23
24
25
26
27
28
29
30

Item 5 of 38
Question Id: 54

Mark | Previous | Next | Full Screen | Tutorial | Lab Values | Notes | Calculator | Reverse Color | Text Zoom | Settings

Exhibit Display

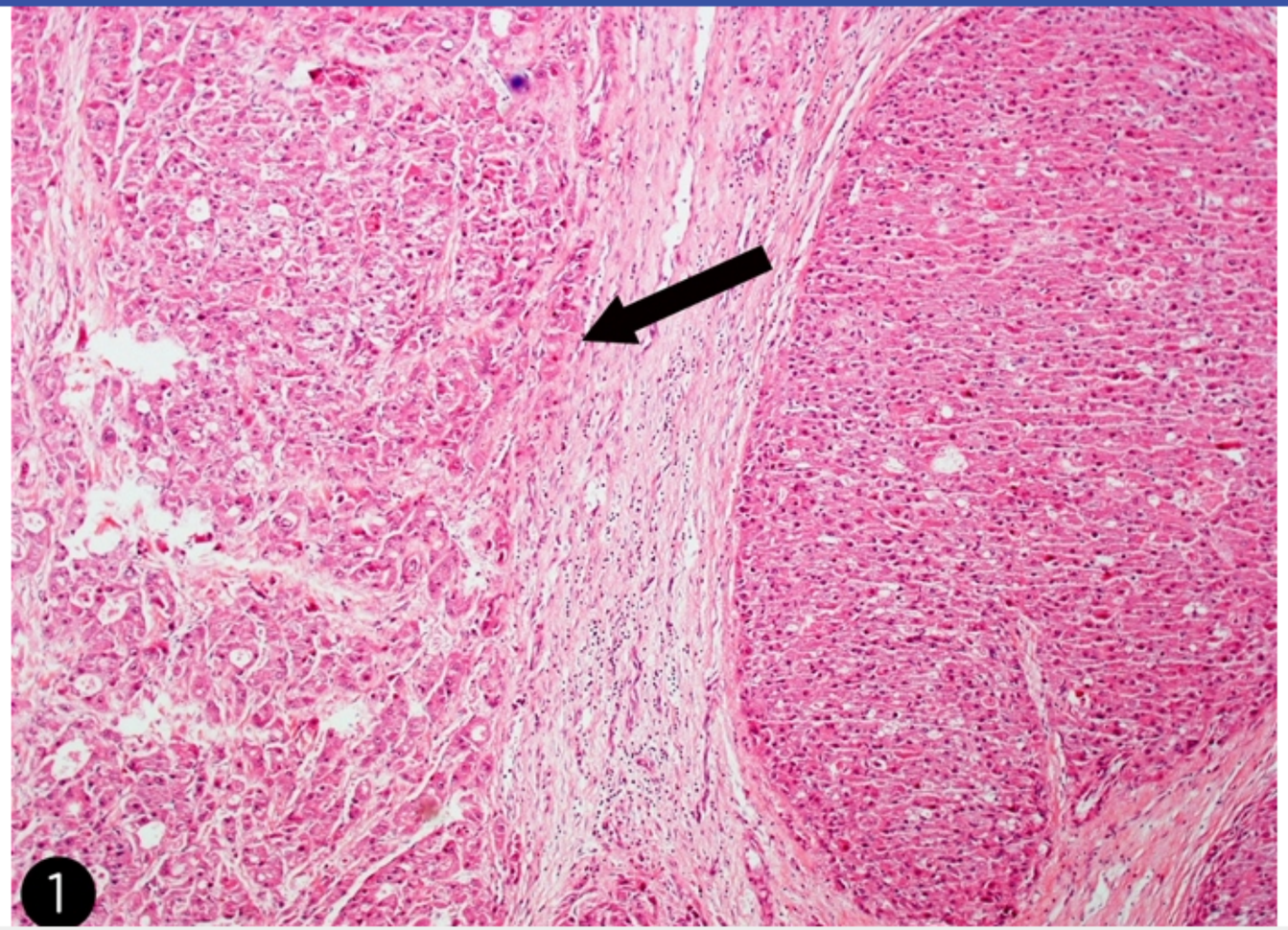

Zoom In | Zoom Out | Reset | Add To New Card | Existing Card

Block Time Remaining: 00:00:17
TUTOR

5 | Feedback | Suspend | End Block

A 23-year-old man is hospitalized with acute pancreatitis that resolves rapidly on fasting. He has suffered 2 similar episodes during the past 2 years. A gallbladder ultrasound obtained during a previous episode was normal. The patient has no other medical problems and takes no medications. He does not consume alcohol. Which of the following tests should be considered during the workup of this patient?

- A. Serum ceruloplasmin
- B. Serum cholesterol
- C. Serum ferritin
- D. Serum triglycerides
- E. Serum uric acid
- F. Urine oxalate

Submit

A 23-year-old man is hospitalized with acute pancreatitis that resolves rapidly on fasting. He has suffered 2 similar episodes during the past 2 years. A gallbladder ultrasound obtained during a previous episode was normal. The patient has no other medical problems and takes no medications. He does not consume alcohol. Which of the following tests should be considered during the workup of this patient?

- A. Serum ceruloplasmin (8%)
- B. Serum cholesterol (15%)
- C. Serum ferritin (5%)
- ✓ D. Serum triglycerides (64%)
- E. Serum uric acid (2%)
- F. Urine oxalate (4%)

Omitted
Correct answer
D

64%
Answered correctly

02 secs
Time Spent

02/20/2020
Last Updated

Explanation

Gallstones and alcoholism are the most common causes of acute pancreatitis. Gallstones typically affect middle-aged and older patients (particularly women) unless there is a predisposing condition (eg, young patients with sickle cell disease are at increased risk for bilirubin gallstones). This young male patient does not consume alcohol and is unlikely to have gallstones, especially considering the negative results of his prior ultrasound. Thus, one of the following less common causes of acute pancreatitis likely accounts for his condition:

1. Recent endoscopic retrograde cholangiopancreatography (ERCP) procedure

Gallstones and alcoholism are the most common causes of acute pancreatitis. Gallstones typically affect middle-aged and older patients (particularly women) unless there is a predisposing condition (eg, young patients with sickle cell disease are at increased risk for bilirubin gallstones). This young male patient does not consume alcohol and is unlikely to have gallstones, especially considering the negative results of his prior ultrasound. Thus, one of the following less common causes of acute pancreatitis likely accounts for his condition:

1. Recent endoscopic retrograde cholangiopancreatography (ERCP) procedure
2. Drugs (eg, azathioprine, sulfasalazine, furosemide, valproic acid)
3. Infections (eg, mumps, Coxsackie virus, *Mycoplasma pneumoniae*)
4. Hypertriglyceridemia
5. Structural abnormalities of the pancreatic duct (strictures, cancer, pancreas divisum) or of the ampullary region (choledochal cyst, stenosis of sphincter of Oddi)
6. Surgery (particularly of the stomach and biliary tract and after cardiac surgery)
7. Hypercalcemia

High levels of circulating triglycerides lead to increased production of free fatty acids within the pancreatic capillaries by pancreatic lipase. Normally, fatty acids exist in serum bound to albumin. However, if serum **triglyceride levels rise to >1000 mg/dL**, the concentration of free fatty acids exceeds the binding capacity of albumin and leads to direct injury to the pancreatic acinar cells. Thus, hypertriglyceridemia causes acute pancreatitis via direct tissue toxicity.

(Choice A) Decreased serum ceruloplasmin and increased hepatic copper content are diagnostic of Wilson disease. Cirrhosis, central nervous system involvement, and Kayser-Fleischer rings are characteristic findings. Wilson disease does not predispose to acute pancreatitis.

(Choice B) Increased serum cholesterol levels predispose to the development of systemic atherosclerosis, putting patients at increased risk for coronary artery disease, peripheral vascular disease, and stroke. In some cases, hypercholesterolemia may increase the risk of cholesterol gallstone formation, but this patient's negative gallbladder ultrasound makes this a less likely cause of his pancreatitis.

(Choice C) High concentrations of serum ferritin are found in hemochromatosis. Hemochromatosis can cause cirrhosis, pancreatic fibrosis and subsequent diabetes, cardiomyopathy, and secondary hypogonadism. It does not cause acute pancreatitis.

High levels of circulating triglycerides lead to increased production of free fatty acids within the pancreatic capillaries by pancreatic lipase. Normally, fatty acids exist in serum bound to albumin. However, if serum **triglyceride levels rise to >1000 mg/dL**, the concentration of free fatty acids exceeds the binding capacity of albumin and leads to direct injury to the pancreatic acinar cells. Thus, hypertriglyceridemia causes acute pancreatitis via direct tissue toxicity.

(Choice A) Decreased serum ceruloplasmin and increased hepatic copper content are diagnostic of Wilson disease. Cirrhosis, central nervous system involvement, and Kayser-Fleischer rings are characteristic findings. Wilson disease does not predispose to acute pancreatitis.

(Choice B) Increased serum cholesterol levels predispose to the development of systemic atherosclerosis, putting patients at increased risk for coronary artery disease, peripheral vascular disease, and stroke. In some cases, hypercholesterolemia may increase the risk of cholesterol gallstone formation, but this patient's negative gallbladder ultrasound makes this a less likely cause of his pancreatitis.

(Choice C) High concentrations of serum ferritin are found in hemochromatosis. Hemochromatosis can cause cirrhosis, pancreatic fibrosis and subsequent diabetes, cardiomyopathy, and secondary hypogonadism. It does not cause acute pancreatitis.

(Choice E) Hyperuricemia can lead to the formation of uric acid renal calculi and urate nephropathy. There is no association with acute pancreatitis.

(Choice F) Increased concentrations of oxalate in the urine are associated with intestinal malabsorption syndromes (eg, Crohn's disease). Calcium oxalate renal stones may form as a result. Hyperoxaluria is not associated with acute pancreatitis.

Educational objective:
Eighty percent of acute pancreatitis cases are caused by gallstones and chronic alcoholism. Less common causes account for the other 20%. Inherited or acquired hypertriglyceridemia can cause acute pancreatitis if the serum level of triglycerides exceeds 1000 mg/dL.

Pathology	Gastrointestinal & Nutrition	Acute pancreatitis
Subject	System	Topic

Copyright © UWorld. All rights reserved.

A 54-year-old man is evaluated in the clinic due to generalized weakness and lethargy for the past 5 years. He has no history of hypothyroidism or depression. The patient uses acetaminophen intermittently for joint pains that he attributes to "old age." He drinks alcohol occasionally but does not use tobacco or illicit drugs. His older brother died of liver cirrhosis. Laboratory tests show a serum ferritin level of 1800 µg/L. If this patient's disorder is hereditary, the genetic defect responsible for his condition most likely affects which of the following processes?

A. Blood iron transport

B. Hemoglobin synthesis

C. Hepatic iron excretion

D. Intestinal iron absorption

E. Renal iron excretion

Submit

A 54-year-old man is evaluated in the clinic due to generalized weakness and lethargy for the past 5 years. He has no history of hypothyroidism or depression. The patient uses acetaminophen intermittently for joint pains that he attributes to "old age." He drinks alcohol occasionally but does not use tobacco or illicit drugs. His older brother died of liver cirrhosis. Laboratory tests show a serum ferritin level of 1800 µg/L. If this patient's disorder is hereditary, the genetic defect responsible for his condition most likely affects which of the following processes?

- A. Blood iron transport (9%)
- B. Hemoglobin synthesis (3%)
- C. Hepatic iron excretion (24%)
- ✓ D. Intestinal iron absorption (60%)
- E. Renal iron excretion (1%)

Omitted
Correct answer
D

60%
Answered correctly

01 sec
Time Spent

03/11/2020
Last Updated

Explanation

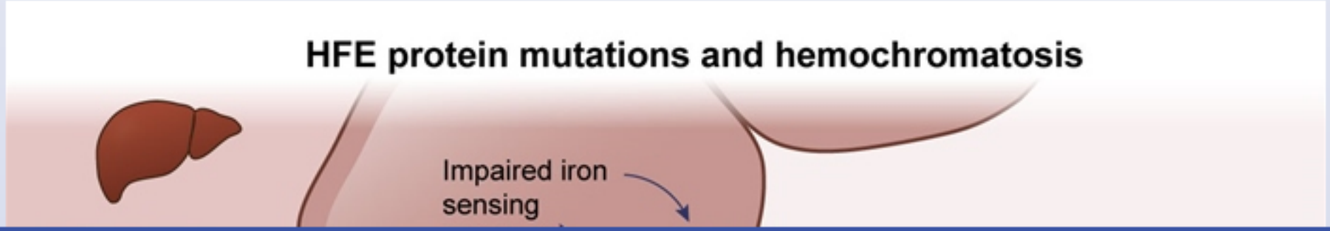

Settings

1
2
3
4
5
6
7
8
9
10
11
12
13
14
15
16
17
18
19
20
21
22
23
24
25
26
27
28
29
30

Item 7 of 38
Question Id: 393

Mark

Previous | Next | Full Screen | Tutorial | Lab Values | Notes | Calculator | Reverse Color | Text Zoom | Settings

HFE protein mutations and hemochromatosis

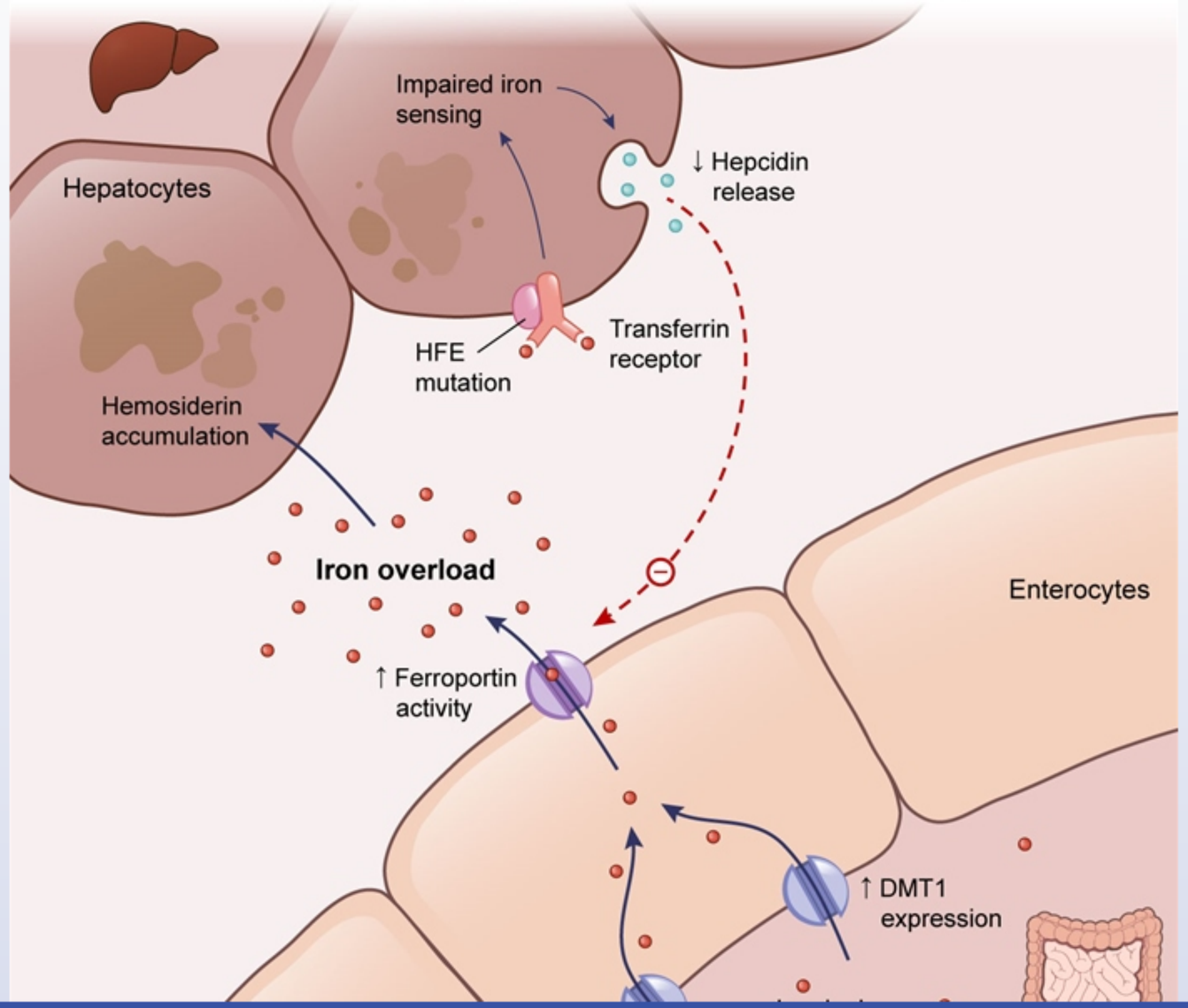

Block Time Remaining: 00:00:20
TUTOR

3 | Feedback | Suspend | End Block

This patient likely has **hereditary hemochromatosis**, an autosomal recessive disorder characterized by excessive intestinal iron absorption and accumulation within parenchymal tissues that result in end-organ damage (eg, cirrhosis, diabetes mellitus, cardiomyopathy, arthropathy). The condition is frequently caused by a missense mutation in the ***HFE* gene** (eg, C282Y), which is most commonly found in Caucasians.

The HFE protein interacts with the transferrin receptor on the cell surface to facilitate endocytosis of the iron-transferrin complex. Once inside the cell, transferrin is degraded and the released iron is added to the labile iron pool. Mutation of the HFE protein leads to reduced iron uptake and causes enterocytes and hepatocytes to sense falsely low iron levels. This enhances iron accumulation in the body via 2 mechanisms:

1. Enterocytes increase apical expression of divalent metal transporter 1 (DMT1), **increasing intestinal iron absorption** from the lumen.
2. Hepatocytes **decrease hepcidin** synthesis, which increases ferroportin expression on the basolateral surface of enterocytes and promotes iron secretion into the circulation.

Excessive iron accumulation results in elevated levels of serum ferritin (cellular iron storage protein) and increased saturation of transferrin (major iron transporter in the plasma).

(Choice A) Iron transport in the blood is not impaired in hereditary hemochromatosis as transferrin function is normal.

(Choice B) Patients with severe forms of thalassemia (eg, beta thalassemia major) often have chronic hemolytic anemia and develop iron overload due to repeated blood transfusions (secondary hemochromatosis). However, hemoglobin production is normal in patients with hereditary hemochromatosis as iron transport to the bone marrow is unaffected.

(Choices C and E) Total body iron levels are regulated by varying the rate of intestinal iron absorption. Although iron loss occurs through sloughing of the intestinal lining and during menstruation in women, there are no regulated mechanisms to excrete iron from the body.

Educational objective:
Hereditary hemochromatosis is most commonly caused by a missense mutation in the *HFE* gene, resulting in excessive intestinal iron absorption and organ damage (eg, cirrhosis, diabetes mellitus, cardiomyopathy, arthropathy) due to iron accumulation within parenchymal tissues.

References

- Hereditary hemochromatosis: pathogenesis, diagnosis, and treatment.
- HFE-associated hereditary hemochromatosis.

causes enterocytes and hepatocytes to sense falsely low iron levels. This enhances iron accumulation in the body via 2 mechanisms:

1. Enterocytes increase apical expression of divalent metal transporter 1 (DMT1), **increasing intestinal iron absorption** from the lumen.
2. Hepatocytes **decrease hepcidin** synthesis, which increases ferroportin expression on the basolateral surface of enterocytes and promotes iron secretion into the circulation.

Excessive iron accumulation results in elevated levels of serum ferritin (cellular iron storage protein) and increased saturation of transferrin (major iron transporter in the plasma).

(Choice A) Iron transport in the blood is not impaired in hereditary hemochromatosis as transferrin function is normal.

(Choice B) Patients with severe forms of thalassemia (eg, beta thalassemia major) often have chronic hemolytic anemia and develop iron overload due to repeated blood transfusions (secondary hemochromatosis). However, hemoglobin production is normal in patients with hereditary hemochromatosis as iron transport to the bone marrow is unaffected.

(Choices C and E) Total body iron levels are regulated by varying the rate of intestinal iron absorption. Although iron loss occurs through sloughing of the intestinal lining and during menstruation in women, there are no regulated mechanisms to excrete iron from the body.

Educational objective:
Hereditary hemochromatosis is most commonly caused by a missense mutation in the *HFE* gene, resulting in excessive intestinal iron absorption and organ damage (eg, cirrhosis, diabetes mellitus, cardiomyopathy, arthropathy) due to iron accumulation within parenchymal tissues.

References

- Hereditary hemochromatosis: pathogenesis, diagnosis, and treatment.
- HFE-associated hereditary hemochromatosis.

Pathology	Gastrointestinal & Nutrition	Hemochromatosis
Subject	System	Topic

Copyright © UWorld. All rights reserved.

A 55-year-old man comes to the office due to recurrent abdominal discomfort. He also has bloating, a feeling of fullness, and indigestion. Vital signs are within normal limits, and abdominal examination is unremarkable. Fecal occult blood testing is positive. Gastrointestinal endoscopic procedures are performed and confirm the presence of an ulcer. The patient is told that the ulcer itself is very unlikely to be malignant based on its location. Which of the following is the most likely site of this patient's gastrointestinal ulcer?

- A. Duodenum
- B. Esophagus
- C. Rectum
- D. Sigmoid colon
- E. Stomach

Submit

1 2 3 4 5 6 7 8 9 10 11 12 13 14 15 16 17 18 19 20 21 22 23 24 25 26 27 28 29 30

A 55-year-old man comes to the office due to recurrent abdominal discomfort. He also has bloating, a feeling of fullness, and indigestion. Vital signs are within normal limits, and abdominal examination is unremarkable. Fecal occult blood testing is positive. Gastrointestinal endoscopic procedures are performed and confirm the presence of an ulcer. The patient is told that the ulcer itself is very unlikely to be malignant based on its location. Which of the following is the most likely site of this patient's gastrointestinal ulcer?

- ✓ A. Duodenum (80%)
- B. Esophagus (1%)
- C. Rectum (1%)
- D. Sigmoid colon (2%)
- E. Stomach (13%)

Omitted
Correct answer
A

80%
Answered correctly

01 sec
Time Spent

02/24/2020
Last Updated

Explanation

Peptic ulcers

Settings

1 2 3 4 5 6 7 8 9 10 11 12 13 14 15 16 17 18 19 20 21 22 23 24 25 26 27 28 29 30

Item 8 of 38
Question Id: 130

Mark | Previous | Next | Full Screen | Tutorial | Lab Values | Notes | Calculator | Reverse Color | Text Zoom | Settings

Peptic ulcers

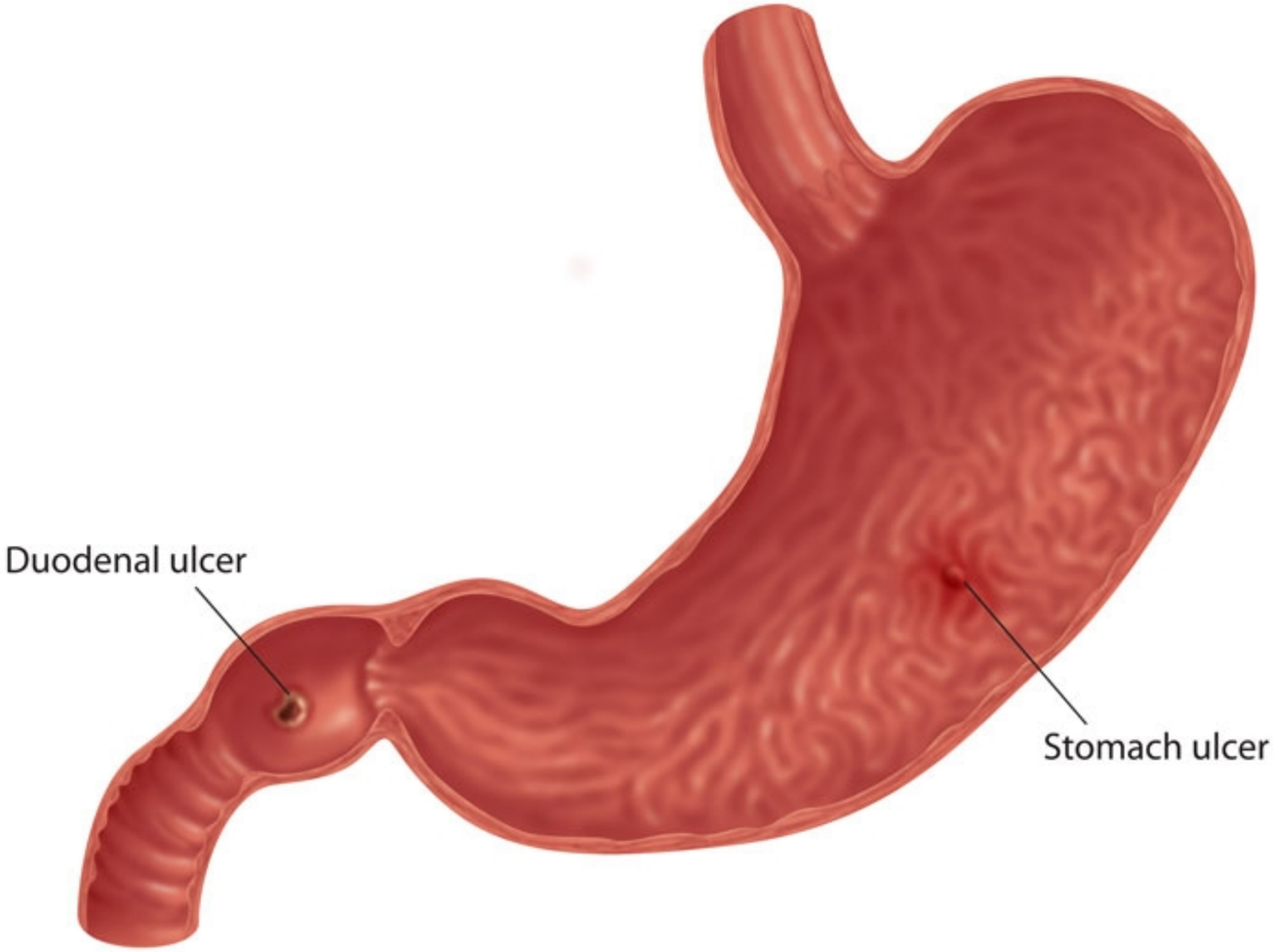

USMLEWorld, LLC © 2011

Block Time Remaining: 00:00:21
TUTOR

3 | Feedback | Suspend | End Block

Gastrointestinal ulcers are defined as breaches of the alimentary tract mucosa that extend through the muscularis mucosae into the submucosa (or beyond). Those specifically designated as **peptic ulcers** are chronic lesions in areas exposed to acid/peptic juices, most commonly in the proximal duodenum, antral stomach, and gastroesophageal junction. Patients may present with epigastric discomfort, early satiety, and a positive fecal occult blood test.

Almost all peptic ulcers are due to either ***Helicobacter pylori*** infection or use of **nonsteroidal anti-inflammatory drugs (NSAIDs)**. The vast majority (>95%) of duodenal ulcers occur within the first part of the duodenum; however, multiple or refractory ulcers beyond the duodenal bulb may be seen in patients with gastrinoma (non-beta islet cell tumor of the pancreas). **Duodenal ulcers** are very **rarely malignant** and do not require biopsy. Conversely, gastric ulcers (located within the stomach) can be malignant (eg, gastric adenocarcinoma) and must be biopsied for confirmation **(Choice E)**. Gastric ulcers caused by *H pylori* infection are associated with an increased risk of gastric cancer, but duodenal ulcers related to this infection do not lead to a higher risk of duodenal carcinoma.

(Choice B) Esophageal adenocarcinoma can appear as an ulcerated/exophytic lesion in the lower third of the esophagus and typically results from Barrett esophagus, chronic gastroesophageal reflux disease, obesity, and/or smoking. Esophageal squamous cell carcinoma appears as plaque-like thickening of the mucosa in the upper two-thirds of the esophagus that may become ulcerated. Major risk factors include smoking, alcohol consumption, and caustic injury.

(Choices C and D) Carcinomas of the distal colon tend to be annular lesions that result in "napkin-ring" constriction of the bowel, with heaped-up edges and an ulcerated central region. Risk factors include advanced age, hereditary (eg, familial adenomatous polyposis) or sporadic colon cancer in the family, and inflammatory bowel disease.

Educational objective:
Duodenal ulcers are not associated with an increased risk of carcinoma in the same location. In contrast, ulcers located in the esophagus, stomach (gastric), and colon may be malignant, and biopsy is required.

References

- A past history of gastric ulcers and Helicobacter pylori infection increase the risk of gastric malignant lymphoma.
- The risk of gastric cancer in patients with duodenal and gastric ulcer: research progresses and clinical implications.

A 36-year-old woman comes to the office due to vague epigastric abdominal pain, occasional nausea, and bloating. She has no associated weight loss. Medical history is notable for moderate obesity and chronic allergic rhinitis. The patient takes no medications and does not use tobacco, alcohol, or illicit drugs. She was a vegetarian for several years but now consumes a wide variety of foods, including meat products. The patient has traveled abroad extensively in the past. Vital signs are normal. Examination shows mild epigastric tenderness to deep palpation. Laboratory results reveal mild anemia. Upper gastrointestinal endoscopy shows diffuse erythema of the antral mucosa. Biopsy reveals an inflammatory cell infiltrate involving the superficial mucosal layers. The underlying cause of this patient's current condition can also lead to which of the following?

A. Gastric lymphoma

B. Gastroparesis

C. Gluten intolerance

D. Ileal obstruction

E. Pernicious anemia

Submit

1 2 3 4 5 6 7 8 9 10 11 12 13 14 15 16 17 18 19 20 21 22 23 24 25 26 27 28 29 30

A 36-year-old woman comes to the office due to vague epigastric abdominal pain, occasional nausea, and bloating. She has no associated weight loss. Medical history is notable for moderate obesity and chronic allergic rhinitis. The patient takes no medications and does not use tobacco, alcohol, or illicit drugs. She was a vegetarian for several years but now consumes a wide variety of foods, including meat products. The patient has traveled abroad extensively in the past. Vital signs are normal. Examination shows mild epigastric tenderness to deep palpation. Laboratory results reveal mild anemia. Upper gastrointestinal endoscopy shows diffuse erythema of the antral mucosa. Biopsy reveals an inflammatory cell infiltrate involving the superficial mucosal layers. The underlying cause of this patient's current condition can also lead to which of the following?

- ✓ A. Gastric lymphoma (55%)
- B. Gastroparesis (2%)
- C. Gluten intolerance (6%)
- D. Ileal obstruction (1%)
- E. Pernicious anemia (33%)

Omitted
Correct answer
A

55%
Answered correctly

01 sec
Time Spent

03/22/2020
Last Updated

Explanation

Atrophic gastritis		
	Helicobacter pylori–induced chronic gastritis	Autoimmune gastritis

Atrophic gastritis

	Helicobacter pylori–induced chronic gastritis	Autoimmune gastritis
Distribution	Multifocal; patchy	Corpus; diffuse (spares antrum)
Inflammatory cells	Neutrophils, plasma cells, lymphocytes	Lymphocytes, macrophages
Gastrin level	Normal or ↓	↑
Acid production	Normal or ↓	↓
Sequelae	Gastric ulcer*	Vitamin B_{12} deficiency/pernicious anemia
Associated malignancy	Adenocarcinoma, MALT lymphoma	Adenocarcinoma, carcinoid
Risk factors	Poverty, living in developing country	Other autoimmune diseases

MALT = mucosa-associated lymphoid tissue.

*Chronic *H pylori* infection is more associated with gastric ulcers; acute infection is more associated with duodenal ulcers

This patient with **antral-predominant** gastritis likely has an **acute** *Helicobacter pylori* infection, which typically presents as nonatrophic gastritis. Destruction of somatostatin-producing cells in the antrum leads to **unchecked gastrin secretion** and results in excess production of stomach acid and an increased risk of **duodenal ulcers**.

If left untreated, **chronic** *H pylori* infection typically **spreads** to involve the corpus (body) and fundus of the stomach and is characterized by patchy, **multifocal gastric atrophy** with intestinal metaplasia. Patchy destruction of parietal and G cells results in **diminished acid secretion** and hypochlorhydria. Patients with chronic gastritis are less likely to develop duodenal ulcers but due to the associated **chronic inflammation**, they are at increased risk of **gastric ulcers** and malignancy, particularly **gastric lymphoma** (ie, mucosa-associated lymphoid tissue [MALT] lymphoma) and gastric adenocarcinoma.

(Choice B) *H pylori*–associated ulcers can cause gastric outlet obstruction, not gastroparesis, which is commonly due to uncontrolled diabetes or

and an increased risk of **duodenal ulcers**.

If left untreated, **chronic** *H pylori* infection typically **spreads** to involve the corpus (body) and fundus of the stomach and is characterized by patchy, **multifocal gastric atrophy** with intestinal metaplasia. Patchy destruction of parietal and G cells results in **diminished acid secretion** and hypochlorhydria. Patients with chronic gastritis are less likely to develop duodenal ulcers but due to the associated **chronic inflammation**, they are at increased risk of **gastric ulcers** and malignancy, particularly **gastric lymphoma** (ie, mucosa-associated lymphoid tissue [MALT] lymphoma) and gastric adenocarcinoma.

(Choice B) *H pylori*–associated ulcers can cause gastric outlet obstruction, not gastroparesis, which is commonly due to uncontrolled diabetes or infiltrative diseases (eg, scleroderma).

(Choice C) Celiac disease is an immune-mediated response to a protein in gluten and can cause microcytic anemia due to iron malabsorption. Autoimmune diseases are associated with autoimmune gastritis, not *H pylori* infection.

(Choice D) Ileal obstruction can occur due to Crohn disease, which can also cause abdominal pain and blood-loss anemia. However, *H pylori* infects gastric mucosa; the ileum is typically unaffected.

(Choice E) Unlike chronic *H pylori*-associated atrophic gastritis, which causes patchy atrophy with sparing of some parietal cells (allowing for continued intrinsic factor production and B_{12} absorption), autoimmune gastritis is characterized by diffuse and more complete immune-mediated destruction of parietal cells and intrinsic factor. This results in impaired vitamin B_{12} absorption and pernicious anemia.

Educational objective:
Acute *Helicobacter pylori* infection initially causes nonatrophic antral gastritis and an increased risk for duodenal ulcers. Chronic infection results in patchy, multifocal, atrophic gastritis with loss of parietal cells and G cells in the gastric body; this is associated with decreased acid secretion and an increased risk of gastric ulcers, gastric adenocarcinoma, and MALT lymphoma.

References

- Gastric adenocarcinoma: the role of Helicobacter pylori in pathogenesis and prevention efforts.

Pathology	Gastrointestinal & Nutrition	Peptic ulcer disease
Subject	System	Topic

A 75-year-old hospitalized man is evaluated for abdominal pain and fever. The patient was admitted 2 weeks ago due to necrotizing fasciitis of the gluteal region and severe sepsis. He has been treated with surgical debridements, intravenous antibiotics, and fluids. For the past 2 days, the patient has had right upper quadrant abdominal pain, nausea, and recurrent fever. He has a history of hypertension, type 2 diabetes mellitus, and chronic obstructive pulmonary disease. His temperature is 38.8 C (102 F). Physical examination shows marked tenderness over the right subcostal area. Leukocyte count is 18,000/mm^3 compared to 9,600/mm^3 2 days ago. Laparoscopic surgery is planned. Which of the following will most likely be found during this patient's surgery?

- A. Choledochal cyst
- B. Fibrotic and shrunken gallbladder
- C. Fluke infection of the biliary tree
- D. Inflamed and enlarged gallbladder
- E. Pigment gallstones
- F. Porcelain gallbladder

Submit

1 2 3 4 5 6 7 8 9 10 11 12 13 14 15 16 17 18 19 20 21 22 23 24 25 26 27 28 29 30

A 75-year-old hospitalized man is evaluated for abdominal pain and fever. The patient was admitted 2 weeks ago due to necrotizing fasciitis of the gluteal region and severe sepsis. He has been treated with surgical debridements, intravenous antibiotics, and fluids. For the past 2 days, the patient has had right upper quadrant abdominal pain, nausea, and recurrent fever. He has a history of hypertension, type 2 diabetes mellitus, and chronic obstructive pulmonary disease. His temperature is 38.8 C (102 F). Physical examination shows marked tenderness over the right subcostal area. Leukocyte count is 18,000/mm^3 compared to 9,600/mm^3 2 days ago. Laparoscopic surgery is planned. Which of the following will most likely be found during this patient's surgery?

- A. Choledochal cyst (2%)
- B. Fibrotic and shrunken gallbladder (1%)
- C. Fluke infection of the biliary tree (6%)
- ✓ D. Inflamed and enlarged gallbladder (71%)
- E. Pigment gallstones (13%)
- F. Porcelain gallbladder (4%)

Omitted
Correct answer
D

71%
Answered correctly

01 sec
Time Spent

05/18/2020
Last Updated

Explanation

This patient likely has acute **acalculous cholecystitis**, an acute inflammation of the gallbladder in the absence of gallstones. Acalculous cholecystitis most commonly occurs in **critically ill** patients (eg, those with sepsis, severe burns, trauma, immunosuppression) and is associated

This patient likely has acute **acalculous cholecystitis**, an acute inflammation of the gallbladder in the absence of gallstones. Acalculous cholecystitis most commonly occurs in **critically ill** patients (eg, those with sepsis, severe burns, trauma, immunosuppression) and is associated with high mortality. The condition is thought to arise secondary to gallbladder stasis and **ischemia**, which cause inflammation of and injury to the gallbladder wall.

Clinical manifestations may be subtle, especially in those who are sedated or intubated. **Fever, right upper quadrant pain**, a positive Murphy's sign, **leukocytosis**, and mild elevations in liver function tests are often present. Physical examination may demonstrate jaundice and a palpable right upper quadrant mass. The diagnostic study of choice is an ultrasound, which may show signs of acute cholecystitis (eg, an edematous and enlarged gallbladder) and **no gallstones**.

(Choice A) Choledochal cysts are congenital dilations of the common bile duct that typically present during childhood (age <10) with recurrent abdominal pain and jaundice.

(Choice B) Chronic cholecystitis results from repeated mild attacks of acute cholecystitis, which leads to thickening of the gallbladder wall. Ultrasound typically demonstrates a shrunken, fibrosed gallbladder.

(Choice C) Liver fluke infection usually affects individuals from endemic areas (eg, Southeast Asia) and presents acutely with fever, right upper quadrant pain, jaundice, and eosinophilia. Infection of the biliary tree is associated with the formation of brown pigment gallstones, not acute acalculous cholecystitis.

(Choice E) Pigment gallstones are categorized as black (typically secondary to intravascular hemolysis) or brown (typically secondary to biliary infection). These gallstones are associated with acute calculous cholecystitis, not acute acalculous cholecystitis.

(Choice F) Porcelain gallbladder is usually found incidentally on abdominal radiograph as a rim of calcium deposits outlining the gallbladder. The condition is associated with chronic cholecystitis and may increase the risk of gallbladder carcinoma.

Educational objective:
Acute acalculous cholecystitis is an acute inflammation of the gallbladder in the absence of gallstones. It typically occurs in critically ill patients (eg, those with sepsis, severe burns, trauma, immunosuppression) due to gallbladder stasis and ischemia. Clinical findings may be subtle and include fever, right upper quadrant pain, and leukocytosis.

enlarged gallbladder) and **no gallstones**.

(Choice A) Choledochal cysts are congenital dilations of the common bile duct that typically present during childhood (age <10) with recurrent abdominal pain and jaundice.

(Choice B) Chronic cholecystitis results from repeated mild attacks of acute cholecystitis, which leads to thickening of the gallbladder wall. Ultrasound typically demonstrates a shrunken, fibrosed gallbladder.

(Choice C) Liver fluke infection usually affects individuals from endemic areas (eg, Southeast Asia) and presents acutely with fever, right upper quadrant pain, jaundice, and eosinophilia. Infection of the biliary tree is associated with the formation of brown pigment gallstones, not acute acalculous cholecystitis.

(Choice E) Pigment gallstones are categorized as black (typically secondary to intravascular hemolysis) or brown (typically secondary to biliary infection). These gallstones are associated with acute calculous cholecystitis, not acute acalculous cholecystitis.

(Choice F) Porcelain gallbladder is usually found incidentally on abdominal radiograph as a rim of calcium deposits outlining the gallbladder. The condition is associated with chronic cholecystitis and may increase the risk of gallbladder carcinoma.

Educational objective:
Acute acalculous cholecystitis is an acute inflammation of the gallbladder in the absence of gallstones. It typically occurs in critically ill patients (eg, those with sepsis, severe burns, trauma, immunosuppression) due to gallbladder stasis and ischemia. Clinical findings may be subtle and include fever, right upper quadrant pain, and leukocytosis.

References

- Acute acalculous cholecystitis: a review.

Pathology	Gastrointestinal & Nutrition	Cholecystitis
Subject	System	Topic

Copyright © UWorld. All rights reserved.

A 45-year-old man with a history of alcohol abuse, chronic hepatitis C, and HIV is brought to the emergency department due to altered mental status and abdominal distension. He is disoriented and unable to provide an adequate history. He is accompanied by a friend who reports the patient's heavy drinking habits. The patient's breath has a sweet, feculent odor. Physical examination shows gynecomastia, palmar erythema, and multiple spider angiomata. The abdomen is severely distended and dilated periumbilical veins are noted. There is 3+ bilateral lower extremity edema. Genital examination shows testicular atrophy. Neurologic examination shows disorientation and asterixis. Abdominal imaging reveals splenomegaly. Which of the following findings in this patient has the same pathogenesis as his gynecomastia?

- A. Altered mental status
- B. Dilated periumbilical veins
- C. Lower extremity edema
- D. Spider angiomata
- E. Splenomegaly
- F. Sweet, feculent breath odor

Submit

1 2 3 4 5 6 7 8 9 10 11 12 13 14 15 16 17 18 19 20 21 22 23 24 25 26 27 28 29 30

A 45-year-old man with a history of alcohol abuse, chronic hepatitis C, and HIV is brought to the emergency department due to altered mental status and abdominal distension. He is disoriented and unable to provide an adequate history. He is accompanied by a friend who reports the patient's heavy drinking habits. The patient's breath has a sweet, feculent odor. Physical examination shows gynecomastia, palmar erythema, and multiple spider angiomata. The abdomen is severely distended and dilated periumbilical veins are noted. There is 3+ bilateral lower extremity edema. Genital examination shows testicular atrophy. Neurologic examination shows disorientation and asterixis. Abdominal imaging reveals splenomegaly. Which of the following findings in this patient has the same pathogenesis as his gynecomastia?

- A. Altered mental status (8%)
- B. Dilated periumbilical veins (3%)
- C. Lower extremity edema (7%)
- ✓ D. Spider angiomata (70%)
- E. Splenomegaly (2%)
- F. Sweet, feculent breath odor (6%)

Omitted
Correct answer
D

70%
Answered correctly

01 sec
Time Spent

02/19/2020
Last Updated

Explanation

Signs of liver cirrhosis

Settings

1 2 3 4 5 6 7 8 9 10 11 12 13 14 15 16 17 18 19 20 21 22 23 24 25 26 27 28 29 30

Item 11 of 38
Question Id: 100

Mark | Previous | Next | Full Screen | Tutorial | Lab Values | Notes | Calculator | Reverse Color | Text Zoom | Settings

Signs of liver cirrhosis

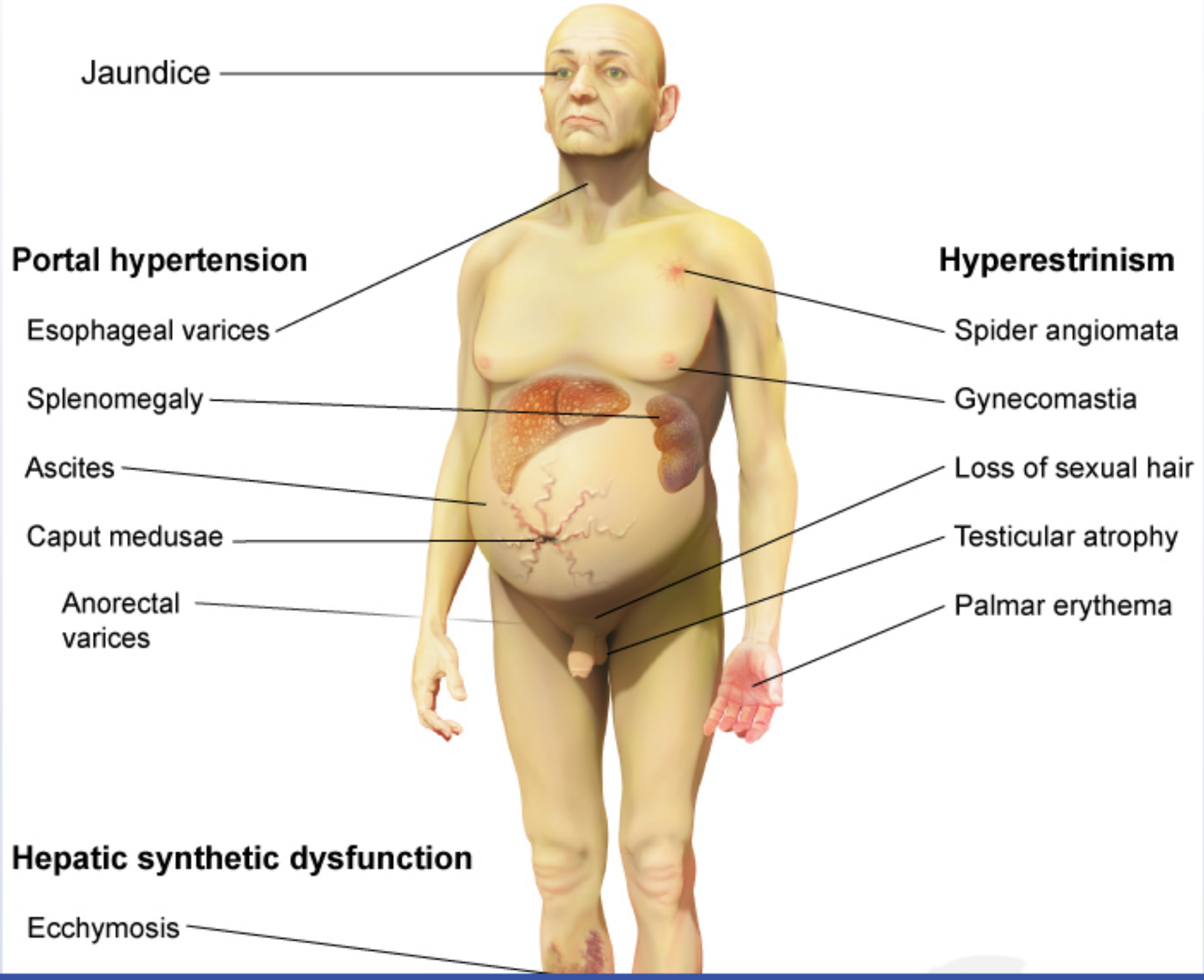

Block Time Remaining: 00:00:24
TUTOR

4 | Feedback | Suspend | End Block

This patient's numerous clinical findings are consistent with **liver cirrhosis**. In the cirrhotic patient, **gynecomastia** arises from **hyperestrinism** likely due to increased adrenal production of androstenedione with aromatization to estrone and eventual conversion to estradiol. Estradiol induces sex hormone-binding globulin production (primarily in the liver, but also in the uterus and testes), which results in increased testosterone binding and a decreased free testosterone/estrogen ratio. Impaired estrogen metabolism by the liver may also be a contributing factor. Other manifestations of hyperestrinism in the cirrhotic patient include spider angiomata and, in males, **testicular atrophy** with **decreased body hair**.

Spider angiomata are subcutaneous vascular lesions consisting of a central arteriole surrounded by many smaller vessels that blanch on compression. They are most frequently found on the trunk, face, and upper limbs. Acquired spider angiomata may also occur with other hyperestrogenic states (eg, pregnancy), possibly due to estrogen's effects on arteriolar dilation. The number and size of these skin lesions generally correlate with the severity of liver disease.

(Choices A and F) Altered mental status and malodorous, sweet, feculent breath (fetor hepaticus) are signs of poor hepatic function and accumulation of metabolic toxins (eg, ammonia, dimethyl sulfide). In the healthy liver, ammonia is detoxified to urea, which is then excreted in the urine. In the cirrhotic liver, ammonia accumulates in the blood, resulting in impaired neurotransmission in the central nervous system and possible brain edema.

(Choices B and E) Portal hypertension arises from increased hepatic resistance to portal flow at the sinusoids. This causes increased

compression. They are most frequently found on the trunk, face, and upper limbs. Acquired spider angiomata may also occur with other hyperestrogenic states (eg, pregnancy), possibly due to estrogen's effects on arteriolar dilation. The number and size of these skin lesions generally correlate with the severity of liver disease.

(Choices A and F) Altered mental status and malodorous, sweet, feculent breath (fetor hepaticus) are signs of poor hepatic function and accumulation of metabolic toxins (eg, ammonia, dimethyl sulfide). In the healthy liver, ammonia is detoxified to urea, which is then excreted in the urine. In the cirrhotic liver, ammonia accumulates in the blood, resulting in impaired neurotransmission in the central nervous system and possible brain edema.

(Choices B and E) Portal hypertension arises from increased hepatic resistance to portal flow at the sinusoids. This causes increased hydrostatic pressure at the portosystemic collateral veins in the anterior abdomen (eg, caput medusae), lower rectum (eg, anorectal varices), and lower esophagus (eg, esophageal varices). Portal hypertension also leads to ascites and venous congestion of the spleen (eg, splenomegaly).

(Choice C) The liver is the primary site of protein synthesis. Liver cirrhosis can result in decreased albumin production, leading to lower intravascular oncotic pressure with fluid extravasation and pitting edema in the lower extremities (pedal edema).

Educational objective:
Hyperestrinism in liver cirrhosis likely arises due to increases in androstenedione production, androgen aromatization, and sex hormone-binding globulin concentration (preferentially binds testosterone). Impaired estrogen metabolism by the liver may also be a contributing factor. A decreased free testosterone/estrogen ratio leads to gynecomastia, testicular atrophy, decreased body hair, and spider angiomata.

References

- Gynecomastia: pathophysiology, evaluation, and management.
- Spider angiomas in patients with liver cirrhosis: role of alcoholism and impaired liver function.

Pathology	Gastrointestinal & Nutrition	Cirrhosis
Subject	System	Topic

Copyright © UWorld. All rights reserved.

1 2 3 4 5 6 7 8 9 10 11 12 13 14 15 16 17 18 19 20 21 22 23 24 25 26 27 28 29 30

Laparotomy performed on a 35-year-old Caucasian male with abdominal pain shows chalky white lesions in the mesentery. Histologic evaluation of the lesions reveals fat cell destruction and calcium deposition. This patient most likely suffers from:

- A. Mesenteric ischemia
- B. Intestinal perforation
- C. Bacterial peritonitis
- D. Crohn's disease
- E. Acute pancreatitis
- F. Celiac disease

Submit

1 2 3 4 5 6 7 8 9 10 11 12 13 14 15 16 17 18 19 20 21 22 23 24 25 26 27 28 29 30

Laparotomy performed on a 35-year-old Caucasian male with abdominal pain shows chalky white lesions in the mesentery. Histologic evaluation of the lesions reveals fat cell destruction and calcium deposition. This patient most likely suffers from:

- A. Mesenteric ischemia (10%)
- B. Intestinal perforation (1%)
- C. Bacterial peritonitis (2%)
- D. Crohn's disease (6%)
- ✓ E. Acute pancreatitis (75%)
- F. Celiac disease (2%)

Omitted
Correct answer
E

75%
Answered correctly

01 sec
Time Spent

02/03/2020
Last Updated

Explanation

In acute pancreatitis, duct obstruction leads to stasis of pancreatic secretions and digestion of adipose cells by lipase. This results in formation of fatty acids that bind calcium ions and precipitate as insoluble calcium salts. The areas of focal necrosis and calcium precipitation induce an inflammatory reaction. If the pathologic process stops at this stage, benign **acute interstitial pancreatitis** develops. In this subtype of acute pancreatitis, the pancreas looks edematous on macroscopic examination. On light microscopy, interstitial edema, focal fat necrosis and calcium deposits are seen. If the inflammatory process continues, blood flow to the pancreatic acini is compromised as a result of the edema. Ischemia

In acute pancreatitis, duct obstruction leads to stasis of pancreatic secretions and digestion of adipose cells by lipase. This results in formation of fatty acids that bind calcium ions and precipitate as insoluble calcium salts. The areas of focal necrosis and calcium precipitation induce an inflammatory reaction. If the pathologic process stops at this stage, benign **acute interstitial pancreatitis** develops. In this subtype of acute pancreatitis, the pancreas looks edematous on macroscopic examination. On light microscopy, interstitial edema, focal fat necrosis and calcium deposits are seen. If the inflammatory process continues, blood flow to the pancreatic acini is compromised as a result of the edema. Ischemia damages the acinar cells and causes abnormal intracellular activation of trypsin. Trypsin then activates other proteolytic enzymes, thus initiating autodigestion (autolysis) of pancreatic tissue. **Acute necrotic pancreatitis** develops. Destruction of blood vessel walls can cause hemorrhage into the necrotic areas. Macroscopically, areas of white chalky fat necrosis are visible in the pancreatic tissue. They can spread onto the mesentery, omentum and other parts of abdominal cavity. Black areas of hemorrhage are also seen on gross examination.

(Choice A) In mesenteric ischemia an affected segment of the bowel is dusky red and congested. Subserosal ecchymoses, edema and/or well-defined areas of necrosis may be present.

(Choice B) Intestinal perforation (due to ulcer, mesenteric ischemia, tumor or inflammatory bowel disease) is characterized by the presence of a defect in the intestinal wall along with signs of peritonitis.

(Choice C) Bacterial peritonitis is characterized by a dull-appearing peritoneal surface with areas of viscous white-yellow suppurative exudate.

(Choice D) In Crohn's disease, mesenteric fat extends along the serosa of an affected segment ("creeping fat"). The intestinal serosa looks dull-gray, edematous and granular. The mesentery of an involved segment may be edematous or fibrotic.

(Choice F) The serosa and mesentery of an involved bowel segment appear normal in celiac disease.

Educational Objective:
In acute interstitial pancreatitis the pancreas is grossly edematous. Focal areas of fat necrosis, calcium deposition and interstitial edema are seen on light microscopy. In necrotizing (hemorrhagic) pancreatitis, chalky-white areas of fat necrosis interspersed with hemorrhage are seen on macroscopic examination.

Pathology | Gastrointestinal & Nutrition | Acute pancreatitis

1 2 3 4 5 6 7 8 9 10 11 12 13 14 15 16 17 18 19 20 21 22 23 24 25 26 27 28 29 30

A 34-year-old man is evaluated for elevated liver aminotransferases. The patient has no chronic medical conditions but has a history of injection drug use. Family history is notable for liver cirrhosis in his mother. Ultrasonography-guided liver biopsy is performed. Histopathology demonstrates marked panlobular mononuclear cell infiltration that cross into adjacent lobules. Occasional intensely eosinophilic round bodies are seen scattered amongst the hepatic parenchyma. Which of the following is the most likely cause of the latter histopathological finding in this patient?

A. Coagulative necrosis due to a toxin

B. Cytotoxic T-cell–mediated apoptosis

C. Intracellular pigment accumulation

D. Intracytoplasmic cytokeratin deposition

E. Small foci of fibrinoid necrosis

F. Stellate cell activation into myofibroblast

Submit

A 34-year-old man is evaluated for elevated liver aminotransferases. The patient has no chronic medical conditions but has a history of injection drug use. Family history is notable for liver cirrhosis in his mother. Ultrasonography-guided liver biopsy is performed. Histopathology demonstrates marked panlobular mononuclear cell infiltration that cross into adjacent lobules. Occasional intensely eosinophilic round bodies are seen scattered amongst the hepatic parenchyma. Which of the following is the most likely cause of the latter histopathological finding in this patient?

- A. Coagulative necrosis due to a toxin (5%)
- ✓ B. Cytotoxic T-cell–mediated apoptosis (44%)
- C. Intracellular pigment accumulation (7%)
- D. Intracytoplasmic cytokeratin deposition (19%)
- E. Small foci of fibrinoid necrosis (9%)
- F. Stellate cell activation into myofibroblast (13%)

Omitted
Correct answer
B

44%
Answered correctly

02 secs
Time Spent

04/03/2020
Last Updated

Explanation

This patient who has a history of intravenous drug use likely has elevated aminotransferases due to **acute viral hepatitis**. Most cases are marked by significant **panlobular lymphocytic inflammation**, which may "bridge" into adjacent hepatic lobules due to collapse of the reticulin framework. Spotty areas of hepatocyte injury are typically seen. Necrotic hepatocytes appear ballooned with pale cytoplasm (ballooning

This patient who has a history of intravenous drug use likely has elevated aminotransferases due to **acute viral hepatitis**. Most cases are marked by significant **panlobular lymphocytic inflammation**, which may "bridge" into adjacent hepatic lobules due to collapse of the reticulin framework. Spotty areas of hepatocyte injury are typically seen. Necrotic hepatocytes appear ballooned with pale cytoplasm (ballooning degeneration). Alternatively, hepatocytes may undergo **cytotoxic T-cell-mediated apoptosis** due to the presence of viral antigens on the hepatocyte surface. These apoptotic cells appear as round, acidophilic (pink on hematoxylin and eosin staining) bodies known as **Councilman bodies**.

Unlike acute viral hepatitis, chronic viral hepatitis is usually characterized by significant inflammation surrounding the portal triad (hepatic artery branch, portal vein branch, bile ductule). Hepatocytes usually have a ground-glass appearance (chronic hepatitis B virus) or an abundance of fat (chronic hepatitis C virus). Intravenous drug use is tightly linked to the transmission of hepatitis B and C virus.

(Choice A) Toxin-mediated hepatic injury (eg, due to acetaminophen) usually results in centrilobular hepatocyte necrosis (ie, centered around central veins) due to oxidative damage.

(Choice C) Hematochromatosis is characterized by the deposition of iron within hepatocytes, which results in the cells appearing pigmented when stained with Prussian blue. There is no fibrosis or inflammatory infiltrate.

(Choice D) Mallory bodies are damaged cytokeratin filaments within hepatocytes that usually arise in patients with alcoholism. They appear as highly eosinophilic inclusions on microscopy. Alcohol-mediated liver injury is associated with fat deposition in hepatocytes, particularly in the centrilobular region.

(Choice E) Aschoff bodies are small areas of granulomatous inflammation seen in the myocardium of patients with rheumatic heart disease. They are not seen in the liver.

(Choice F) Stellate cells reside in the hepatic perisinusoidal space and can transdifferentiate into myofibroblasts in response to liver injury; they are the primary cells associated with liver fibrosis. However, this patient has an inflammatory infiltrate and Councilman bodies, not fibrosis.

Educational objective:
Intravenous drug use is a major risk factor for hepatitis B and C viral infection. Acute viral hepatitis is marked by panlobular inflammation and hepatocyte necrosis and ballooning. Cytotoxic T-cell-mediated signals also cause hepatocyte apoptosis with the formation of intensely

Unlike acute viral hepatitis, chronic viral hepatitis is usually characterized by significant inflammation surrounding the portal triad (hepatic artery branch, portal vein branch, bile ductule). Hepatocytes usually have a ground-glass appearance (chronic hepatitis B virus) or an abundance of fat (chronic hepatitis C virus). Intravenous drug use is tightly linked to the transmission of hepatitis B and C virus.

(Choice A) Toxin-mediated hepatic injury (eg, due to acetaminophen) usually results in centrilobular hepatocyte necrosis (ie, centered around central veins) due to oxidative damage.

(Choice C) Hematochromatosis is characterized by the deposition of iron within hepatocytes, which results in the cells appearing pigmented when stained with Prussian blue. There is no fibrosis or inflammatory infiltrate.

(Choice D) Mallory bodies are damaged cytokeratin filaments within hepatocytes that usually arise in patients with alcoholism. They appear as highly eosinophilic inclusions on microscopy. Alcohol-mediated liver injury is associated with fat deposition in hepatocytes, particularly in the centrilobular region.

(Choice E) Aschoff bodies are small areas of granulomatous inflammation seen in the myocardium of patients with rheumatic heart disease. They are not seen in the liver.

(Choice F) Stellate cells reside in the hepatic perisinusoidal space and can transdifferentiate into myofibroblasts in response to liver injury; they are the primary cells associated with liver fibrosis. However, this patient has an inflammatory infiltrate and Councilman bodies, not fibrosis.

Educational objective:
Intravenous drug use is a major risk factor for hepatitis B and C viral infection. Acute viral hepatitis is marked by panlobular inflammation and hepatocyte necrosis and ballooning. Cytotoxic T-cell–mediated signals also cause hepatocyte apoptosis with the formation of intensely eosinophilic Councilman bodies.

Pathology	Gastrointestinal & Nutrition	Hepatitis c
Subject	System	Topic

Copyright © UWorld. All rights reserved.

Settings

1 2 3 4 5 6 7 8 9 10 11 12 13 14 15 16 17 18 19 20 21 22 23 24 25 26 27 28 29 30

Item 13 of 38
Question Id: 1927

Mark | Previous | Next | Full Screen | Tutorial | Lab Values | Notes | Calculator | Reverse Color | Text Zoom | Settings

bodies.

Exhibit Display

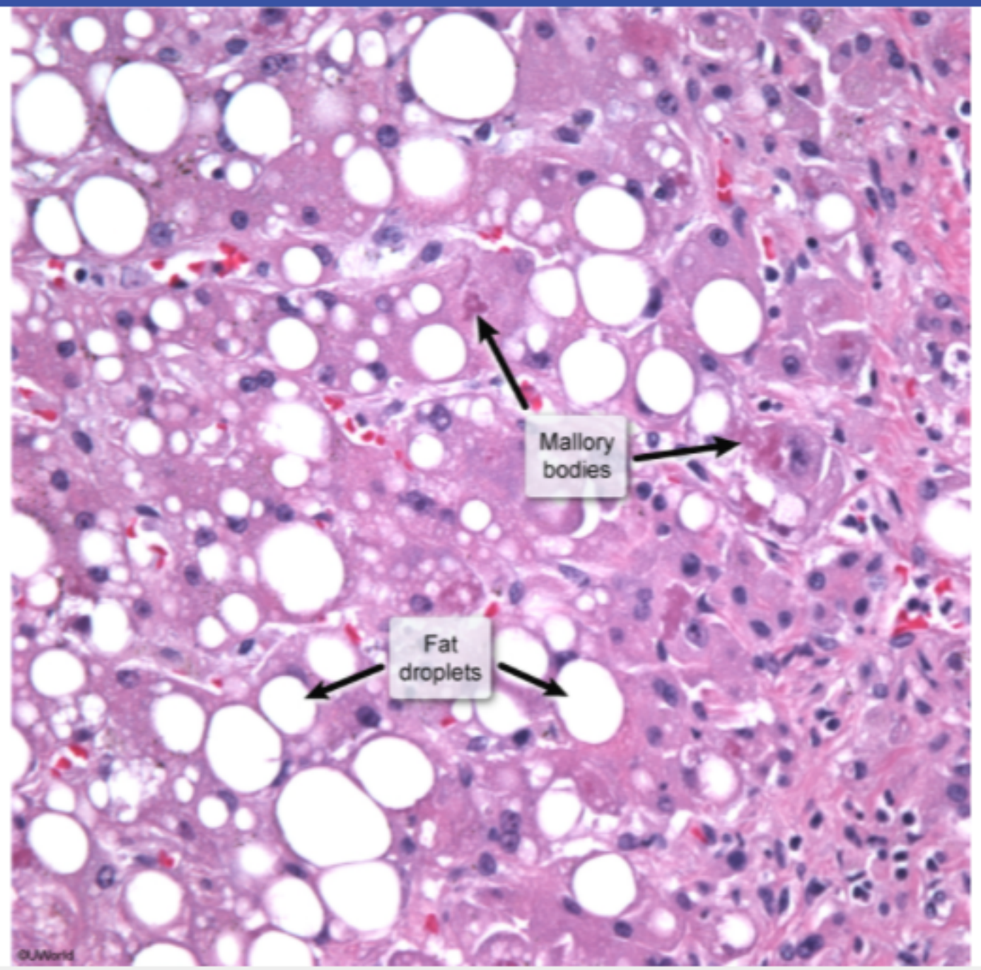

Zoom In | Zoom Out | Reset | Add To New Card | Existing Card

Block Time Remaining: 00:00:27
TUTOR

4 | Feedback | Suspend | End Block

Settings

1 2 3 4 5 6 7 8 9 10 11 12 13 14 15 16 17 18 19 20 21 22 23 24 25 26 27 28 29 30

Item 13 of 38
Question Id: 1927

Mark | Previous | Next | Full Screen | Tutorial | Lab Values | Notes | Calculator | Reverse Color | Text Zoom | Settings

Exhibit Display

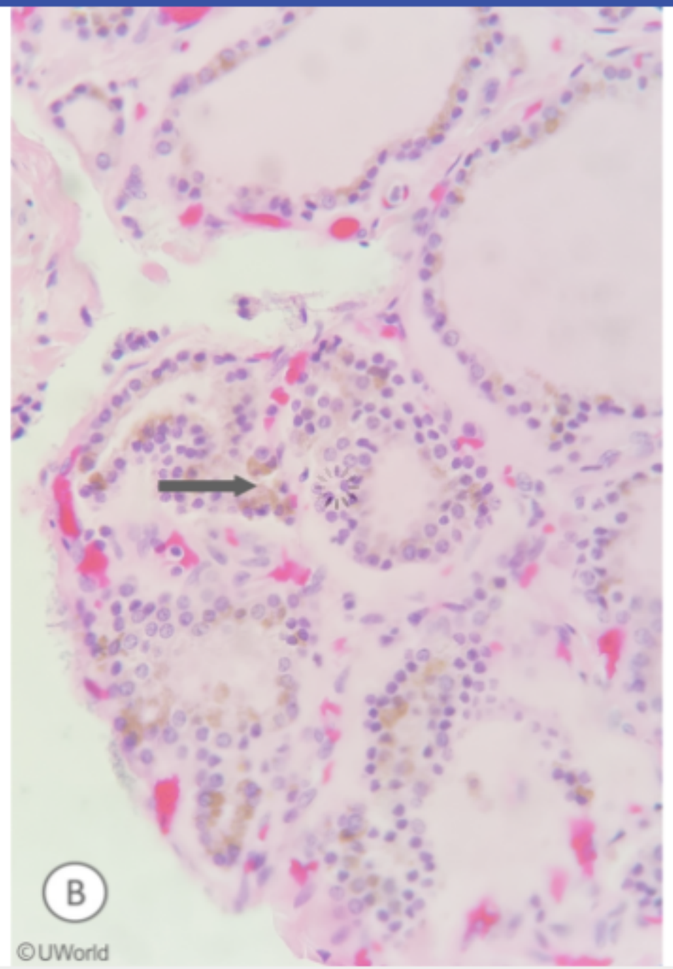

Zoom In | Zoom Out | Reset | Add To New Card | Existing Card

Block Time Remaining: 00:00:27
TUTOR

4 | Feedback | Suspend | End Block

A 54-year-old man dies from profuse upper gastrointestinal hemorrhage. An autopsy is performed; gross examination of his liver is shown in the image below.

Displayed with permission from Springer Healthcare Ltd. © Copyright 2006 by Current Medicine

This patient's condition most likely resulted from which of the following processes?

- A. Dilation of sinusoids and perivenular hemorrhages
- B. Fibrosis and nodular parenchymal regeneration
- C. Granulomatous destruction of bile ducts



Displayed with permission from Springer Healthcare Ltd. © Copyright 2006 by Current Medicine

This patient's condition most likely resulted from which of the following processes?

- A. Dilation of sinusoids and perivenular hemorrhages
- B. Fibrosis and nodular parenchymal regeneration
- C. Granulomatous destruction of bile ducts
- D. Intrahepatic hydatid cysts with surrounding fibrous reaction
- E. Pigment accumulation within hepatocytes

Submit



Displayed with permission from Springer Healthcare Ltd. © Copyright 2006 by Current Medicine

This patient's condition most likely resulted from which of the following processes?

- A. Dilation of sinusoids and perivenular hemorrhages (17%)
- ✓ B. Fibrosis and nodular parenchymal regeneration (71%)
- C. Granulomatous destruction of bile ducts (2%)
- D. Intrahepatic hydatid cysts with surrounding fibrous reaction (7%)
- E. Pigment accumulation within hepatocytes (1%)

Omitted
Correct answer

71%
Answered correctly

04 secs
Time Spent

06/13/2020
Last Updated

Explanation

Cirrhosis, the end stage of many chronic liver diseases, is characterized by **diffuse hepatic fibrosis** with replacement of the normal lobular architecture by fibrous-lined regenerative parenchymal nodules. The most common causes include **chronic viral hepatitis** (eg, hepatitis B and C), **alcohol**, hemochromatosis, and nonalcoholic fatty liver disease. **Portal hypertension**, from increased resistance to hepatic blood flow, typically develops in advanced cirrhosis and can lead to development of **gastroesophageal varices**. Untreated, these varices are prone to rupture and can result in a massive gastrointestinal hemorrhage and possibly death.

(Choice A) Dilation of sinusoids and perivenular hemorrhage are associated with acute venous outflow obstruction within the liver (eg, Budd-Chiari syndrome). Chronic hepatic vein obstruction is a rare cause of cirrhosis and portal hypertension.

(Choice C) Granulomatous destruction of bile ducts is seen in patients with primary biliary cirrhosis (PBC). Although PBC can cause cirrhosis, it is a far less common cause than alcohol or chronic hepatitis. Moreover, PBC occurs almost exclusively in women.

(Choice D) Intrahepatic hydatid cysts with surrounding fibrous reaction can be seen in patients with an *Echinococcus* infection, but it is a very rare disease in the United States.

(Choice E) Pigment accumulation within hepatocytes occurs in conditions such as Dubin-Johnson syndrome, an autosomal recessive disorder causing conjugated hyperbilirubinemia. In this condition, hepatocellular accumulation of coarse pigmented granules causes the liver to appear grossly black.

Educational objective:
Cirrhosis is characterized by diffuse hepatic fibrosis with replacement of the normal lobular architecture by fibrous-lined parenchymal nodules. Chronic viral hepatitis (eg, hepatitis B and C), alcohol, hemochromatosis, and nonalcoholic fatty liver disease are the most common causes of cirrhosis in the United States.

Pathology	Gastrointestinal & Nutrition	Cirrhosis
Subject	System	Topic

Copyright © UWorld. All rights reserved.

Settings

1
2
3
4
5
6
7
8
9
10
11
12
13
14
15
16
17
18
19
20
21
22
23
24
25
26
27
28
29
30

Item 14 of 38
Question Id: 368

Mark | Previous | Next | Full Screen | Tutorial | Lab Values | Notes | Calculator | Reverse Color | Text Zoom | Settings

Explanation

Exhibit Display

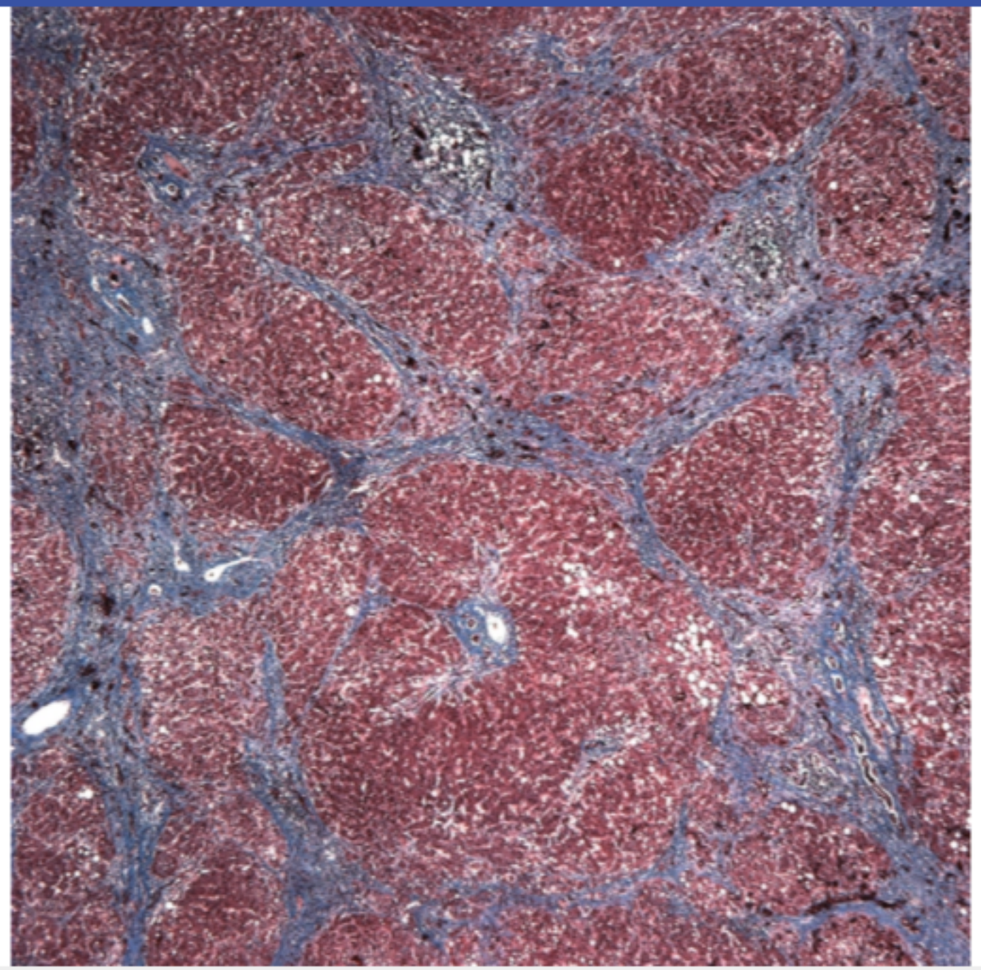

Zoom In | Zoom Out | Reset | Add To New Card | Existing Card

Block Time Remaining: 00:00:31
TUTOR

3 | Feedback | Suspend | End Block

A 72-year-old man develops mild abdominal pain and bloody diarrhea after undergoing urgent cholecystectomy. The surgery was complicated by an episode of hypotension that was treated with bolus intravenous crystalloid fluids. The patient had no previous gastrointestinal bleeding. His last colonoscopy 10 years ago was normal. Past medical history is notable for hypertension, hyperlipidemia, type 2 diabetes mellitus, and a myocardial infarction 7 years ago. The patient smoked for 40 years and quit after the myocardial infarction. Colonoscopy would most likely show pathology in which of the following portions of the large bowel?

- A. Ascending colon
- B. Cecum
- C. Hepatic flexure
- D. Rectosigmoid junction
- E. Mid-transverse colon

Submit

1 2 3 4 5 6 7 8 9 10 11 12 13 14 15 16 17 18 19 20 21 22 23 24 25 26 27 28 29 30

A 72-year-old man develops mild abdominal pain and bloody diarrhea after undergoing urgent cholecystectomy. The surgery was complicated by an episode of hypotension that was treated with bolus intravenous crystalloid fluids. The patient had no previous gastrointestinal bleeding. His last colonoscopy 10 years ago was normal. Past medical history is notable for hypertension, hyperlipidemia, type 2 diabetes mellitus, and a myocardial infarction 7 years ago. The patient smoked for 40 years and quit after the myocardial infarction. Colonoscopy would most likely show pathology in which of the following portions of the large bowel?

- A. Ascending colon (10%)
- B. Cecum (4%)
- C. Hepatic flexure (22%)
- ✓ D. Rectosigmoid junction (43%)
- E. Mid-transverse colon (18%)

Omitted
Correct answer
D

43%
Answered correctly

02 secs
Time Spent

02/09/2020
Last Updated

Explanation

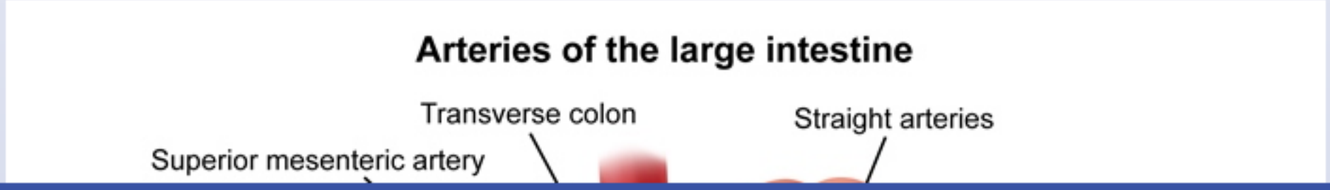

Settings

1 2 3 4 5 6 7 8 9 10 11 12 13 14 15 16 17 18 19 20 21 22 23 24 25 26 27 28 29 30

Item 15 of 38
Question Id: 413

Mark | Previous | Next | Full Screen | Tutorial | Lab Values | Notes | Calculator | Reverse Color | Text Zoom | Settings

Arteries of the large intestine

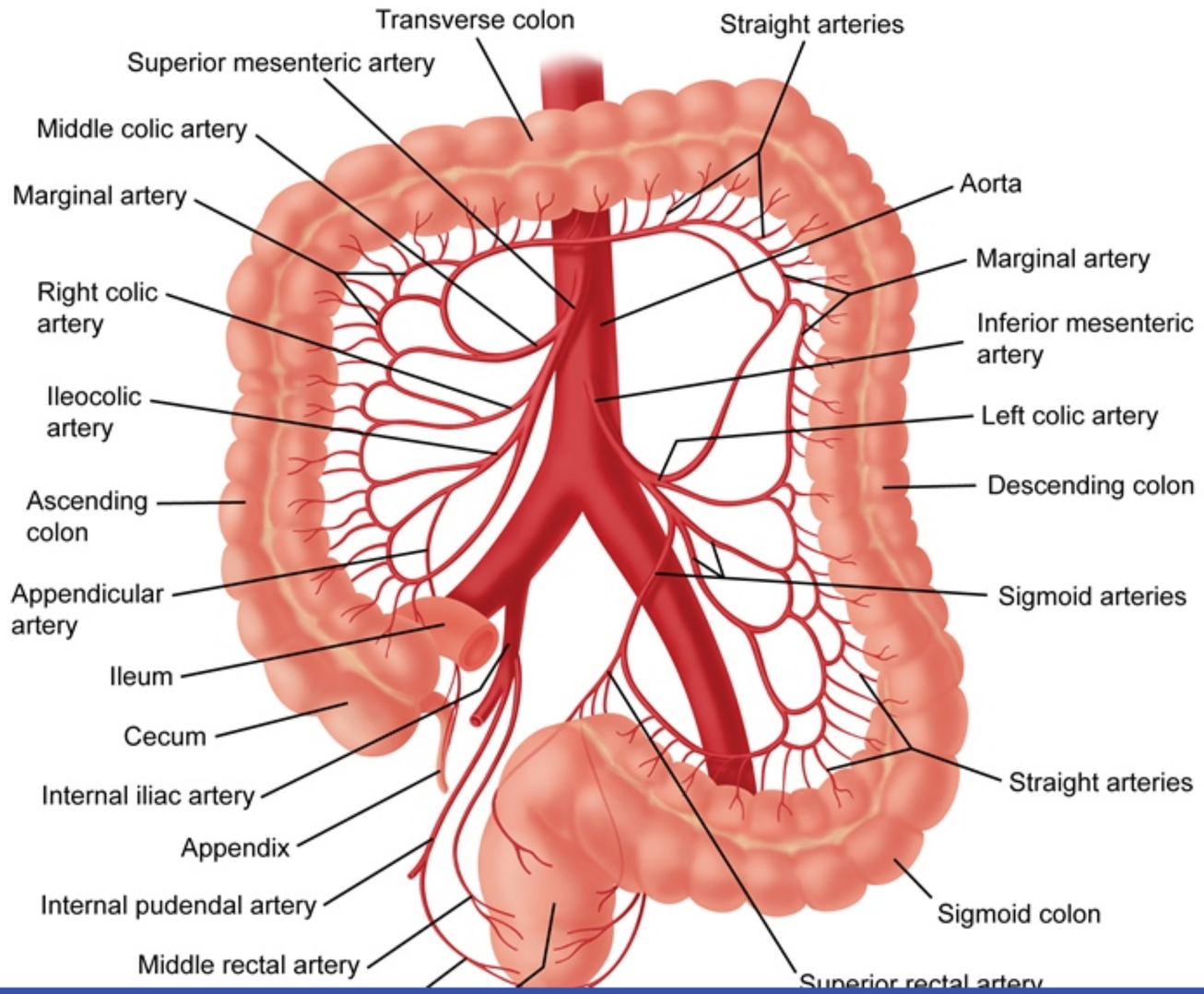

Block Time Remaining: 00:00:33
TUTOR

2 | Feedback | Suspend | End Block

©UWorld

Anus

This patient with abdominal pain and bloody diarrhea following a complicated surgical procedure likely has acute nonocclusive **ischemic colitis**. The colon receives blood from the marginal artery of the colon (artery of Drummond), an anastomotic system of arteries that is in turn supplied by the superior (SMA) and inferior (IMA) mesenteric artery systems. The distal colon receives blood also from the internal iliac artery.

In low-flow states, as may be seen in severe hypotension in patients with underlying arterial insufficiency (eg, diabetes, atherosclerotic arterial disease), **nonocclusive ischemia** may occur at the margins of the anastomotic distributions. These "**watershed**" areas are primarily in the left colon at the **splenic flexure** (border between SMA and IMA supply) and **rectosigmoid junction** (border between sigmoid artery and superior rectal artery). Less commonly, **occlusive ischemia** can also be caused by thromboembolic (eg, hypercoagulable states, atrial fibrillation) or atheroembolic (eg, aortic instrumentation) events.

Impaired perfusion to the bowel leads to ischemia and necrosis of the intestinal wall. Complications can include acidosis, sepsis, gangrene, and perforation. Colonoscopy will reveal pale mucosa and petechial hemorrhages.

(Choices A, B, C, and E) The ascending colon, cecum, hepatic flexure, and most of the transverse colon are supplied by branches of the SMA. Mesenteric ischemia in these areas is significantly less common than in the watershed areas of the left colon. Ischemia is also uncommon in the rectum, which receives collateral blood supply via the rectal arteries.

Educational objective:
The splenic flexure and rectosigmoid junction lie between regions of perfusion of major arteries. These "watershed" areas are susceptible to ischemic damage during hypotensive states, especially in patients with underlying arterial insufficiency.

References

- Clinical approach to colonic ischemia.

Pathology	Gastrointestinal & Nutrition	Colonic ischemia
Subject	System	Topic

Copyright © UWorld. All rights reserved.

A 40-year-old female presented to the physician for evaluation of worsening fatigue. She has no other medical problems. She does not use tobacco, alcohol or drugs. Vital signs are within normal limits. Physical examination is within normal limits. Laboratory evaluation shows an alkaline phosphatase level of 180 U/L. Which of the following should be checked next?

- A. Unconjugated bilirubin level
- B. Lactate dehydrogenase level
- C. Serum ammonia levels
- D. Prothrombin time
- E. γ-glutamyl transpeptidase
- F. Aspartate aminotransferase

Submit

1 2 3 4 5 6 7 8 9 10 11 12 13 14 15 16 17 18 19 20 21 22 23 24 25 26 27 28 29 30

A 40-year-old female presented to the physician for evaluation of worsening fatigue. She has no other medical problems. She does not use tobacco, alcohol or drugs. Vital signs are within normal limits. Physical examination is within normal limits. Laboratory evaluation shows an alkaline phosphatase level of 180 U/L. Which of the following should be checked next?

A. Unconjugated bilirubin level (18%)

B. Lactate dehydrogenase level (11%)

C. Serum ammonia levels (4%)

D. Prothrombin time (6%)

✓ E. γ-glutamyl transpeptidase (42%)

F. Aspartate aminotransferase (17%)

Omitted
Correct answer
E

42%
Answered correctly

02 secs
Time Spent

02/03/2020
Last Updated

Explanation

Broadly speaking, laboratory tests used in the evaluation of hepatobiliary disease either assess liver functionality (eg, prothrombin time, bilirubin, albumin, cholesterol) or the structural integrity and cellular intactness of the liver (eg, transaminases) or the biliary tract (eg, alkaline phosphatase, γ-glutamyl transferase).

Alkaline phosphatase represents a group of enzymes associated with metabolic activity in a number of tissues, including liver, bone, intestine, kidney, placenta, leukocytes, and some neoplasms. Bone and liver are the primary sources of alkaline phosphatase, with threefold elevations

Broadly speaking, laboratory tests used in the evaluation of hepatobiliary disease either assess liver functionality (eg, prothrombin time, bilirubin, albumin, cholesterol) or the structural integrity and cellular intactness of the liver (eg, transaminases) or the biliary tract (eg, alkaline phosphatase, γ-glutamyl transferase).

Alkaline phosphatase represents a group of enzymes associated with metabolic activity in a number of tissues, including liver, bone, intestine, kidney, placenta, leukocytes, and some neoplasms. Bone and liver are the primary sources of alkaline phosphatase, with threefold elevations considered a relatively nonspecific finding for many liver diseases. To clarify the importance of a moderately elevated alkaline phosphatase, the hepatic γ-glutamyl transpeptidase (GGTP) should be evaluated.

γ-glutamyl transpeptidase is an enzyme predominantly present in hepatocytes and biliary epithelia. While it too can be found in various extrahepatic tissues (organs such as kidney, spleen, pancreas, heart, lung, and brain), GGTP is not present to a significant extent in bone. It is therefore particularly useful in determining whether an elevated alkaline phosphatase is of hepatic or bony origin.

(Choice A) Measurement of unconjugated bilirubin (especially in contrast to conjugated bilirubin) can be of assistance in distinguishing hemolytic conditions from hepatic dysfunction or bile duct obstruction. This test is not particularly helpful in following up an elevated alkaline phosphatase.

(Choice B) Lactate dehydrogenase is a relatively nonspecific test that can be of some assistance in the evaluation of tissue injury or death. It is not the most helpful test in following up an elevated alkaline phosphatase.

(Choice C) Serum ammonia levels can be of assistance in determining the extent of liver failure or gastrointestinal bleeding, among other conditions. It is not the most helpful test in following up an elevated alkaline phosphatase.

(Choice D) Prothrombin time is of assistance in assessing coagulative ability and liver functionality, especially in the acute setting. It is not the most helpful test in following up an elevated alkaline phosphatase.

(Choice F) Aspartate aminotransferase is of assistance in assessing and monitoring hepatic damage. It is not the most helpful test in following up an elevated alkaline phosphatase.

Educational Objective:
A moderately elevated alkaline phosphatase of unclear etiology should be followed up with γ-glutamyl transpeptidase.

Alkaline phosphatase represents a group of enzymes associated with metabolic activity in a number of tissues, including liver, bone, intestine, kidney, placenta, leukocytes, and some neoplasms. Bone and liver are the primary sources of alkaline phosphatase, with threefold elevations considered a relatively nonspecific finding for many liver diseases. To clarify the importance of a moderately elevated alkaline phosphatase, the hepatic γ-glutamyl transpeptidase (GGTP) should be evaluated.

γ-glutamyl transpeptidase is an enzyme predominantly present in hepatocytes and biliary epithelia. While it too can be found in various extrahepatic tissues (organs such as kidney, spleen, pancreas, heart, lung, and brain), GGTP is not present to a significant extent in bone. It is therefore particularly useful in determining whether an elevated alkaline phosphatase is of hepatic or bony origin.

(Choice A) Measurement of unconjugated bilirubin (especially in contrast to conjugated bilirubin) can be of assistance in distinguishing hemolytic conditions from hepatic dysfunction or bile duct obstruction. This test is not particularly helpful in following up an elevated alkaline phosphatase.

(Choice B) Lactate dehydrogenase is a relatively nonspecific test that can be of some assistance in the evaluation of tissue injury or death. It is not the most helpful test in following up an elevated alkaline phosphatase.

(Choice C) Serum ammonia levels can be of assistance in determining the extent of liver failure or gastrointestinal bleeding, among other conditions. It is not the most helpful test in following up an elevated alkaline phosphatase.

(Choice D) Prothrombin time is of assistance in assessing coagulative ability and liver functionality, especially in the acute setting. It is not the most helpful test in following up an elevated alkaline phosphatase.

(Choice F) Aspartate aminotransferase is of assistance in assessing and monitoring hepatic damage. It is not the most helpful test in following up an elevated alkaline phosphatase.

Educational Objective:
A moderately elevated alkaline phosphatase of unclear etiology should be followed up with γ-glutamyl transpeptidase.

Pathology	Gastrointestinal & Nutrition	Abnormal lfts
Subject	System	Topic

Copyright © UWorld. All rights reserved.

An 81-year-old woman is brought to the emergency department by a neighbor due to abdominal pain. The pain comes in waves and is associated with nausea and vomiting. The patient is confused and unable to provide additional information. Past medical history is unknown, but she comes with a bag containing medications used in type 2 diabetes mellitus, hypercholesterolemia, hypertension, and dementia. On examination, the patient has a low-grade fever and mild tachycardia. She appears in distress due to pain. Mucous membranes are dry, and there is decreased skin turgor. Abdominal examination shows diffuse tenderness with high-pitched bowel sounds. Imaging of the abdomen reveals a complete small bowel obstruction. The patient undergoes laparotomy with extraction of a hard mass obstructing the ileocecal valve. The cholesterol content of the mass is 85%. Which of the following radiographic findings is most consistent with this patient's clinical presentation?

- A. Air in the biliary tree
- B. Distended bladder
- C. Free air in peritoneal cavity
- D. Heavily calcified arteries
- E. Pancreatic calcifications
- F. Pleural effusion

Submit

An 81-year-old woman is brought to the emergency department by a neighbor due to abdominal pain. The pain comes in waves and is associated with nausea and vomiting. The patient is confused and unable to provide additional information. Past medical history is unknown, but she comes with a bag containing medications used in type 2 diabetes mellitus, hypercholesterolemia, hypertension, and dementia. On examination, the patient has a low-grade fever and mild tachycardia. She appears in distress due to pain. Mucous membranes are dry, and there is decreased skin turgor. Abdominal examination shows diffuse tenderness with high-pitched bowel sounds. Imaging of the abdomen reveals a complete small bowel obstruction. The patient undergoes laparotomy with extraction of a hard mass obstructing the ileocecal valve. The cholesterol content of the mass is 85%. Which of the following radiographic findings is most consistent with this patient's clinical presentation?

- ✓ A. Air in the biliary tree (68%)
- B. Distended bladder (1%)
- C. Free air in peritoneal cavity (8%)
- D. Heavily calcified arteries (6%)
- E. Pancreatic calcifications (13%)
- F. Pleural effusion (0%)

Omitted
Correct answer
A

68%
Answered correctly

01 sec
Time Spent

02/09/2020
Last Updated

Explanation

Settings

1
2
3
4
5
6
7
8
9
10
11
12
13
14
15
16
17
18
19
20
21
22
23
24
25
26
27
28
29
30

Item 17 of 38
Question Id: 88

Mark | Previous | Next | Full Screen | Tutorial | Lab Values | Notes | Calculator | Reverse Color | Text Zoom | Settings

Gallstone ileus

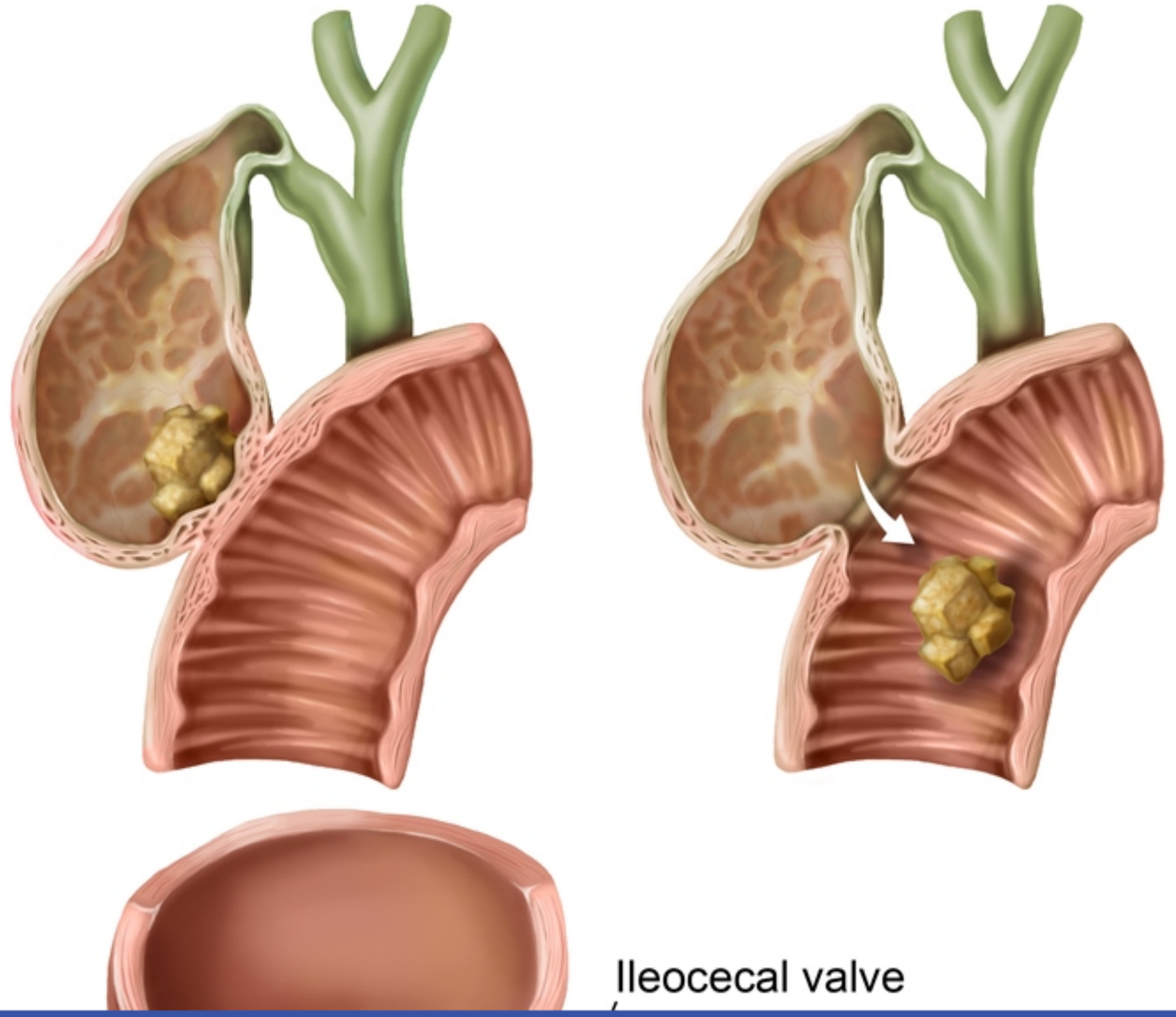

Block Time Remaining: 00:00:36
TUTOR

3 | Feedback | Suspend | End Block

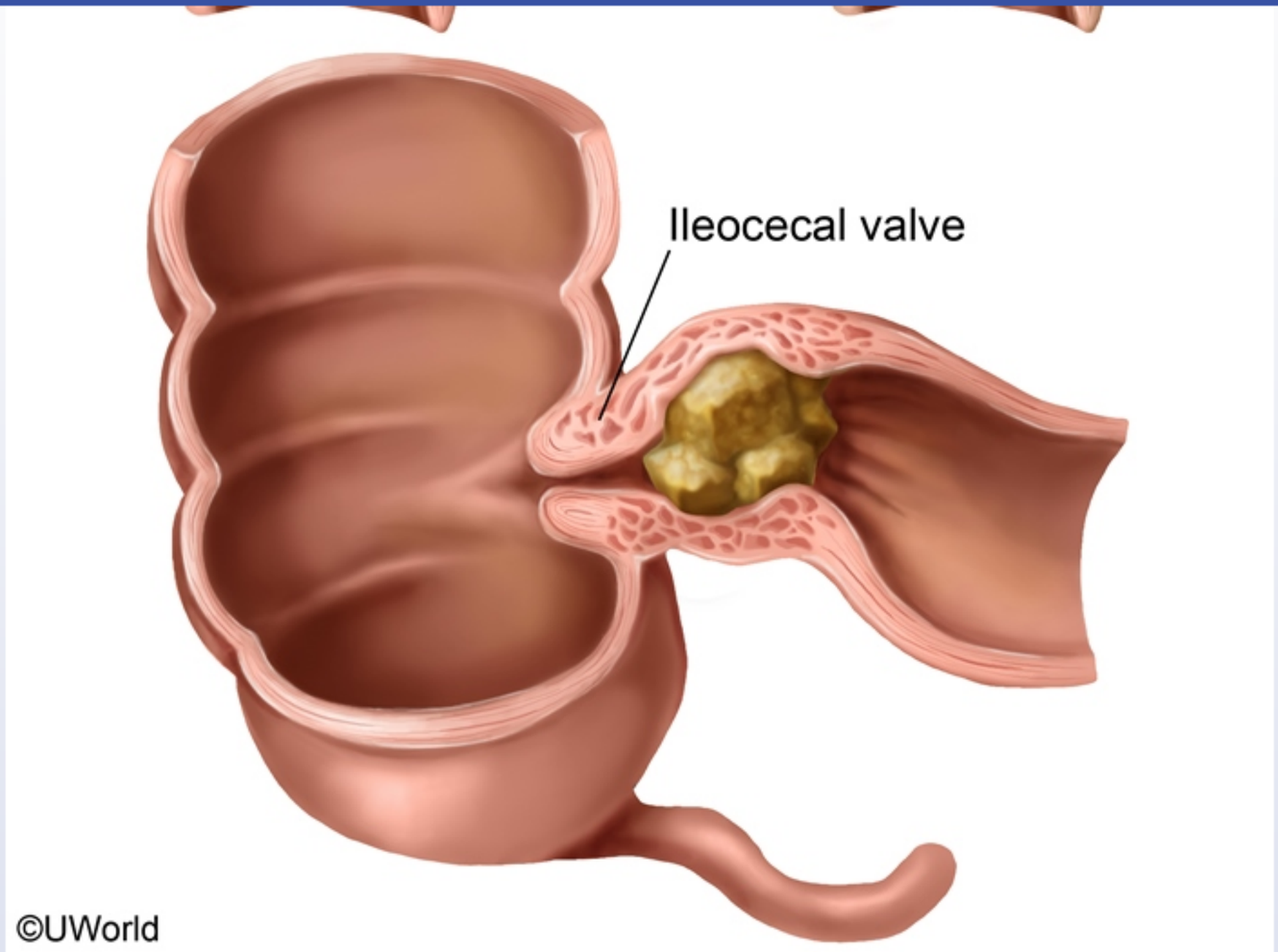

This patient, an older woman with intermittent abdominal pain and a cholesterol-containing mass lodged at the ileocecal valve, has a **gallstone ileus**. Gallstone ileus is not a true ileus (nonmechanical disruption of intestinal motility) but rather a mechanical obstruction that occurs when a large gallstone (usually >2.5 cm in diameter) erodes into the intestinal lumen through a **cholecystoenteric fistula**. As the gallstone travels down the intestine, it intermittently obstructs the lumen, causing episodic symptoms. Eventually, the gallstone may come to rest in the ileum, which has

This patient, an older woman with intermittent abdominal pain and a cholesterol-containing mass lodged at the ileocecal valve, has a **gallstone ileus**. Gallstone ileus is not a true ileus (nonmechanical disruption of intestinal motility) but rather a mechanical obstruction that occurs when a large gallstone (usually >2.5 cm in diameter) erodes into the intestinal lumen through a **cholecystoenteric fistula**. As the gallstone travels down the intestine, it intermittently obstructs the lumen, causing episodic symptoms. Eventually, the gallstone may come to rest in the ileum, which has the smallest lumen of the intestinal tract.

Typical symptoms of gallstone ileus include crampy pain, vomiting, and bloating. Examination will show signs of **small bowel obstruction**, such as abdominal distension, tenderness, and high-pitched (tinkling) bowel sounds. Abdominal radiographs may reveal dilated bowel loops with air-fluid levels. Careful inspection may also reveal air in the biliary tree (**pneumobilia**) due to retrograde passage of intestinal gas through the fistula.

(Choice B) Bladder distension due to urinary retention is most often associated with underlying prostatic hyperplasia, anticholinergic medication use, and underlying neurologic impairment.

(Choice C) Air in the peritoneal cavity is suggestive of bowel perforation. Although the bowel wall is disrupted in gallstone ileus, the cholecystoenteric fistula is usually associated with fibrotic adhesions between the biliary tree and the bowel, and there is no free communication with the peritoneal cavity.

(Choice D) Heavily calcified vessels are a sign of chronic atherosclerotic arterial disease. Common intra-abdominal complications in such patients would include intestinal ischemia and abdominal aortic aneurysm.

(Choice E) Pancreatic calcifications are suggestive of chronic pancreatitis, which is most commonly seen in alcohol abuse, cystic fibrosis, or outlet obstruction due to tumor, pseudocysts, or recurrent passage of gallstones.

(Choice F) Pleural effusion may be seen in a broad range of intra-abdominal conditions, such as pancreatitis, esophageal rupture, or chronic hepatic or renal disease.

Educational objective:
Gallstone ileus is a mechanical bowel obstruction caused when a large gallstone erodes into the intestinal lumen. Pneumobilia (air in the biliary tract) is a common finding.

References

1 2 3 4 5 6 7 8 9 10 11 12 13 14 15 16 17 18 19 20 21 22 23 24 25 26 27 28 29 30

Typical symptoms of gallstone ileus include crampy pain, vomiting, and bloating. Examination will show signs of **small bowel obstruction**, such as abdominal distension, tenderness, and high-pitched (tinkling) bowel sounds. Abdominal radiographs may reveal dilated bowel loops with air-fluid levels. Careful inspection may also reveal air in the biliary tree (**pneumobilia**) due to retrograde passage of intestinal gas through the fistula.

(Choice B) Bladder distension due to urinary retention is most often associated with underlying prostatic hyperplasia, anticholinergic medication use, and underlying neurologic impairment.

(Choice C) Air in the peritoneal cavity is suggestive of bowel perforation. Although the bowel wall is disrupted in gallstone ileus, the cholecystoenteric fistula is usually associated with fibrotic adhesions between the biliary tree and the bowel, and there is no free communication with the peritoneal cavity.

(Choice D) Heavily calcified vessels are a sign of chronic atherosclerotic arterial disease. Common intra-abdominal complications in such patients would include intestinal ischemia and abdominal aortic aneurysm.

(Choice E) Pancreatic calcifications are suggestive of chronic pancreatitis, which is most commonly seen in alcohol abuse, cystic fibrosis, or outlet obstruction due to tumor, pseudocysts, or recurrent passage of gallstones.

(Choice F) Pleural effusion may be seen in a broad range of intra-abdominal conditions, such as pancreatitis, esophageal rupture, or chronic hepatic or renal disease.

Educational objective:
Gallstone ileus is a mechanical bowel obstruction caused when a large gallstone erodes into the intestinal lumen. Pneumobilia (air in the biliary tract) is a common finding.

References

- Gallstone ileus: case report and literature review.

Pathology	Gastrointestinal & Nutrition	Bowel obstruction
Subject	System	Topic

Copyright © UWorld. All rights reserved.

1 2 3 4 5 6 7 8 9 10 11 12 13 14 15 16 17 18 19 20 21 22 23 24 25 26 27 28 29 30

A 35-year-old woman comes to the clinic due to severe heartburn that is resistant to over-the-counter antacids. The patient has no known medical problems and takes no other medications. She occasionally has a glass of wine with dinner but does not use tobacco or illicit drugs. Physical examination shows scattered telangiectasias on the face, several ulcers at the tips of the fingers, and small calcium deposits in the soft tissues of the hands and elbows. Which of the following processes is the most likely cause of this patient's heartburn?

A. Abnormal location of the gastroesophageal junction

B. Fibrous replacement of the muscularis in the lower esophagus

C. Increased gastric acid production

D. Increase in resting lower esophageal sphincter tone

E. Uncoordinated, simultaneous muscle contractions in the lower esophagus

Submit

A 35-year-old woman comes to the clinic due to severe heartburn that is resistant to over-the-counter antacids. The patient has no known medical problems and takes no other medications. She occasionally has a glass of wine with dinner but does not use tobacco or illicit drugs. Physical examination shows scattered telangiectasias on the face, several ulcers at the tips of the fingers, and small calcium deposits in the soft tissues of the hands and elbows. Which of the following processes is the most likely cause of this patient's heartburn?

A. Abnormal location of the gastroesophageal junction (3%)

✓ B. Fibrous replacement of the muscularis in the lower esophagus (55%)

C. Increased gastric acid production (16%)

D. Increase in resting lower esophageal sphincter tone (6%)

E. Uncoordinated, simultaneous muscle contractions in the lower esophagus (17%)

Omitted
Correct answer
B

55%
Answered correctly

01 sec
Time Spent

02/12/2020
Last Updated

Explanation

This patient has features consistent with **CREST syndrome** (ie, Calcinosis, **R**aynaud phenomenon, **E**sophageal dysmotility, **S**clerodactyly, Telangiectasia), a limited variant of systemic sclerosis with skin disease that primarily affects the face, forearms, and fingers. The pathogenesis of systemic sclerosis involves chronic autoimmune inflammation, vascular endothelial injury resulting in chronic ischemic tissue damage (eg, fingertip ulcers), and excessive activation of fibroblasts leading to progressive tissue fibrosis.

Esophageal dysmotility is a result of **atrophy** and **fibrous replacement** of the muscularis in the lower esophagus. The esophageal body and the

Explanation

This patient has features consistent with **CREST syndrome** (ie, Calcinosis, Raynaud phenomenon, Esophageal dysmotility, Sclerodactyly, Telangiectasia), a limited variant of systemic sclerosis with skin disease that primarily affects the face, forearms, and fingers. The pathogenesis of systemic sclerosis involves chronic autoimmune inflammation, vascular endothelial injury resulting in chronic ischemic tissue damage (eg, fingertip ulcers), and excessive activation of fibroblasts leading to progressive tissue fibrosis.

Esophageal dysmotility is a result of **atrophy** and **fibrous replacement** of the muscularis in the lower esophagus. The esophageal body and the lower esophageal sphincter become atonic and dilated, resulting in symptoms of **gastroesophageal reflux** (eg, heartburn, regurgitation, dysphagia). This increases the risk of Barrett's esophagus and fibrous stricture formation.

(Choice A) A sliding hiatal hernia is characterized by herniation of the gastroesophageal junction and a portion of the stomach through the esophageal hiatus, which predisposes patients to gastroesophageal reflux.

(Choice C) Increased gastric acid production occurs with gastrinomas, gastrin-secreting neuroendocrine tumors of the small intestine/pancreas that often present with multiple or medically refractory peptic ulcers.

(Choice D) Achalasia is an esophageal motility disorder characterized by failed relaxation of the lower esophageal sphincter resulting in food retention, dilation of the esophageal body, and symptoms of solid/liquid dysphagia.

(Choice E) Diffuse esophageal spasm is characterized by periodic, uncoordinated, simultaneous contractions of the lower esophagus due to impaired inhibitory innervation within the esophageal myenteric plexus. Patients typically have liquid/solid dysphagia and chest pain due to inefficient propagation of food into the stomach.

Educational objective:
Systemic sclerosis may result in esophageal dysmotility and incompetence of the lower esophageal sphincter due to atrophy and fibrous replacement of the esophageal muscularis. This can cause gastroesophageal reflux with an increased risk of Barrett's esophagus and stricture formation.

References

- Diagnosis and classification of systemic sclerosis

Settings

1 2 3 4 5 6 7 8 9 10 11 12 13 14 15 16 17 18 19 20 21 22 23 24 25 26 27 28 29 30

Item 18 of 38
Question Id: 284

Mark | Previous | Next | Full Screen | Tutorial | Lab Values | Notes | Calculator | Reverse Color | Text Zoom | Settings

Explanation

Exhibit Display

Calcinosis Calcinosis cutis

Zoom In | Zoom Out | Reset | Add To New Card | Existing Card

Diagnosis and classification of systemic sclerosis

Block Time Remaining: 00:00:37
TUTOR

7 | Feedback | Suspend | End Block

Settings

1 2 3 4 5 6 7 8 9 10 11 12 13 14 15 16 17 18 19 20 21 22 23 24 25 26 27 28 29 30

Item 18 of 38
Question Id: 284

Mark | Previous | Next | Full Screen | Tutorial | Lab Values | Notes | Calculator | Reverse Color | Text Zoom | Settings

Explanation

Exhibit Display

Calcinosis Calcinosis cutis

Zoom In | Zoom Out | Reset | Add To New Card | Existing Card

Diagnosis and classification of systemic sclerosis

Block Time Remaining: 00:00:37
TUTOR

7 | Feedback | Suspend | End Block

Settings

1
2
3
4
5
6
7
8
9
10
11
12
13
14
15
16
17
18
19
20
21
22
23
24
25
26
27
28
29
30

Item 18 of 38
Question Id: 284

Mark | Previous | Next | Full Screen | Tutorial | Lab Values | Notes | Calculator | Reverse Color | Text Zoom | Settings

Explanation

Exhibit Display

Zoom In | Zoom Out | Reset | Add To New Card | Existing Card

Diagnosis and classification of systemic sclerosis

Block Time Remaining: 00:00:37
TUTOR

7 | Feedback | Suspend | End Block

Settings

1
2
3
4
5
6
7
8
9
10
11
12
13
14
15
16
17
18
19
20
21
22
23
24
25
26
27
28
29
30

Item 18 of 38
Question Id: 284

Mark | Previous | Next | Full Screen | Tutorial | Lab Values | Notes | Calculator | Reverse Color | Text Zoom | Settings

Exhibit Display

Zoom In | Zoom Out | Reset | Add To New Card | Existing Card

Diagnosis and classification of systemic sclerosis

Block Time Remaining: 00:00:37
TUTOR

7 | Feedback | Suspend | End Block

Settings

1
2
3
4
5
6
7
8
9
10
11
12
13
14
15
16
17
18
19
20
21
22
23
24
25
26
27
28
29
30

Item 18 of 38
Question Id: 284

Mark | Previous | Next | Full Screen | Tutorial | Lab Values | Notes | Calculator | Reverse Color | Text Zoom | Settings

Exhibit Display

Zoom In | Zoom Out | Reset | Add To New Card | Existing Card

Diagnosis and classification of systemic sclerosis

Block Time Remaining: 00:00:37
TUTOR

7 | Feedback | Suspend | End Block

Settings

1
2
3
4
5
6
7
8
9
10
11
12
13
14
15
16
17
18
19
20
21
22
23
24
25
26
27
28
29
30

Item 18 of 38
Question Id: 284

Mark | Previous | Next | Full Screen | Tutorial | Lab Values | Notes | Calculator | Reverse Color | Text Zoom | Settings

Exhibit Display

Spider angioma

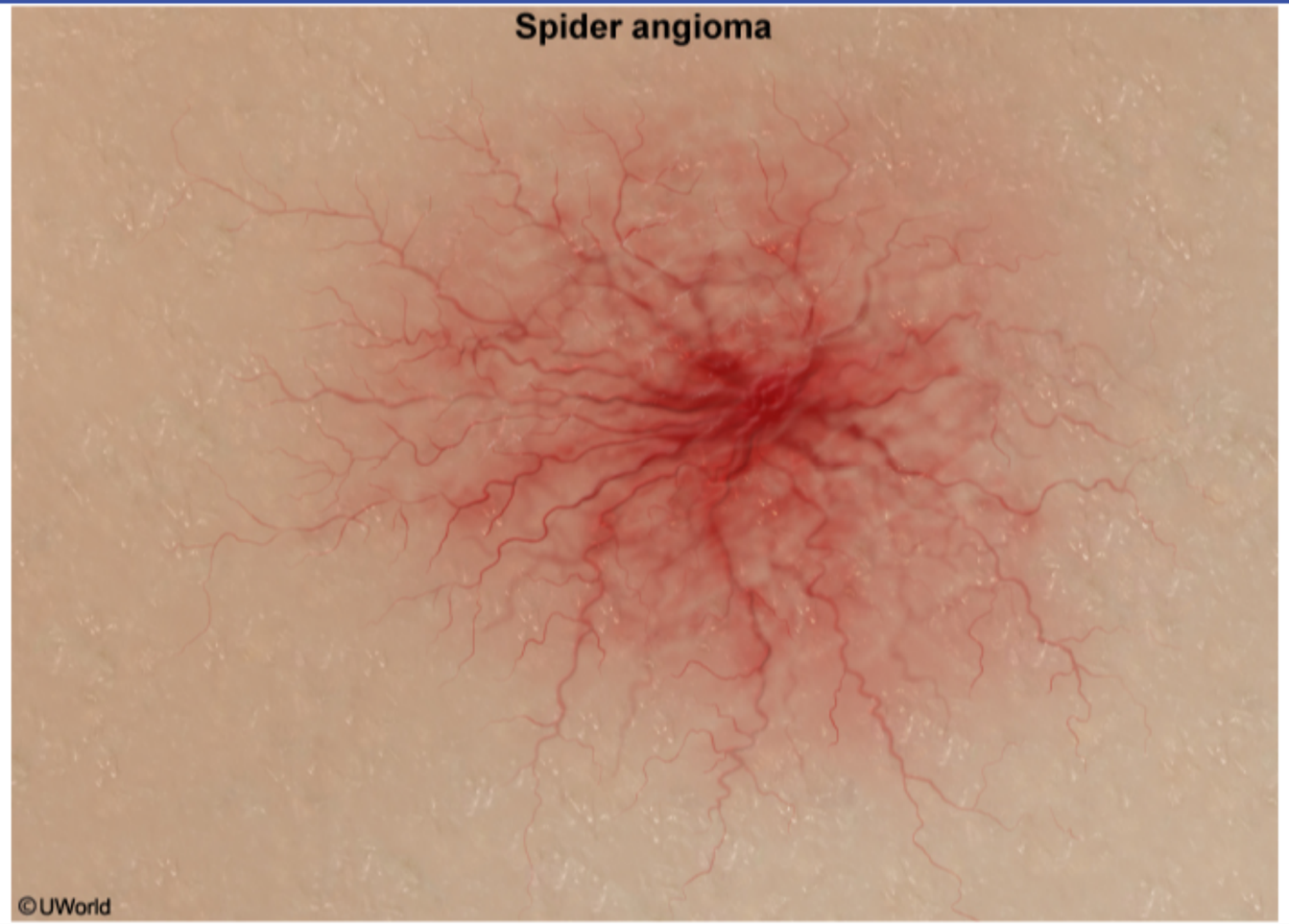

Zoom In | Zoom Out | Reset | Add To New Card | Existing Card

Diagnosis and classification of systemic sclerosis

Block Time Remaining: 00:00:37
TUTOR

7 | Feedback | Suspend | End Block

1 2 3 4 5 6 7 8 9 10 11 12 13 14 15 16 17 18 19 20 21 22 23 24 25 26 27 28 29 30

A 32-year-old man comes to the clinic for peptic ulcer disease follow-up. The patient has received several months of proton pump inhibitor therapy without significant improvement in his epigastric discomfort. He does not use nonsteroidal anti-inflammatory drugs, tobacco, or alcohol. *Helicobacter pylori* testing is negative. The patient undergoes a partial gastrectomy for refractory peptic ulcer disease. The pathologist receives the tissue and notes significant enlargement of the gastric rugal folds on gross examination. Microscopy of the gastric mucosa reveals parietal cell hyperplasia. Which of the following stimuli is the most likely cause of parietal cell proliferation in this patient?

A. Acetylcholine

B. Gastrin

C. Secretin

D. Serotonin

E. Somatostatin

F. Transforming growth factor alpha

Submit

1 2 3 4 5 6 7 8 9 10 11 12 13 14 15 16 17 18 19 20 21 22 23 24 25 26 27 28 29 30

A 32-year-old man comes to the clinic for peptic ulcer disease follow-up. The patient has received several months of proton pump inhibitor therapy without significant improvement in his epigastric discomfort. He does not use nonsteroidal anti-inflammatory drugs, tobacco, or alcohol. *Helicobacter pylori* testing is negative. The patient undergoes a partial gastrectomy for refractory peptic ulcer disease. The pathologist receives the tissue and notes significant enlargement of the gastric rugal folds on gross examination. Microscopy of the gastric mucosa reveals parietal cell hyperplasia. Which of the following stimuli is the most likely cause of parietal cell proliferation in this patient?

- A. Acetylcholine (7%)
- ✓ B. Gastrin (82%)
- C. Secretin (3%)
- D. Serotonin (0%)
- E. Somatostatin (1%)
- F. Transforming growth factor alpha (3%)

Omitted
Correct answer
B

82%
Answered correctly

02 secs
Time Spent

06/29/2020
Last Updated

Explanation

Parietal cells are located in the gastric glands of the fundus and body of the stomach. They can be spotted easily due to their eosinophilic cytoplasm on H&E stain. These cells have abundant mitochondria and an intracellular tubulovesicular system that allows them to secrete large quantities of gastric acid (HCl) and intrinsic factor.

Parietal cells are located in the gastric glands of the fundus and body of the stomach. They can be spotted easily due to their eosinophilic cytoplasm on H&E stain. These cells have abundant mitochondria and an intracellular tubulovesicular system that allows them to secrete large quantities of gastric acid (HCl) and intrinsic factor.

Parietal cells are influenced by a number of substances. Histamine, acetylcholine, and gastrin increase gastric acid secretion, but prostaglandins inhibit it. **Gastrin** not only stimulates **HCl secretion**, but it also has a **trophic effect** on parietal cells. In patients with Zollinger-Ellison syndrome (such as this patient), gastrin hypersecretion induces **parietal cell hyperplasia**, causing visible **enlargement of gastric folds** on endoscopy. The increased gastric acid secretion induced by excess gastrin also causes peptic ulcer disease, heartburn, and diarrhea.

(Choice A) Acetylcholine is a universal neurotransmitter that is present in parasympathetic postganglionic synapses and in all autonomic preganglionic synapses. Cholinergic receptors are divided into muscarinic (located in smooth muscle and glands) and nicotinic (found at the neuromuscular junction). Acetylcholine stimulates parietal cell acid secretion but is not typically associated with parietal cell hyperplasia or gastric fold enlargement.

(Choice C) Secretin is produced by S cells of the small intestine. It increases bicarbonate production by the pancreas and leads to the secretion of watery, alkaline pancreatic juice. This substance also inhibits gastric acid secretion and stimulates pyloric sphincter contraction.

(Choice D) Serotonin (5HT) is primarily found in enterochromaffin cells of the gastrointestinal (GI) tract, the central nervous system, and platelets. In the GI tract, it helps to regulate intestinal secretions and peristalsis.

(Choice E) Somatostatin (growth hormone-inhibiting hormone) is secreted by D cells of pancreatic islets and GI mucosa. It has multiple inhibitory effects over the GI tract, including decreasing motility, gastrin secretion, pancreatic endocrine/exocrine secretion, and absorption of nutrients.

(Choice F) Transforming growth factor alpha (TGF-α) is a potent stimulator of epithelial growth and is secreted by carcinomas, macrophages, and epithelial cells. Menetrier disease is associated with overproduction of TGF-α, resulting in mucosal-cell hyperplasia with gastric fold enlargement. However, the condition causes hypoplasia of parietal/chief cells, resulting in glandular atrophy with reduced gastric acid secretion.

Educational objective:
Patients with Zollinger-Ellison syndrome develop peptic ulcer disease and parietal cell hyperplasia with gastric fold enlargement due to gastrin hypersecretion.

preganglionic synapses. Cholinergic receptors are divided into muscarinic (located in smooth muscle and glands) and nicotinic (found at the neuromuscular junction). Acetylcholine stimulates parietal cell acid secretion but is not typically associated with parietal cell hyperplasia or gastric fold enlargement.

(Choice C) Secretin is produced by S cells of the small intestine. It increases bicarbonate production by the pancreas and leads to the secretion of watery, alkaline pancreatic juice. This substance also inhibits gastric acid secretion and stimulates pyloric sphincter contraction.

(Choice D) Serotonin (5HT) is primarily found in enterochromaffin cells of the gastrointestinal (GI) tract, the central nervous system, and platelets. In the GI tract, it helps to regulate intestinal secretions and peristalsis.

(Choice E) Somatostatin (growth hormone-inhibiting hormone) is secreted by D cells of pancreatic islets and GI mucosa. It has multiple inhibitory effects over the GI tract, including decreasing motility, gastrin secretion, pancreatic endocrine/exocrine secretion, and absorption of nutrients.

(Choice F) Transforming growth factor alpha (TGF-α) is a potent stimulator of epithelial growth and is secreted by carcinomas, macrophages, and epithelial cells. Menetrier disease is associated with overproduction of TGF-α, resulting in mucosal-cell hyperplasia with gastric fold enlargement. However, the condition causes hypoplasia of parietal/chief cells, resulting in glandular atrophy with reduced gastric acid secretion.

Educational objective:
Patients with Zollinger-Ellison syndrome develop peptic ulcer disease and parietal cell hyperplasia with gastric fold enlargement due to gastrin hypersecretion.

References

- Zollinger-Ellison Syndrome.
- Role of gastrointestinal hormones in the proliferation of normal and neoplastic tissues.

Pathology	Gastrointestinal & Nutrition	Zollinger ellison syndrome
Subject	System	Topic

Copyright © UWorld. All rights reserved.

1 2 3 4 5 6 7 8 9 10 11 12 13 14 15 16 17 18 19 20 21 22 23 24 25 26 27 28 29 30

A 65-year-old man comes to the office with dysphagia. For the last 3 months, he has relied on protein shakes and juices for nourishment as he has had difficulty swallowing solid foods. He has also had a diminished appetite and an estimated weight loss of 9.1 kg (20 lb). Medical history includes hyperlipidemia, emphysema, and previous episodes of pancreatitis. Family history includes lung cancer in his mother. The patient smoked a pack of cigarettes daily for 50 years but quit 2 years ago. He has been drinking a fifth (750 mL) of vodka weekly for the last decade. Vital signs are normal. BMI is 19.2 kg/m^2. Temporal wasting is present but physical examination is otherwise unremarkable. Upper endoscopy reveals a 4-cm mass in the middle third of the esophagus, and several biopsies are taken. Thoracic imaging reveals mediastinal lymphadenopathy. Histologic evaluation of the biopsy specimens will most likely show which of the following in this patient?

A. Intestinal cells without dysplasia

B. Irregular glandular cells with tissue invasion

C. Keratin pearls and intercellular bridges

D. Myocytes with prominent atypia

E. Spindle cells expressing CD117

Submit

1 2 3 4 5 6 7 8 9 10 11 12 13 14 15 16 17 18 19 20 21 22 23 24 25 26 27 28 29 30

A 65-year-old man comes to the office with dysphagia. For the last 3 months, he has relied on protein shakes and juices for nourishment as he has had difficulty swallowing solid foods. He has also had a diminished appetite and an estimated weight loss of 9.1 kg (20 lb). Medical history includes hyperlipidemia, emphysema, and previous episodes of pancreatitis. Family history includes lung cancer in his mother. The patient smoked a pack of cigarettes daily for 50 years but quit 2 years ago. He has been drinking a fifth (750 mL) of vodka weekly for the last decade. Vital signs are normal. BMI is 19.2 kg/m^2. Temporal wasting is present but physical examination is otherwise unremarkable. Upper endoscopy reveals a 4-cm mass in the middle third of the esophagus, and several biopsies are taken. Thoracic imaging reveals mediastinal lymphadenopathy. Histologic evaluation of the biopsy specimens will most likely show which of the following in this patient?

A. Intestinal cells without dysplasia (1%)

B. Irregular glandular cells with tissue invasion (14%)

✓ C. Keratin pearls and intercellular bridges (81%)

D. Myocytes with prominent atypia (1%)

E. Spindle cells expressing CD117 (1%)

Omitted
Correct answer
C

81%
Answered correctly

01 sec
Time Spent

01/24/2020
Last Updated

Explanation

Squamous cell carcinoma of the esophagus	

Explanation

Squamous cell carcinoma of the esophagus	
Risk factors	• Alcohol, smoking, foods containing N-nitroso • Age >50
Location	• Proximal two-thirds of esophagus (most common in the middle third) • Associated mediastinal lymphadenopathy
Histopathology	• Sheets of eosinophilic squamous cells • Keratin pearls, intercellular bridges

This patient with a mid-esophageal mass and mediastinal lymphadenopathy likely **has squamous cell carcinoma** (SCC) of the esophagus. SCC is characterized by sheets of pleomorphic squamous cells with abundant eosinophilic cytoplasm and large, bizarre nuclei with atypical mitosis; keratin formation (keratin pearls) and intercellular bridges are common. Malignant cells are often seen invading the submucosa and surrounding structures.

The esophagus can be subdivided (based on anatomy and embryonic formation) into thirds; malignancies occur at different frequencies within each segment.

- Proximal and middle third: SCC is more common, and occurs at the highest frequency in the **middle third**. Lymphatics drain to mediastinal nodes; metastatic disease may present with mediastinal lymphadenopathy.
- Distal third: Adenocarcinoma is more common. Lymphatics drain caudally to the gastric and celiac nodes; metastatic disease may present with abdominal lymphadenopathy.

Adenocarcinoma is characterized by invasive patches of dysplastic, mucin-producing cells that form glands. It typically occurs as a consequence of chronic gastroesophageal reflux disease and is preceded by Barrett esophagus (replacement of the normal esophagus with nondysplastic columnar intestinal cells) **(Choices A and B)**.

1 2 3 4 5 6 7 8 9 10 11 12 13 14 15 16 17 18 19 20 21 22 23 24 25 26 27 28 29 30

	• Keratin pearls, intercellular bridges

This patient with a mid-esophageal mass and mediastinal lymphadenopathy likely **has squamous cell carcinoma** (SCC) of the esophagus. SCC is characterized by sheets of pleomorphic squamous cells with abundant eosinophilic cytoplasm and large, bizarre nuclei with atypical mitosis; keratin formation (keratin pearls) and intercellular bridges are common. Malignant cells are often seen invading the submucosa and surrounding structures.

The esophagus can be subdivided (based on anatomy and embryonic formation) into thirds; malignancies occur at different frequencies within each segment.

- Proximal and middle third: SCC is more common, and occurs at the highest frequency in the **middle third**. Lymphatics drain to mediastinal nodes; metastatic disease may present with mediastinal lymphadenopathy.
- Distal third: Adenocarcinoma is more common. Lymphatics drain caudally to the gastric and celiac nodes; metastatic disease may present with abdominal lymphadenopathy.

Adenocarcinoma is characterized by invasive patches of dysplastic, mucin-producing cells that form glands. It typically occurs as a consequence of chronic gastroesophageal reflux disease and is preceded by Barrett esophagus (replacement of the normal esophagus with nondysplastic columnar intestinal cells) **(Choices A and B)**.

(Choices D and E) Leiomyosarcoma demonstrates myocyte atypia on histology. Gastrointestinal stromal tumors are often composed of spindle cells (eosinophilic cells arranged in fascicles) that overexpress CD117. These malignancies occur more commonly in the stomach and small intestine and are rare in the esophagus.

Educational objective:
Esophageal squamous cell carcinoma presents mostly in the proximal two-thirds of the esophagus and frequently metastasizes to the mediastinal lymph nodes. Histology characteristically shows sheets of pleomorphic squamous cells with keratin pearls and intercellular bridges.

Pathology	Gastrointestinal & Nutrition	Esophageal cancer
Subject	System	Topic

Copyright © UWorld. All rights reserved.

Settings

Item 20 of 38
Question Id: 14878

Mark | Previous | Next | Full Screen | Tutorial | Lab Values | Notes | Calculator | Reverse Color | Text Zoom | Settings

- Keratin pearls, intercellular bridges

Exhibit Display

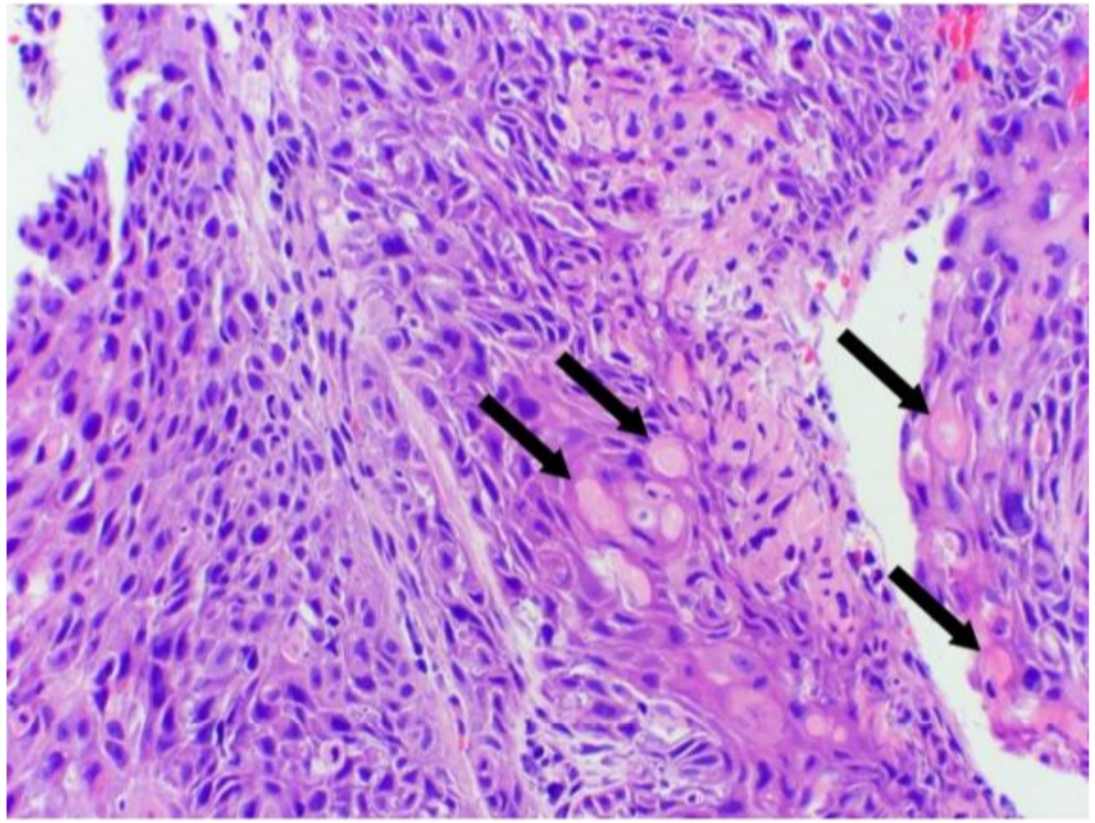

Zoom In | Zoom Out | Reset | Add To New Card | Existing Card

Block Time Remaining: 00:00:40
TUTOR

9 | Feedback | Suspend | End Block

Settings

1
2
3
4
5
6
7
8
9
10
11
12
13
14
15
16
17
18
19
20
21
22
23
24
25
26
27
28
29
30

Item 20 of 38
Question Id: 14878

Mark

Settings

This patien
is characte
keratin forn
structures.

The esopha
each segm

- Proxi
node
- Dista
with

Adenocarci
of chronic g
columnar in

(Choices D
cells (eosin
intestine an

Education
Esophagea
lymph node

Pathology
Subject

System

Topic

Exhibit Display

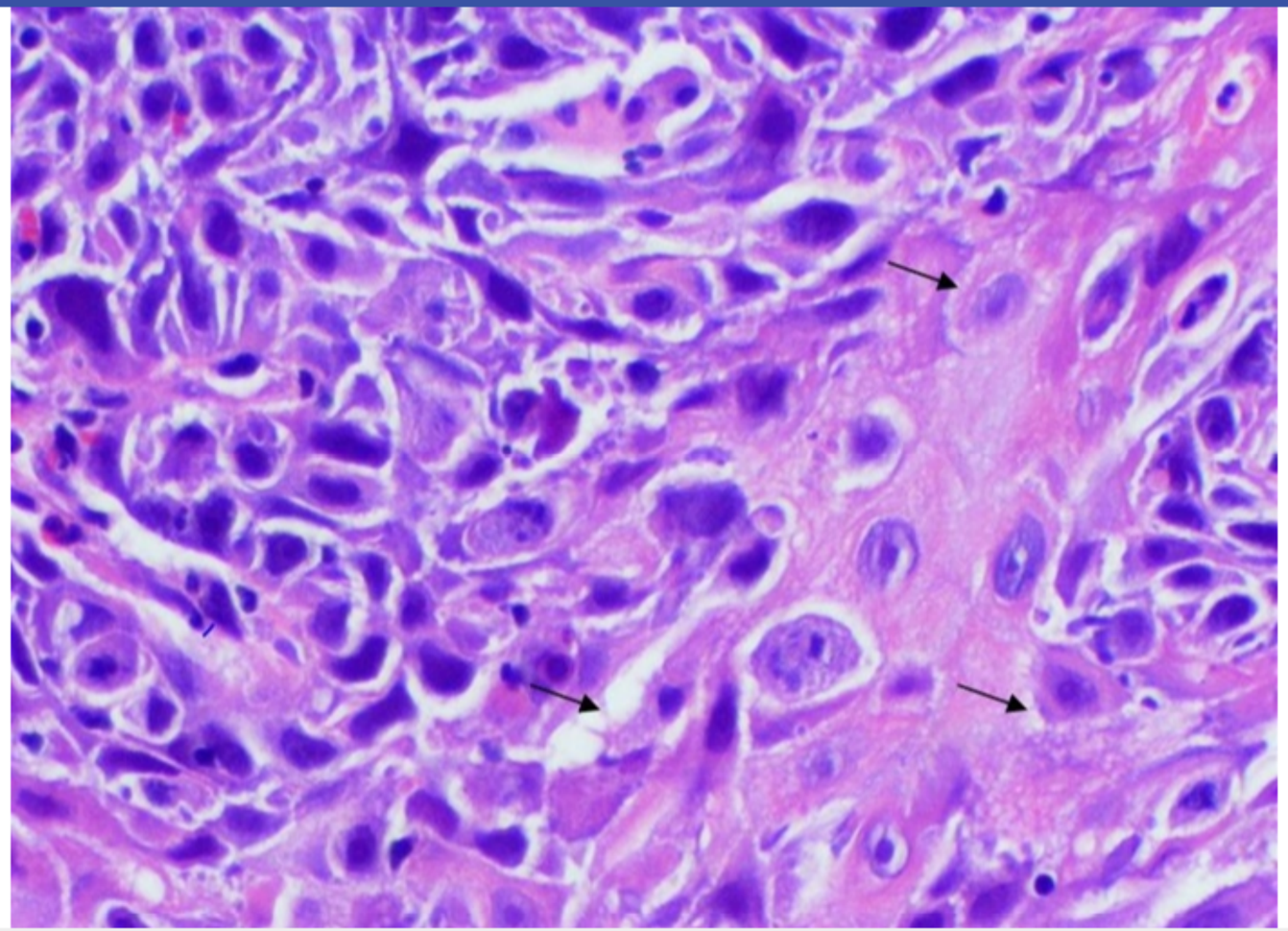

Zoom In | Zoom Out | Reset | Add To New Card | Existing Card

Block Time Remaining: 00:00:40
TUTOR

9

Feedback

Suspend

End Block

Settings

1 2 3 4 5 6 7 8 9 10 11 12 13 14 15 16 17 18 19 20 21 22 23 24 25 26 27 28 29 30

Item 20 of 38
Question Id: 14878

Mark | Previous | Next | Full Screen | Tutorial | Lab Values | Notes | Calculator | Reverse Color | Text Zoom | Settings

This patient with a mid-esophageal mass and mediastinal lymphadenopathy likely **has squamous cell carcinoma** (SCC) of the esophagus. SCC

Exhibit Display

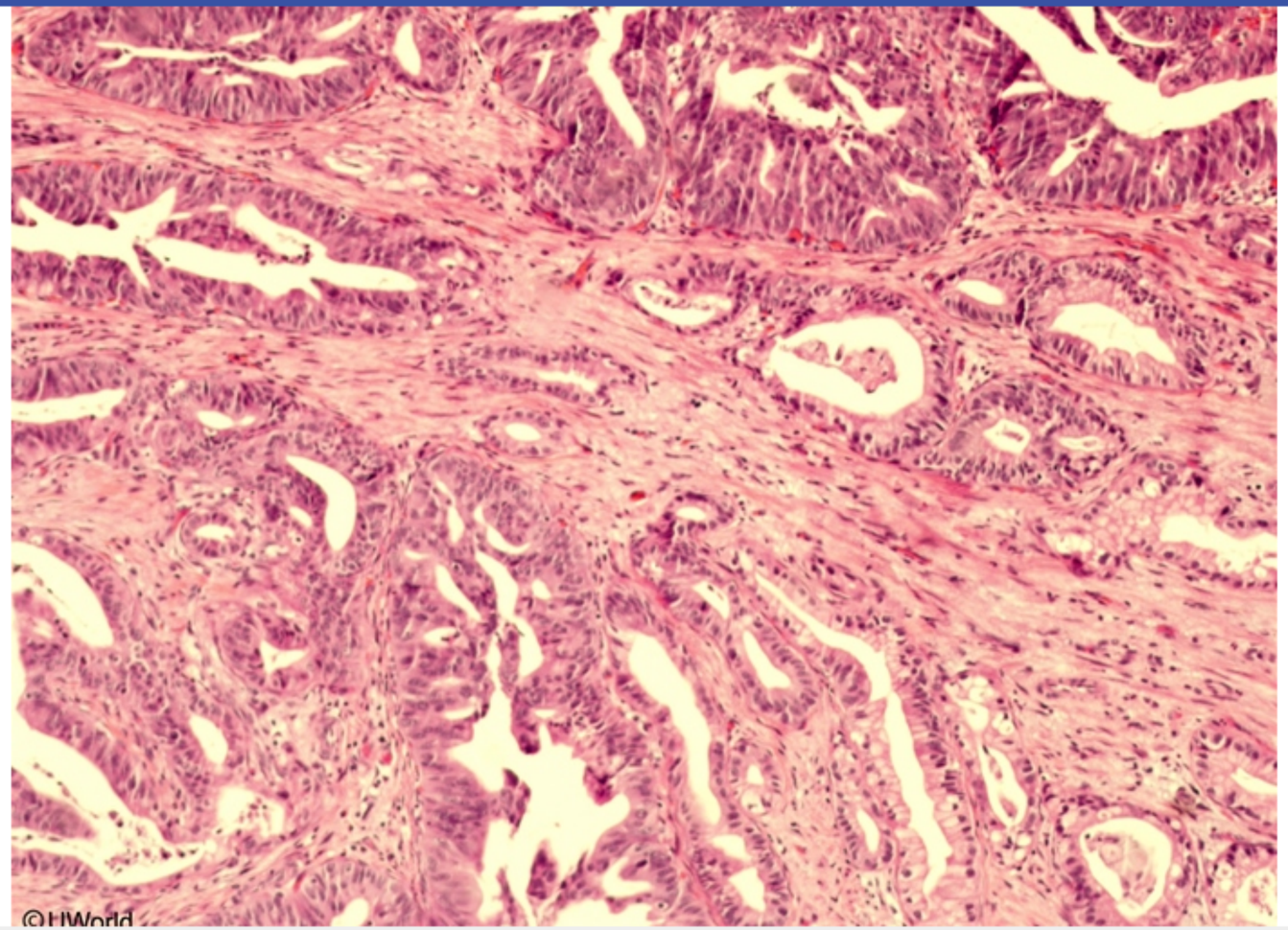

Zoom In | Zoom Out | Reset | Add To New Card | Existing Card

Block Time Remaining: 00:00:40
TUTOR

9 | Feedback | Suspend | End Block

Settings

1 2 3 4 5 6 7 8 9 10 11 12 13 14 15 16 17 18 19 20 21 22 23 24 25 26 27 28 29 30

Item 20 of 38
Question Id: 14878

Mark | Previous | Next | Full Screen | Tutorial | Lab Values | Notes | Calculator | Reverse Color | Text Zoom | Settings

This patient with a mid-esophageal mass and mediastinal lymphadenopathy likely **has squamous cell carcinoma** (SCC) of the esophagus. SCC

Exhibit Display

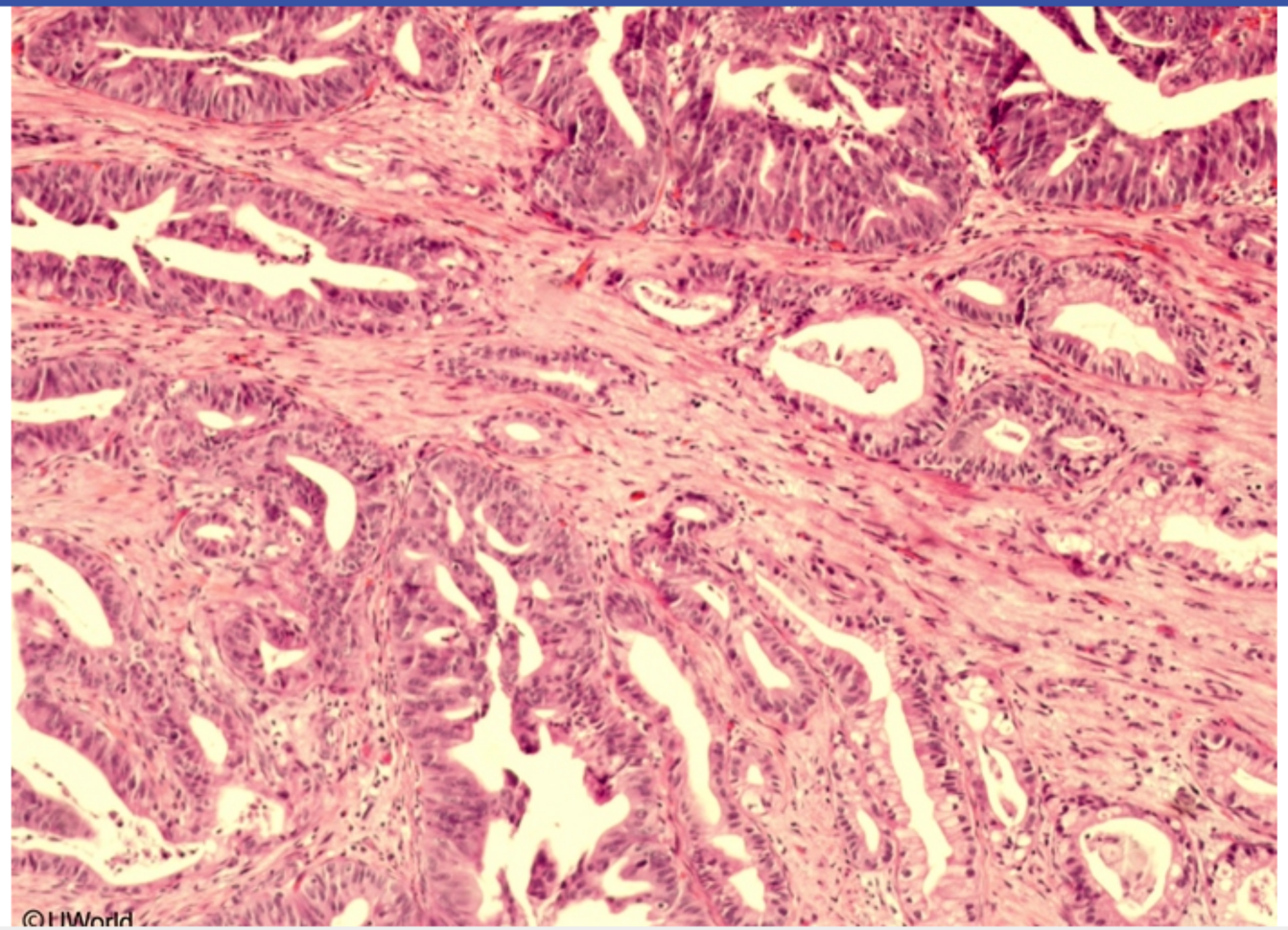

Zoom In | Zoom Out | Reset | Add To New Card | Existing Card

Block Time Remaining: 00:00:40
TUTOR

9 | Feedback | Suspend | End Block

Settings

1 2 3 4 5 6 7 8 9 10 11 12 13 14 15 16 17 18 19 20 21 22 23 24 25 26 27 28 29 30

Item 20 of 38
Question Id: 14878

Mark | Previous | Next | Full Screen | Tutorial | Lab Values | Notes | Calculator | Reverse Color | Text Zoom | Settings

This patient with a mid-esophageal mass and mediastinal lymphadenopathy likely **has squamous cell carcinoma** (SCC) of the esophagus. SCC

Exhibit Display

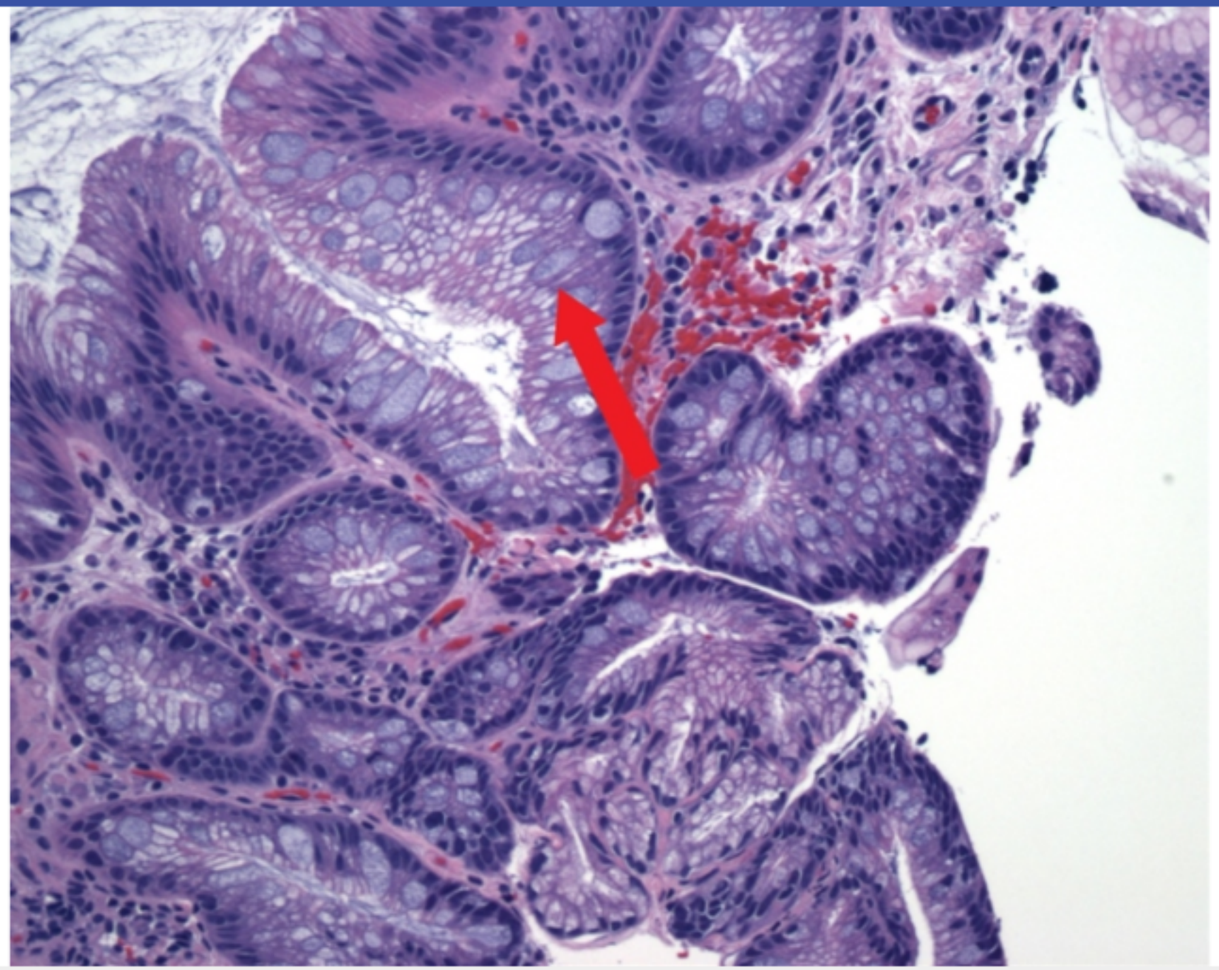

Zoom In | Zoom Out | Reset | Add To New Card | Existing Card

Block Time Remaining: 00:00:40
TUTOR

9 | Feedback | Suspend | End Block

Settings

1 2 3 4 5 6 7 8 9 10 11 12 13 14 15 16 17 18 19 20 21 22 23 24 25 26 27 28 29 30

Item 20 of 38
Question Id: 14878

Mark | Previous | Next | Full Screen | Tutorial | Lab Values | Notes | Calculator | Reverse Color | Text Zoom | Settings

This patient with a mid-esophageal mass and mediastinal lymphadenopathy likely **has squamous cell carcinoma** (SCC) of the esophagus. SCC

Exhibit Display

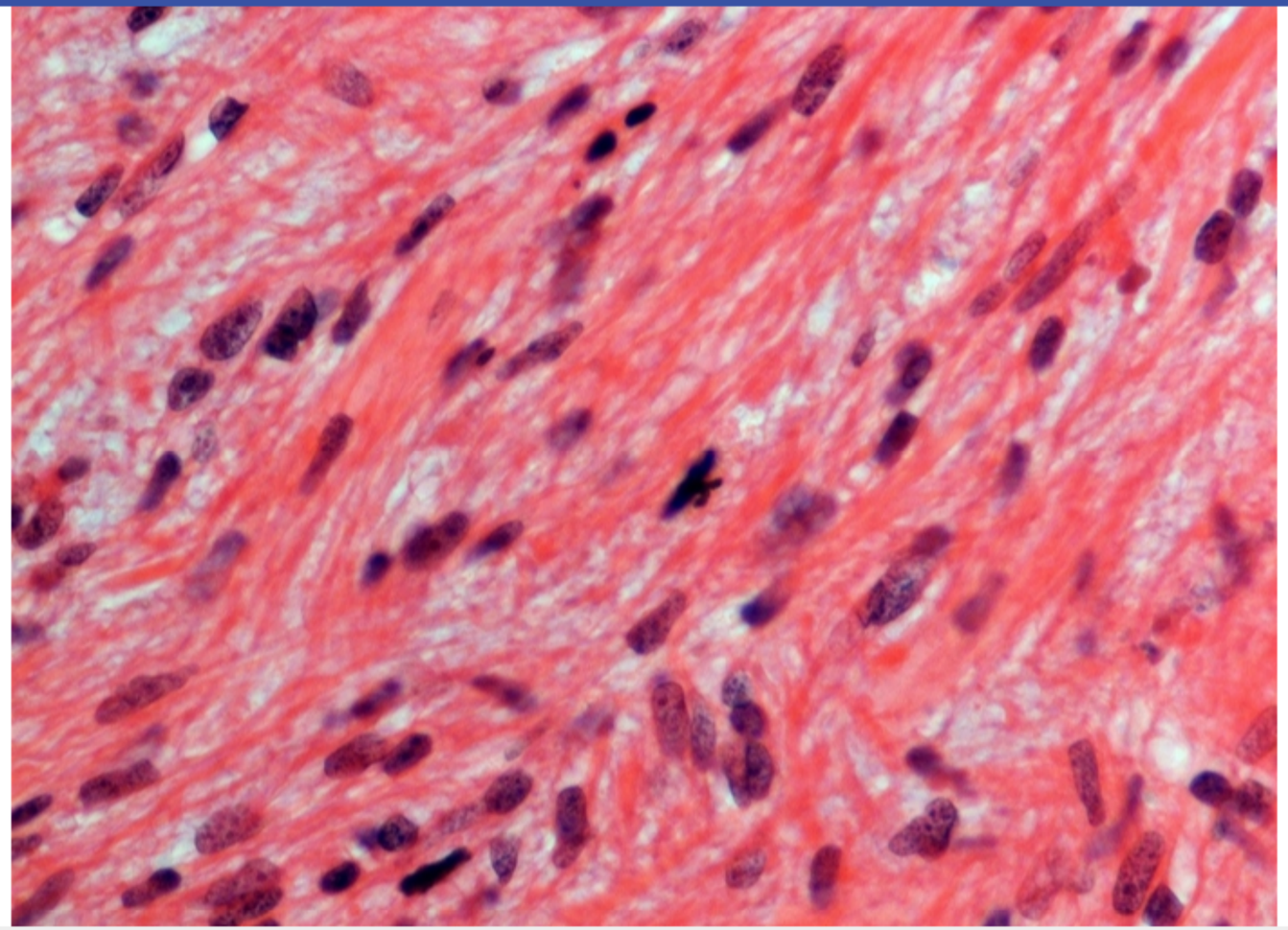

Zoom In | Zoom Out | Reset | Add To New Card | Existing Card

Block Time Remaining: 00:00:40
TUTOR

9 | Feedback | Suspend | End Block

Settings

1 2 3 4 5 6 7 8 9 10 11 12 13 14 15 16 17 18 19 20 21 22 23 24 25 26 27 28 29 30

Item 20 of 38
Question Id: 14878

Mark | Previous | Next | Full Screen | Tutorial | Lab Values | Notes | Calculator | Reverse Color | Text Zoom | Settings

This patient with a mid-esophageal mass and mediastinal lymphadenopathy likely **has squamous cell carcinoma** (SCC) of the esophagus. SCC

Exhibit Display

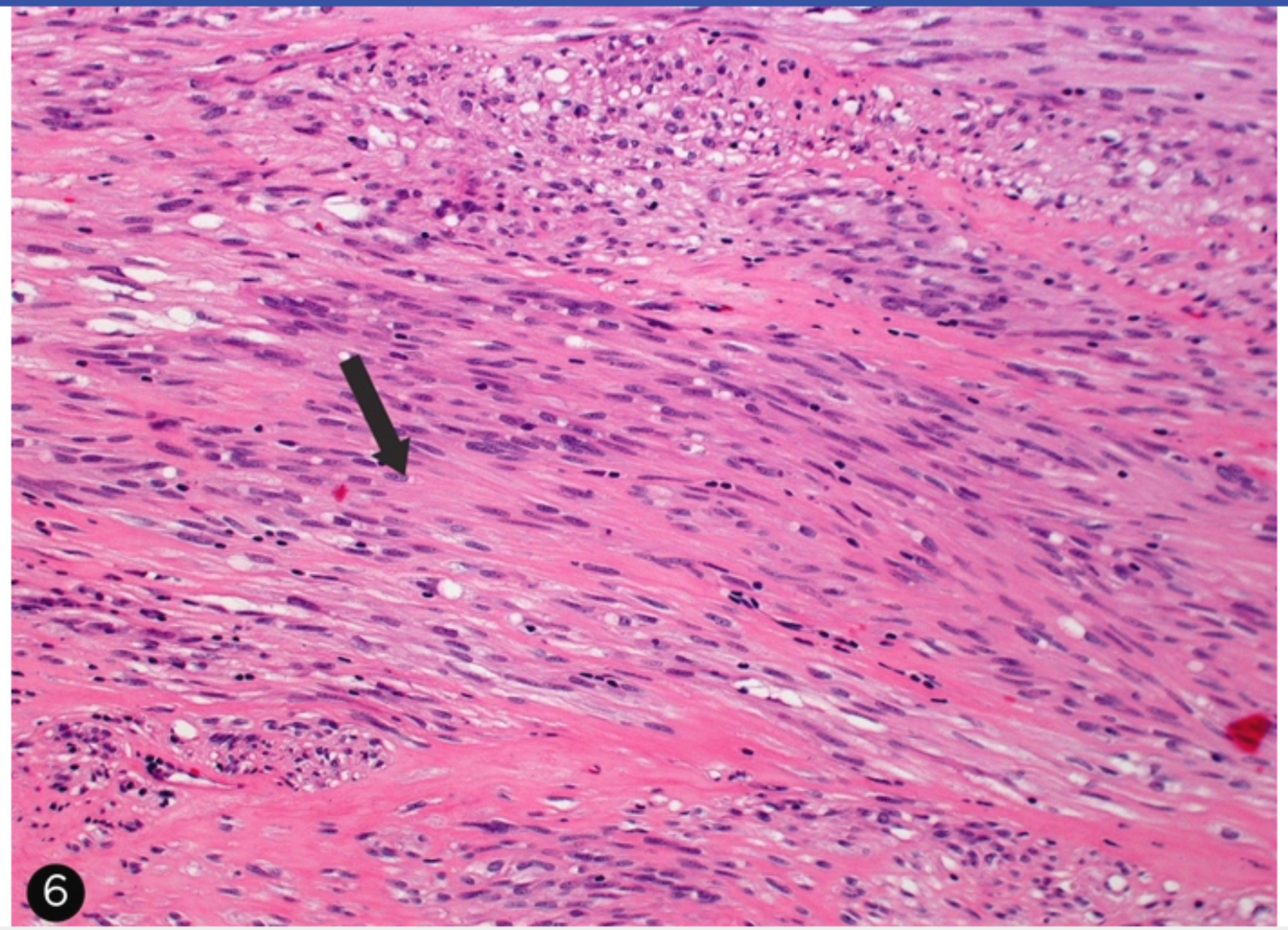

Zoom In | Zoom Out | Reset | Add To New Card | Existing Card

Block Time Remaining: 00:00:40
TUTOR

9 | Feedback | Suspend | End Block

1 2 3 4 5 6 7 8 9 10 11 12 13 14 15 16 17 18 19 20 21 22 23 24 25 26 27 28 29 30

A 65-year-old man is referred to a gastroenterology clinic by his primary care provider after he develops symptoms suspicious for colorectal cancer. The patient has a history of obesity, diabetes mellitus, and chronic obstructive pulmonary disease. He often eats steaks and hamburgers but avoids vegetables as "they have no flavor." The patient has smoked a pack of cigarettes daily for the past 40 years and occasionally consumes alcohol. He undergoes a colonoscopy and is found to have a mass lesion in the ascending colon. The mass is biopsied, and the histopathologic findings are consistent with colon adenocarcinoma. This patient most likely initially presented with which of the following clinical symptoms?

- A. Abdominal pain, distension, and nausea
- B. Constipation alternating with diarrhea
- C. Recurrent grossly bloody stool and low-grade fever
- D. Tenesmus and small-caliber stool
- E. Weight loss and progressive fatigue

Submit

1 2 3 4 5 6 7 8 9 10 11 12 13 14 15 16 17 18 19 20 21 22 23 24 25 26 27 28 29 30

A 65-year-old man is referred to a gastroenterology clinic by his primary care provider after he develops symptoms suspicious for colorectal cancer. The patient has a history of obesity, diabetes mellitus, and chronic obstructive pulmonary disease. He often eats steaks and hamburgers but avoids vegetables as "they have no flavor." The patient has smoked a pack of cigarettes daily for the past 40 years and occasionally consumes alcohol. He undergoes a colonoscopy and is found to have a mass lesion in the ascending colon. The mass is biopsied, and the histopathologic findings are consistent with colon adenocarcinoma. This patient most likely initially presented with which of the following clinical symptoms?

- A. Abdominal pain, distension, and nausea (6%)
- B. Constipation alternating with diarrhea (8%)
- C. Recurrent grossly bloody stool and low-grade fever (19%)
- D. Tenesmus and small-caliber stool (7%)
- ✓ E. Weight loss and progressive fatigue (58%)

Omitted
Correct answer
E

58%
Answered correctly

02 secs
Time Spent

03/02/2020
Last Updated

Explanation

The location of colon adenocarcinoma can influence its clinical manifestations. **Right-sided colon cancers** usually grow as exophytic masses. Patients generally do not develop intestinal obstruction because the ascending colon has a larger caliber lumen than the descending colon and stool in the proximal colon is more liquid. Right-sided colon cancers typically present with features of **iron deficiency anemia** (eg, fatigue, pallor) due to occult blood loss. Nonspecific symptoms such as anorexia, malaise, and unintentional weight loss may also occur.

1 2 3 4 5 6 7 8 9 10 11 12 13 14 15 16 17 18 19 20 21 22 23 24 25 26 27 28 29 30

The location of colon adenocarcinoma can influence its clinical manifestations. **Right-sided colon cancers** usually grow as exophytic masses. Patients generally do not develop intestinal obstruction because the ascending colon has a larger caliber lumen than the descending colon and stool in the proximal colon is more liquid. Right-sided colon cancers typically present with features of **iron deficiency anemia** (eg, fatigue, pallor) due to occult blood loss. Nonspecific symptoms such as anorexia, malaise, and unintentional weight loss may also occur.

Environmental and lifestyle factors that may have increased this patient's risk of colon cancer include obesity, cigarette smoking, consumption of red/processed meat, and low dietary intake of vegetables.

(Choice A) Left-sided colon cancers tend to infiltrate the intestinal wall and encircle the lumen, causing a change in bowel habits (eg, constipation) and symptoms of intestinal obstruction (eg, abdominal pain, distension, nausea/vomiting).

(Choice B) Constipation that alternates with diarrhea is characteristic of irritable bowel syndrome.

(Choice C) Recurrent grossly bloody stool associated with abdominal discomfort and low-grade fever is characteristic of ulcerative colitis, which is a risk factor for colon cancer. Rectosigmoid cancer often causes hematochezia, but fever is uncommon.

(Choice D) Tenesmus (ineffectual/painful straining on defecation) and small-caliber stool are characteristic of rectal adenocarcinoma.

Educational objective:
Right-sided colon cancers usually grow as exophytic masses and present with occult bleeding and symptoms of iron deficiency anemia. Left-sided colon cancers tend to infiltrate the intestinal wall and encircle the lumen, causing constipation and symptoms of intestinal obstruction. Rectosigmoid involvement often causes hematochezia.

References

- Left and right sided large bowel cancer.
- Correlation of clinical data, anatomical site and disease stage in colorectal cancer.
- How does colorectal cancer present? Symptoms, duration, and clues to location.

Pathology | Gastrointestinal & Nutrition | Colorectal cancer

1 2 3 4 5 6 7 8 9 10 11 12 13 14 15 16 17 18 19 20 21 22 23 24 25 26 27 28 29 30

A 65-year-old man comes to the emergency department due to abdominal pain and diarrhea. Three weeks ago, he drove from Texas to Mexico for a family vacation. Temperature is 38.3 C (101 F), blood pressure is 115/70 mm Hg, and pulse is 98/min. Abdominal examination shows mild, generalized tenderness with no rebound tenderness or guarding. Leukocyte count is 14,000/mm^3. Sigmoidoscopy demonstrates white-yellow plaques on the colonic mucosa, and biopsy shows that the plaques are composed of fibrin and inflammatory cells. Further questioning regarding this patient's trip to Mexico is most likely to reveal which of the following events?

A. He consumed shellfish from the hotel buffet

B. He drank unpurified tap water on several occasions

C. He had undercooked pork at a resort barbecue

D. He required hospitalization and antibiotics for pneumonia

E. He took home-canned foods to consume during the trip

Submit

A 65-year-old man comes to the emergency department due to abdominal pain and diarrhea. Three weeks ago, he drove from Texas to Mexico for a family vacation. Temperature is 38.3 C (101 F), blood pressure is 115/70 mm Hg, and pulse is 98/min. Abdominal examination shows mild, generalized tenderness with no rebound tenderness or guarding. Leukocyte count is 14,000/mm^3. Sigmoidoscopy demonstrates white-yellow plaques on the colonic mucosa, and biopsy shows that the plaques are composed of fibrin and inflammatory cells. Further questioning regarding this patient's trip to Mexico is most likely to reveal which of the following events?

- A. He consumed shellfish from the hotel buffet (4%)
- B. He drank unpurified tap water on several occasions (14%)
- C. He had undercooked pork at a resort barbecue (6%)
- ✓ D. He required hospitalization and antibiotics for pneumonia (74%)
- E. He took home-canned foods to consume during the trip (1%)

Omitted
Correct answer
D

74%
Answered correctly

02 secs
Time Spent

02/23/2020
Last Updated

Explanation

Clostridium difficile colitis	
Risk factors	• Recent antibiotics • Hospitalization

***Clostridium difficile* colitis**	
Risk factors	• Recent antibiotics • Hospitalization • PPI
Pathogenesis	• Disruption of intestinal flora → *C difficile* overgrowth • Exotoxins cause mucosal injury • Pseudomembrane formation
Clinical presentation	• Profuse diarrhea (most common) • Fulminant colitis/toxic megacolon
Diagnosis	• PCR for toxin-encoding gene • EIA for bacterial toxin or glutamate dehydrogenase
Treatment	• Oral vancomycin or fidaxomicin

EIA = enzyme immunoassay; **PCR** = polymerase chain reaction; **PPI** = proton pump inhibitor.

This patient has abdominal pain, diarrhea, and leukocytosis. The formation of pseudomembranes (white-yellow plaques composed of fibrin, inflammatory cells, and cellular debris) on the colonic mucosa is highly consistent with pseudomembranous colitis due to ***Clostridium difficile***, a spore-forming bacillus that colonizes up to 50% of hospitalized adults. **Antibiotic therapy** (eg, fluoroquinolones for bacterial pneumonia) **increases the risk** of *C difficile* infection as it kills intestinal microbes that normally keep potential pathogens in check. *C difficile* can proliferate in the altered microbiome, leading to overgrowth and clinical disease.

C difficile produces 2 toxins—toxin A (enterotoxin) and toxin B (cytotoxin)—which penetrate colonic epithelial cells and damage cellular

This patient has abdominal pain, diarrhea, and leukocytosis. The formation of pseudomembranes (white-yellow plaques composed of fibrin, inflammatory cells, and cellular debris) on the colonic mucosa is highly consistent with pseudomembranous colitis due to ***Clostridium difficile***, a spore-forming bacillus that colonizes up to 50% of hospitalized adults. **Antibiotic therapy** (eg, fluoroquinolones for bacterial pneumonia) **increases the risk** of *C difficile* infection as it kills intestinal microbes that normally keep potential pathogens in check. *C difficile* can proliferate in the altered microbiome, leading to overgrowth and clinical disease.

C difficile produces 2 toxins—toxin A (enterotoxin) and toxin B (cytotoxin)—which penetrate colonic epithelial cells and damage cellular cytoskeletons and intercellular tight junctions. This results in widespread inflammation, edema, necrosis, and fibrin deposition. Clinical manifestations range from watery diarrhea and mild abdominal cramping to fulminant colitis with nonobstructive colonic enlargement (megacolon) and intestinal perforation.

(Choices A and B) Ingestion of undercooked shellfish is associated with *Vibrio*, Norwalk virus, and hepatitis A infections. Traveler's diarrhea, caused by bacteria (eg, enterotoxigenic *Escherichia coli*, *Campylobacter*, *Salmonella*, *Shigella*) or parasites (eg, *Giardia*), is often due to contaminated water consumption. These conditions can manifest as diarrhea and abdominal pain; however, pseudomembranes are virtually pathognomonic for *C difficile* colitis.

(Choice C) Consumption of undercooked pork is a risk factor for intestinal tapeworm (taeniasis), which occurs after ingestion of *Taenia solium*. Patients are often asymptomatic but may have nausea or abdominal pain.

(Choice E) Adult botulism occurs after ingestion of preformed toxin in home-canned food. This neurotoxin inhibits acetylcholine release from the nerve terminals at neuromuscular junctions and causes a descending flaccid paralysis.

Educational objective:
Antibiotics disrupt the normal intestinal flora and which can allow for overgrowth of *Clostridium difficile*, an anaerobic, gram-positive, spore-forming bacillus. *C difficile* produces 2 toxins that penetrate colonic epithelial cells leading to watery diarrhea, abdominal cramping, and colitis. The presence of a pseudomembrane (exudate on colonic mucosa consisting of fibrin and inflammatory cells) is highly suggestive of *C difficile* infection.

Pathology	Gastrointestinal & Nutrition	Clostridium difficile infection
Subject	System	Topic

Settings

1 2 3 4 5 6 7 8 9 10 11 12 13 14 15 16 17 18 19 20 21 22 23 24 25 26 27 28 29 30

Item 22 of 38
Question Id: 1396

Mark | Previous | Next | Full Screen | Tutorial | Lab Values | Notes | Calculator | Reverse Color | Text Zoom | Settings

Exhibit Display

Pseudomembranous colitis

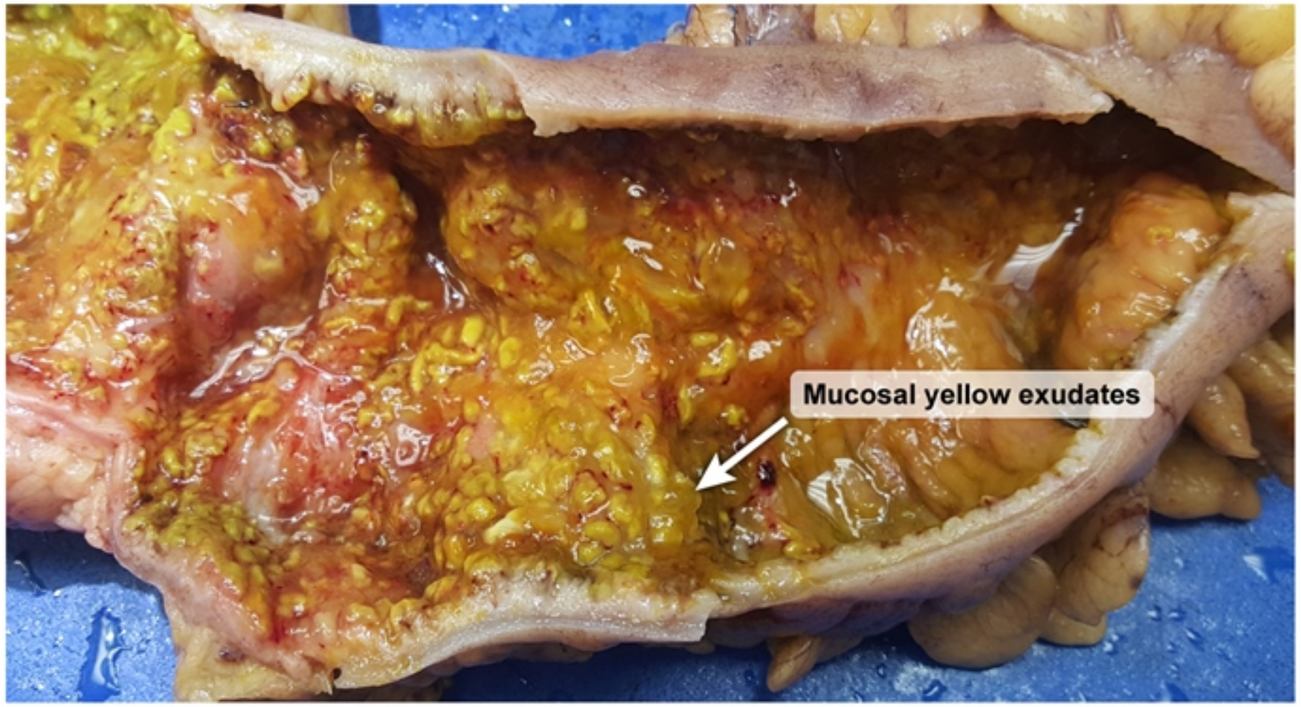

©UWorld

Zoom In | Zoom Out | Reset | Add To New Card | Existing Card

Block Time Remaining: 00:00:44
TUTOR

3 | Feedback | Suspend | End Block

spore-forming bacillus that colonizes up to 50% of hospitalized adults. **Antibiotic therapy** (eg, fluoroquinolones for bacterial pneumonia) **increases the risk** of *C difficile* infection as it kills intestinal microbes that normally keep potential pathogens in check. *C difficile* can proliferate in the altered microbiome, leading to overgrowth and clinical disease.

C difficile produces 2 toxins—toxin A (enterotoxin) and toxin B (cytotoxin)—which penetrate colonic epithelial cells and damage cellular cytoskeletons and intercellular tight junctions. This results in widespread inflammation, edema, necrosis, and fibrin deposition. Clinical manifestations range from watery diarrhea and mild abdominal cramping to fulminant colitis with nonobstructive colonic enlargement (megacolon) and intestinal perforation.

(Choices A and B) Ingestion of undercooked shellfish is associated with *Vibrio*, Norwalk virus, and hepatitis A infections. Traveler's diarrhea, caused by bacteria (eg, enterotoxigenic *Escherichia coli*, *Campylobacter*, *Salmonella*, *Shigella*) or parasites (eg, *Giardia*), is often due to contaminated water consumption. These conditions can manifest as diarrhea and abdominal pain; however, pseudomembranes are virtually pathognomonic for *C difficile* colitis.

(Choice C) Consumption of undercooked pork is a risk factor for intestinal tapeworm (taeniasis), which occurs after ingestion of *Taenia solium*. Patients are often asymptomatic but may have nausea or abdominal pain.

(Choice E) Adult botulism occurs after ingestion of preformed toxin in home-canned food. This neurotoxin inhibits acetylcholine release from the nerve terminals at neuromuscular junctions and causes a descending flaccid paralysis.

Educational objective:
Antibiotics disrupt the normal intestinal flora and which can allow for overgrowth of *Clostridium difficile*, an anaerobic, gram-positive, spore-forming bacillus. *C difficile* produces 2 toxins that penetrate colonic epithelial cells leading to watery diarrhea, abdominal cramping, and colitis. The presence of a pseudomembrane (exudate on colonic mucosa consisting of fibrin and inflammatory cells) is highly suggestive of *C difficile* infection.

Pathology	Gastrointestinal & Nutrition	Clostridium difficile infection
Subject	System	Topic

Copyright © UWorld. All rights reserved.

1 2 3 4 5 6 7 8 9 10 11 12 13 14 15 16 17 18 19 20 21 22 23 24 25 26 27 28 29 30

A 26-year-old woman is evaluated for intermittent abdominal pain occurring over the last several years. The pain is crampy without radiation and graded 6/10 in intensity. She also has fluctuating diarrhea but has not seen blood in the stool. The patient has no nausea, vomiting, constipation, urinary frequency, dysuria, or vaginal symptoms. Her last menstrual period was 2 weeks ago. She does not use tobacco or alcohol. Temperature is 37.2 C (99 F), blood pressure is 115/70 mm Hg, and pulse is 90/min. On examination, the abdomen is tender without guarding or rebound. There is a draining fistula near her coccyx. Which of the following is the most likely diagnosis in this patient?

A. Crohn disease

B. Diverticulitis

C. Intergluteal pilonidal disease

D. Irritable bowel syndrome

E. Ulcerative colitis

Submit

A 26-year-old woman is evaluated for intermittent abdominal pain occurring over the last several years. The pain is crampy without radiation and graded 6/10 in intensity. She also has fluctuating diarrhea but has not seen blood in the stool. The patient has no nausea, vomiting, constipation, urinary frequency, dysuria, or vaginal symptoms. Her last menstrual period was 2 weeks ago. She does not use tobacco or alcohol. Temperature is 37.2 C (99 F), blood pressure is 115/70 mm Hg, and pulse is 90/min. On examination, the abdomen is tender without guarding or rebound. There is a draining fistula near her coccyx. Which of the following is the most likely diagnosis in this patient?

- ✓ A. Crohn disease (78%)
- B. Diverticulitis (4%)
- C. Intergluteal pilonidal disease (5%)
- D. Irritable bowel syndrome (6%)
- E. Ulcerative colitis (4%)

Omitted
Correct answer
A

78%
Answered correctly

01 sec
Time Spent

05/30/2020
Last Updated

Explanation

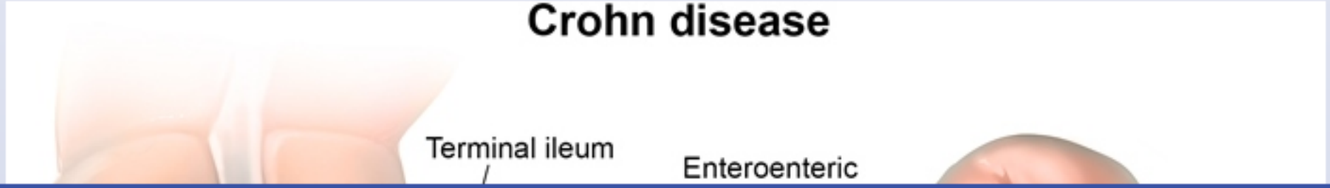

1 2 3 4 5 6 7 8 9 10 11 12 13 14 15 16 17 18 19 20 21 22 23 24 25 26 27 28 29 30

Crohn disease

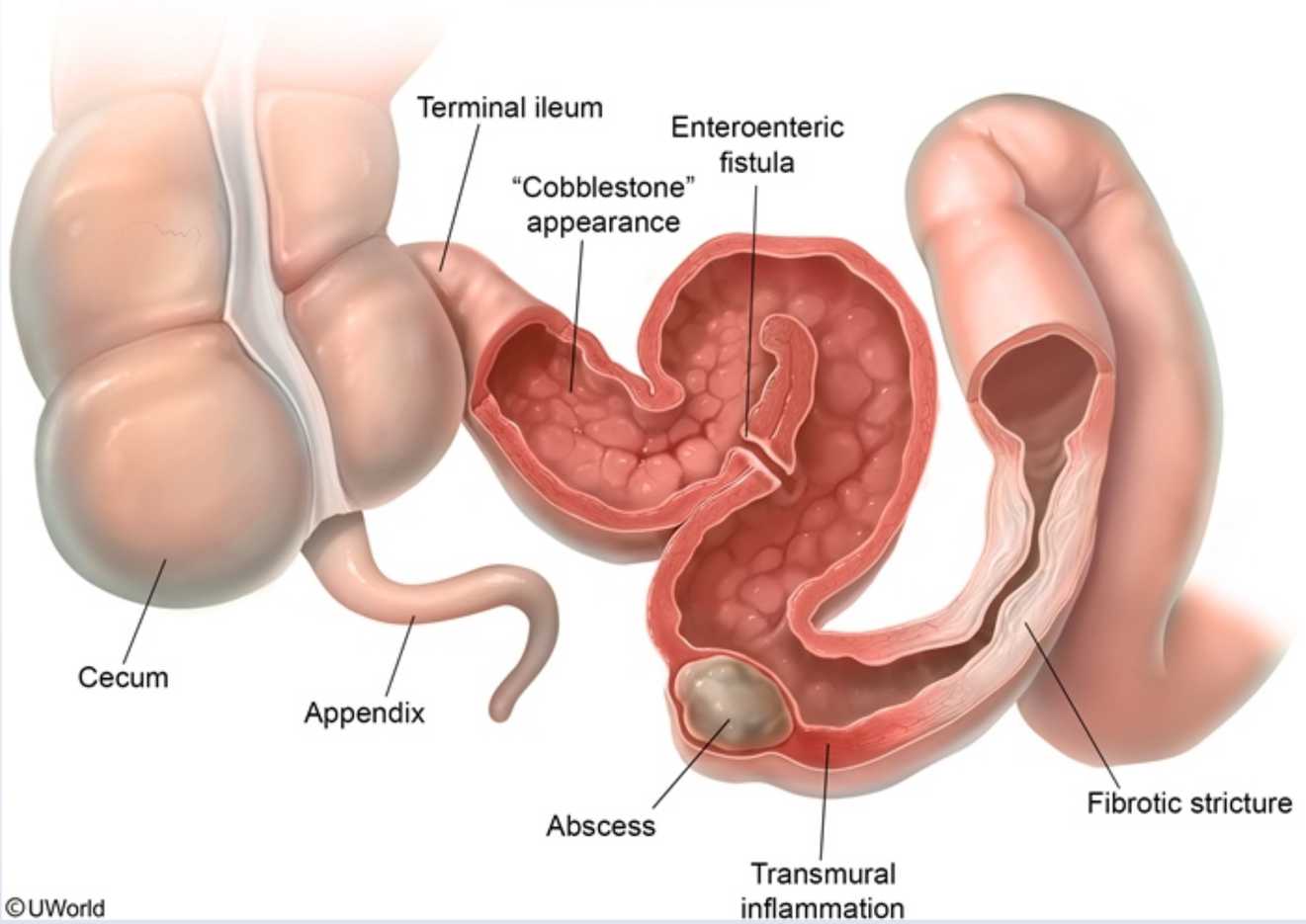

This patient likely has **Crohn disease (CD)** complicated by a perianal fistula. CD can involve the gastrointestinal tract anywhere from the mouth to the anus but often spares the rectum. Patients typically present insidiously (over the course of years) with bouts of crampy abdominal pain, diarrhea, and constitutional symptoms (eg, fatigue, weight loss, fever). Fecal occult blood testing is often positive; however, grossly bloody stool is less commonly seen unless the colon is involved.

This patient likely has **Crohn disease (CD)** complicated by a perianal fistula. CD can involve the gastrointestinal tract anywhere from the mouth to the anus but often spares the rectum. Patients typically present insidiously (over the course of years) with bouts of crampy abdominal pain, diarrhea, and constitutional symptoms (eg, fatigue, weight loss, fever). Fecal occult blood testing is often positive; however, grossly bloody stool is less commonly seen unless the colon is involved.

Patients are prone to developing fistulas and abscesses due to the **transmural** inflammation that occurs in CD. **Fistulas** are abnormal connections between 2 epithelial-lined organs. They are usually formed between the bowel and nearby structures that include the skin (enterocutaneous), urinary bladder (enterovesical), vagina (enterovaginal), or bowel (enteroenteric). **Perianal disease** other than fistulas is also common and may include skin tags and fissures.

(Choice B) Diverticulitis is characterized by inflammation of saclike protrusions (diverticula) that typically form in the sigmoid colon of older patients. It can present with left lower quadrant abdominal pain, diarrhea or constipation, low-grade fever, and fistulas; however, this patient's young age makes the diagnosis less likely.

(Choice C) Intergluteal pilonidal disease is an acquired skin infection involving the upper natal cleft of the buttocks. Although patients may present with draining sinus tracts in the intergluteal region, abdominal pain/tenderness and diarrhea are not characteristic.

(Choice D) Irritable bowel syndrome (IBS) is characterized by chronic abdominal pain associated with altered bowel habits (eg, diarrhea and/or constipation). Pain is often relieved with bowel movements. IBS is not an inflammatory condition and does not cause fistulas.

(Choice E) Ulcerative colitis is an inflammatory disease of the colonic mucosa that almost always affects the rectum and often presents with grossly bloody stool. Fistulas are not commonly seen as inflammation does not involve the full thickness of the bowel wall.

Educational objective:
Crohn disease typically presents with the insidious onset of abdominal pain, diarrhea, and constitutional symptoms (eg, weight loss, fever). Patients are prone to developing fistulas/abscesses as the lesions affect the entire thickness of the bowel wall. Perianal disease (eg, skin tags, fissures) is also common.

References

- Diagnosis and management of Crohn's disease.

Settings

1
2
3
4
5
6
7
8
9
10
11
12
13
14
15
16
17
18
19
20
21
22
23
24
25
26
27
28
29
30

Item 23 of 38
Question Id: 1783

Mark | Previous | Next | Full Screen | Tutorial | Lab Values | Notes | Calculator | Reverse Color | Text Zoom | Settings

to the anus but often spares the rectum. Patients typically present insidiously (over the course of years) with bouts of cramp abdominal pain,

Exhibit Display

Zoom In | Zoom Out | Reset | Add To New Card | Existing Card

Block Time Remaining: 00:00:45
TUTOR

4 | Feedback | Suspend | End Block

1 2 3 4 5 6 7 8 9 10 11 12 13 14 15 16 17 18 19 20 21 22 23 24 25 26 27 28 29 30

A 32-year-old man comes to the clinic due to several months of fatigue and weight loss. The patient has no significant medical history. He drinks 1 or 2 alcoholic beverages daily and has used illicit intravenous drugs in the past. He is sexually active with his girlfriend. The patient has a maternal aunt with hypothyroidism, but his family history is otherwise unremarkable. Temperature is 36.7 C (98 F), blood pressure is 110/70 mm Hg, pulse is 65/min, and respirations are 18/min. Physical examination is normal. A liver biopsy is obtained, and light microscopy reveals large hepatocytes filled with finely granular, homogeneous, pale pink cytoplasm. Which of the following is the most likely diagnosis in this patient?

A. Alcoholic steatohepatitis

B. Hemochromatosis

C. Hepatitis B infection

D. Hepatitis C infection

E. Nonalcoholic steatohepatitis

Submit

A 32-year-old man comes to the clinic due to several months of fatigue and weight loss. The patient has no significant medical history. He drinks 1 or 2 alcoholic beverages daily and has used illicit intravenous drugs in the past. He is sexually active with his girlfriend. The patient has a maternal aunt with hypothyroidism, but his family history is otherwise unremarkable. Temperature is 36.7 C (98 F), blood pressure is 110/70 mm Hg, pulse is 65/min, and respirations are 18/min. Physical examination is normal. A liver biopsy is obtained, and light microscopy reveals large hepatocytes filled with finely granular, homogeneous, pale pink cytoplasm. Which of the following is the most likely diagnosis in this patient?

A. Alcoholic steatohepatitis (26%)

B. Hemochromatosis (4%)

✓ C. Hepatitis B infection (34%)

D. Hepatitis C infection (26%)

E. Nonalcoholic steatohepatitis (8%)

Omitted
Correct answer
C

34%
Answered correctly

02 secs
Time Spent

03/03/2020
Last Updated

Explanation

Hepatitis B infection, one of the most common causes of hepatic injury in the United States, is frequently transmitted sexually or via percutaneous inoculation (eg, intravenous drug use). A distinct histopathologic manifestation of **chronic** hepatitis B infection is the accumulation of hepatitis B **surface antigen** within infected hepatocytes. This results in the appearance of a finely granular, **diffusely homogeneous**, **pale eosinophilic** cytoplasm (**"ground-glass" hepatocytes**).

Explanation

Hepatitis B infection, one of the most common causes of hepatic injury in the United States, is frequently transmitted sexually or via percutaneous inoculation (eg, intravenous drug use). A distinct histopathologic manifestation of **chronic** hepatitis B infection is the accumulation of hepatitis B **surface antigen** within infected hepatocytes. This results in the appearance of a finely granular, **diffusely homogeneous**, **pale eosinophilic** cytoplasm (**"ground-glass" hepatocytes**).

Other nonspecific morphologic changes include hepatocyte necrosis (eg, ballooning degeneration), apoptosis, steatosis, and portal inflammation with mononuclear inclusions (lymphocytes, macrophages). Acidophil (Councilman) bodies, deeply eosinophilic globules that represent shrunken apoptotic hepatocytes, can be seen in a variety of liver diseases.

(Choices A and E) Hepatic steatosis is characterized by the accumulation of large and small vesicles of fat within hepatocytes. It is most commonly due to significant alcohol ingestion (>15 drinks/week for men, >10 drinks/week for women) but can also be due to obesity (nonalcoholic steatohepatitis). Mallory bodies may be seen in alcoholic steatohepatitis; they are characterized by **clumped**, amorphous, eosinophilic intracytoplasmic inclusions made up of tangled intermediate filaments.

(Choice B) Hemochromatosis is characterized by the deposition of iron in the liver, which appears as gold-yellow hemosiderin granules in the cytoplasm. Cirrhosis and portal hypertension result if the condition is left untreated.

(Choice D) A liver infected with hepatitis C virus commonly has lymphoid aggregates within the portal tracts and focal areas of macrovesicular steatosis; however, ground-glass hepatocytes are more specific for hepatitis B infection.

Educational objective:
Hepatitis B infection causes the hepatocellular cytoplasm to fill with hepatitis B surface antigen. These inclusions are highly specific for hepatitis B infection and have a finely granular, pale eosinophilic, ground-glass appearance.

References

- "Ground-glass" hepatocytes.
- Liver biopsy findings in chronic hepatitis B.

Settings

1 2 3 4 5 6 7 8 9 10 11 12 13 14 15 16 17 18 19 20 21 22 23 24 25 26 27 28 29 30

Item 24 of 38
Question Id: 367

Mark | Previous | Next | Full Screen | Tutorial | Lab Values | Notes | Calculator | Reverse Color | Text Zoom | Settings

Hepatitis B infection, one of the most common causes of hepatic injury in the United States, is frequently transmitted sexually or via

Exhibit Display

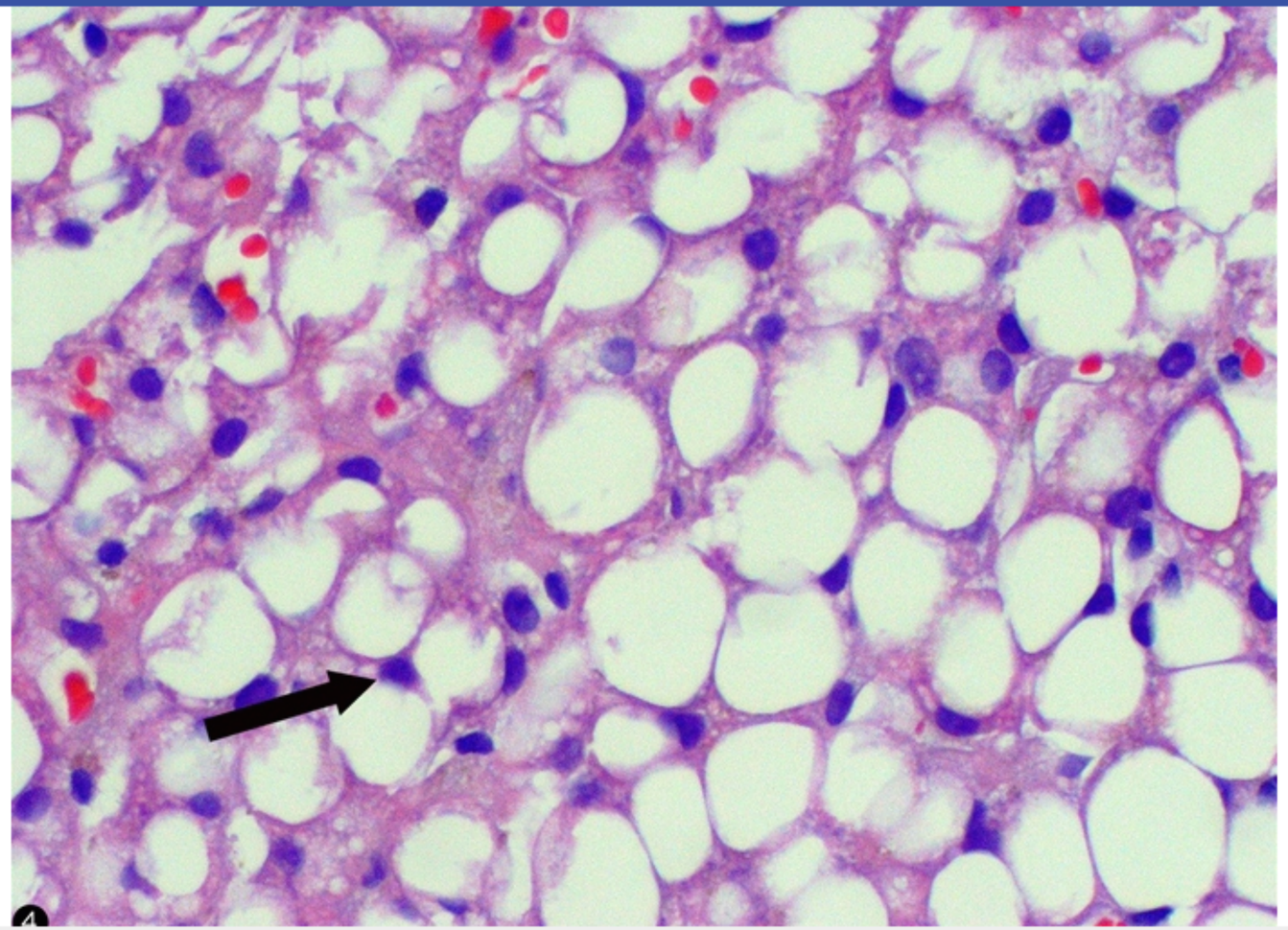

Zoom In | Zoom Out | Reset | Add To New Card | Existing Card

Subject System Topic

Block Time Remaining: 00:00:47
TUTOR

5 | Feedback | Suspend | End Block

Settings

1 2 3 4 5 6 7 8 9 10 11 12 13 14 15 16 17 18 19 20 21 22 23 24 25 26 27 28 29 30

Item 24 of 38
Question Id: 367

Mark | Previous | Next | Full Screen | Tutorial | Lab Values | Notes | Calculator | Reverse Color | Text Zoom | Settings

Hepatitis B infection, one of the most common causes of hepatic injury in the United States, is frequently transmitted sexually or via

Exhibit Display

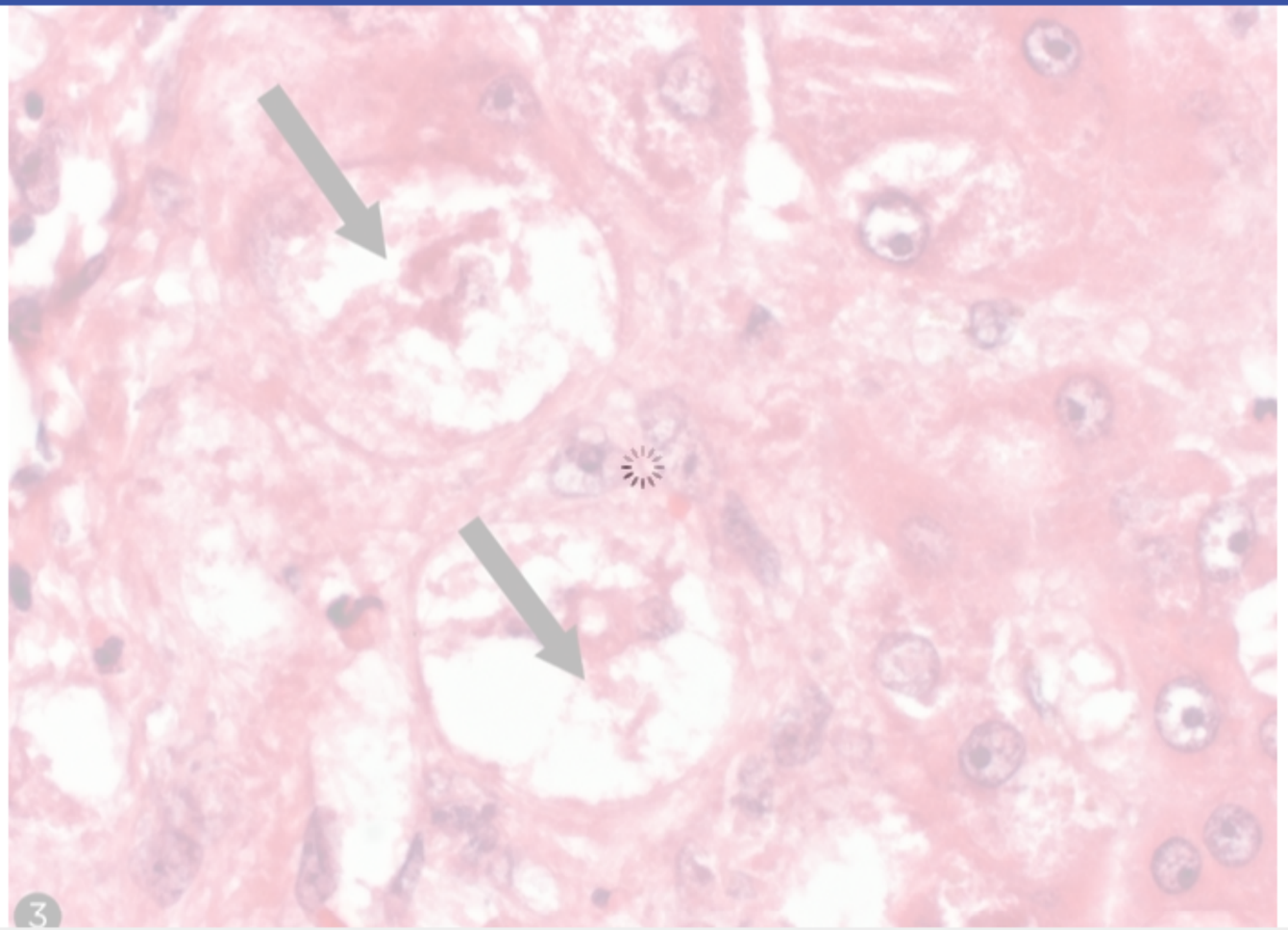

Zoom In | Zoom Out | Reset | Add To New Card | Existing Card

Subject System Topic

Block Time Remaining: 00:00:47
TUTOR

5 | Feedback | Suspend | End Block

Settings

1 2 3 4 5 6 7 8 9 10 11 12 13 14 15 16 17 18 19 20 21 22 23 24 25 26 27 28 29 30

Item 24 of 38
Question Id: 367

Mark | Previous | Next | Full Screen | Tutorial | Lab Values | Notes | Calculator | Reverse Color | Text Zoom | Settings

Hepatitis B infection, one of the most common causes of hepatic injury in the United States, is frequently transmitted sexually or via

Exhibit Display

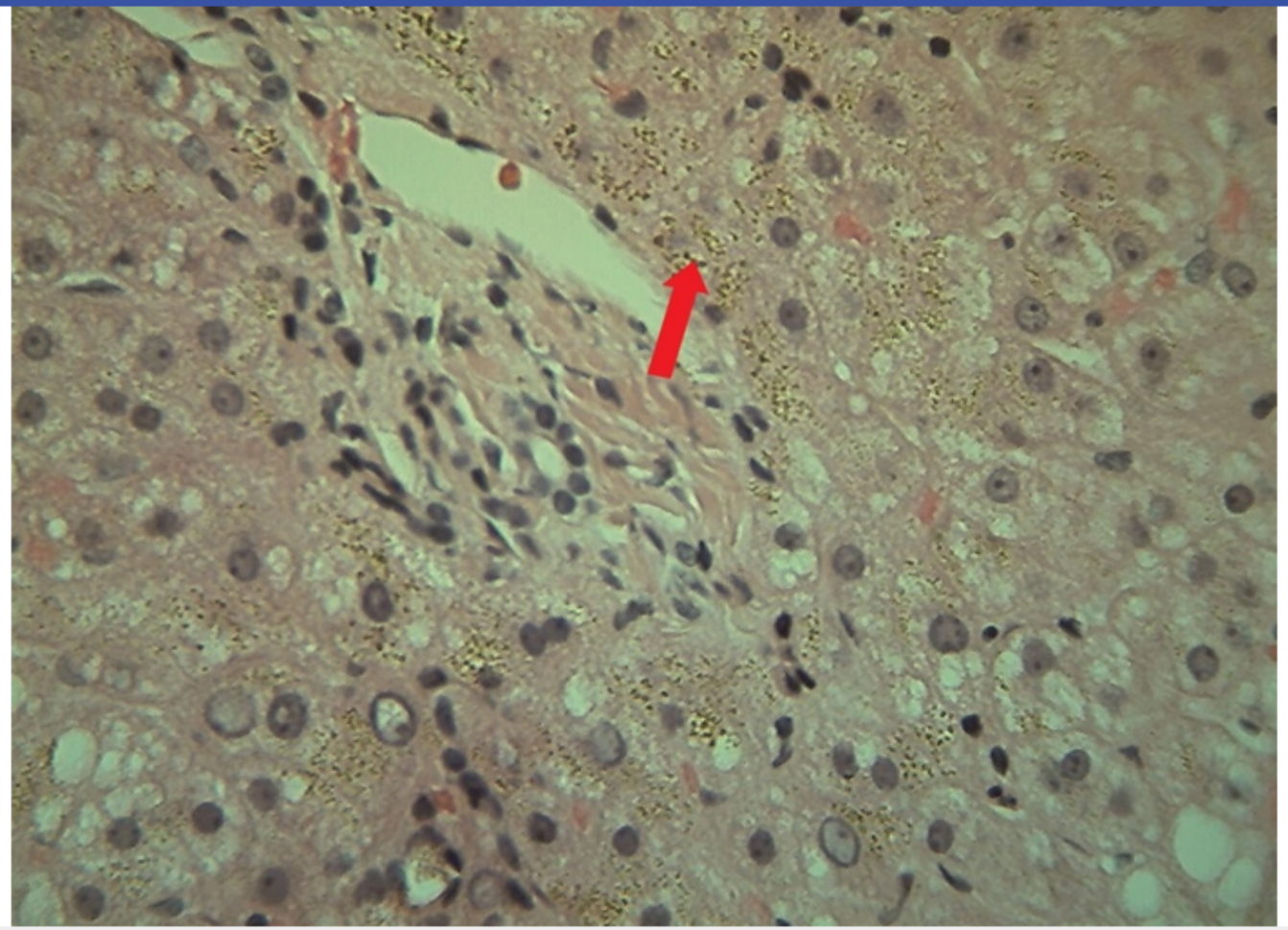

Zoom In | Zoom Out | Reset | Add To New Card | Existing Card

Subject System Topic

Block Time Remaining: 00:00:47
TUTOR

5 | Feedback | Suspend | End Block

The following vignette applies to the next **2** items. The items in the set must be answered in sequential order. Once you click **Proceed to Next Item**, you will not be able to add or change an answer.

A 54-year-old man comes to the emergency department after an episode of bloody vomiting. He has had no fever, chills, abdominal pain, diarrhea, or constipation. The patient has a history of alcohol abuse with multiple previous hospital admissions due to alcohol withdrawal and generalized tonic-clonic seizures. He also has a history of intravenous drug abuse and is currently enrolled in a methadone maintenance program. Blood pressure is 96/62 mm Hg and pulse is 102/min. On examination, the patient appears comfortable but develops dizziness when asked to sit up. There is no jugular venous distension. The abdomen is distended with dullness to percussion at both flanks. The liver is enlarged on palpation, and the tip of the spleen is also palpable. There is trace pedal edema. Laboratory studies show:

Hemoglobin	9.7 g/dL
Mean corpuscular volume	98 fL
Leukocytes	5,000/mm^3
Platelets	78,000/mm^3

Item 1 of 2

Histopathologic examination of this patient's spleen is most likely to show which of the following?

A. Extramedullary hematopoiesis
B. Histiocytic proliferation
C. Lymphoid follicle expansion
D. Metastatic deposits
E. Red pulp expansion

9
10
11
12
13
14
15
16
17
18
19
20
21
22
23
24
25
26
27
28
29
30
31
32
33
34
35
36
37
38

A 54-year-old man comes to the emergency department after an episode of bloody vomiting. He has had no fever, chills, abdominal pain, diarrhea, or constipation. The patient has a history of alcohol abuse with multiple previous hospital admissions due to alcohol withdrawal and generalized tonic-clonic seizures. He also has a history of intravenous drug abuse and is currently enrolled in a methadone maintenance program. Blood pressure is 96/62 mm Hg and pulse is 102/min. On examination, the patient appears comfortable but develops dizziness when asked to sit up. There is no jugular venous distension. The abdomen is distended with dullness to percussion at both flanks. The liver is enlarged on palpation, and the tip of the spleen is also palpable. There is trace pedal edema. Laboratory studies show:

Hemoglobin	9.7 g/dL
Mean corpuscular volume	98 fL
Leukocytes	5,000/mm^3
Platelets	78,000/mm^3

Item 1 of 2

Histopathologic examination of this patient's spleen is most likely to show which of the following?

A. Extramedullary hematopoiesis
B. Histiocytic proliferation
C. Lymphoid follicle expansion
D. Metastatic deposits
E. Red pulp expansion

Add To New Card | Add To Existing Card

Submit

9 10 11 12 13 14 15 16 17 18 19 20 21 22 23 24 25 26 27 28 29 30 31 32 33 34 35 36 37 38

A 54-year-old man comes to the emergency department after an episode of bloody vomiting. He has had no fever, chills, abdominal pain, diarrhea, or constipation. The patient has a history of alcohol abuse with multiple previous hospital admissions due to alcohol withdrawal and generalized tonic-clonic seizures. He also has a history of intravenous drug abuse and is currently enrolled in a methadone maintenance program. Blood pressure is 96/62 mm Hg and pulse is 102/min. On examination, the patient appears comfortable but develops dizziness when asked to sit up. There is no jugular venous distension. The abdomen is distended with dullness to percussion at both flanks. The liver is enlarged on palpation, and the tip of the spleen is also palpable. There is trace pedal edema. Laboratory studies show:

Hemoglobin	9.7 g/dL
Mean corpuscular volume	98 fL
Leukocytes	5,000/mm^3
Platelets	78,000/mm^3

Item 1 of 2

Histopathologic examination of this patient's spleen is most likely to show which of the following?

A. Extramedullary hematopoiesis (25%)
B. Histiocytic proliferation (5%)
C. Lymphoid follicle expansion (4%)
D. Metastatic deposits (1%)
✓ E. Red pulp expansion (62%)

Omitted
Correct answer

62%
Answered correctly

04 secs
Time Spent

01/27/2020
Last Updated

9
10
11
12
13
14
15
16
17
18
19
20
21
22
23
24
25
26
27
28
29
30
31
32
33
34
35
36
37
38

Explanation

This patient with a history of significant alcohol and intravenous drug abuse has evidence of **alcoholic liver disease** (ALD). His hematemesis, orthostatic symptoms, and normocytic anemia are likely due to acute bleeding from esophageal varices. Although chronic gastrointestinal blood loss can cause microcytic anemia due to depletion of iron stores and reduced hemoglobin synthesis, acute hemorrhage (as in this patient) is usually associated with normal mean corpuscular volume. ALD also causes thrombocytopenia due to decreased platelet production, increased destruction, and splenic sequestration.

Fibrosis and distortion of intrahepatic vasculature in ALD obstructs blood flow through the liver, leading to **portal hypertension**. Because the splenic vein is part of the portal circulation, any condition that causes portal hypertension can lead to **splenomegaly** with congestive hypersplenism. Venous congestion causes apparent **expansion of the red pulp** of the spleen, which is composed of blood-filled sinuses and cords lined by reticuloendothelial-type cells.

(Choice A) Extramedullary hematopoiesis results when hematopoietic precursor cells are displaced from the bone marrow and infiltrate the liver and spleen preferentially, resulting in splenomegaly. A common condition in which this occurs is myelofibrosis.

(Choices B and D) Histiocytic proliferation can cause splenomegaly in the setting of Langerhans cell histiocytosis (formerly known as histiocytosis X), but this is a rare disease with highest incidence in childhood. Metastatic tumors (eg, lung, breast, colorectal cancer) can infiltrate the spleen and lead to hypersplenism, but this patient has no history of malignancy. Given this patient's substance abuse history, ALD is much more likely.

(Choice C) Lymphoid follicle expansion can cause hypersplenism in the setting of systemic infections (eg, infectious mononucleosis) or as a result of immunologic diseases (eg, systemic lupus erythematosus, rheumatoid arthritis [Felty syndrome]).

Educational objective:
Portal hypertension, as seen in alcoholic liver disease, produces splenomegaly by causing congestion of blood within the spleen, which produces expansion of the red pulp.

Pathology	Gastrointestinal & Nutrition	Cirrhosis
Subject	System	Topic

9
10
11
12
13
14
15
16
17
18
19
20
21
22
23
24
25
26
27
28
29
30
31
32
33
34
35
36
37
38

orthostatic symptoms, and normocytic anemia are likely due to acute bleeding from esophageal varices. Although chronic gastrointestinal blood loss can cause microcytic anemia due to depletion of iron stores and reduced hemoglobin synthesis, acute hemorrhage (as in this patient) is usually associated with normal mean corpuscular volume. ALD also causes thrombocytopenia due to decreased platelet production, increased destruction, and splenic sequestration.

Fibrosis and distortion of intrahepatic vasculature in ALD obstructs blood flow through the liver, leading to **portal hypertension**. Because the splenic vein is part of the portal circulation, any condition that causes portal hypertension can lead to **splenomegaly** with congestive hypersplenism. Venous congestion causes apparent **expansion of the red pulp** of the spleen, which is composed of blood-filled sinuses and cords lined by reticuloendothelial-type cells.

(Choice A) Extramedullary hematopoiesis results when hematopoietic precursor cells are displaced from the bone marrow and infiltrate the liver and spleen preferentially, resulting in splenomegaly. A common condition in which this occurs is myelofibrosis.

(Choices B and D) Histiocytic proliferation can cause splenomegaly in the setting of Langerhans cell histiocytosis (formerly known as histiocytosis X), but this is a rare disease with highest incidence in childhood. Metastatic tumors (eg, lung, breast, colorectal cancer) can infiltrate the spleen and lead to hypersplenism, but this patient has no history of malignancy. Given this patient's substance abuse history, ALD is much more likely.

(Choice C) Lymphoid follicle expansion can cause hypersplenism in the setting of systemic infections (eg, infectious mononucleosis) or as a result of immunologic diseases (eg, systemic lupus erythematosus, rheumatoid arthritis [Felty syndrome]).

Educational objective:
Portal hypertension, as seen in alcoholic liver disease, produces splenomegaly by causing congestion of blood within the spleen, which produces expansion of the red pulp.

Pathology	Gastrointestinal & Nutrition	Cirrhosis
Subject	System	Topic

Copyright © UWorld. All rights reserved.

9
10
11
12
13
14
15
16
17
18
19
20
21
22
23
24
25
26
27
28
29
30
31
32
33
34
35
36
37
38

Item 2 of 2

After initial stabilization with intravenous fluids and blood products, the patient develops another bout of bloody emesis. Urgent upper gastrointestinal endoscopy confirms esophageal varices. Which of the following peptides is most likely to immediately decrease the portal venous pressure in this patient?

A. Cholecystokinin

B. Glucagon

C. Pentagastrin

D. Secretin

E. Somatostatin

Submit

9
10
11
12
13
14
15
16
17
18
19
20
21
22
23
24
25
26
27
28
29
30
31
32
33
34
35
36
37
38

Item 2 of 2

After initial stabilization with intravenous fluids and blood products, the patient develops another bout of bloody emesis. Urgent upper gastrointestinal endoscopy confirms esophageal varices. Which of the following peptides is most likely to immediately decrease the portal venous pressure in this patient?

A. Cholecystokinin (3%)

B. Glucagon (4%)

C. Pentagastrin (3%)

D. Secretin (1%)

✓ E. Somatostatin (87%)

Omitted
Correct answer
E

87%
Answered correctly

02 secs
Time Spent

01/27/2020
Last Updated

Explanation

Prolonged **portal hypertension** in alcoholic liver disease can cause venous engorgement and dilation (ie, **varices**) at sites of portocaval anastomosis in the esophagus, rectum, umbilicus, and retroperitoneum. Subsequent rupture of esophageal varices can cause rapid blood loss and carries high mortality.

Acute management of variceal hemorrhage requires rapid lowering of portal pressure. **Somatostatin** and **octreotide** (a long-acting somatostatin analog) inhibit the release of endogenous hormones (eg, glucagon, vasoactive intestinal peptide) that induce splanchnic vasodilation, thereby

9
10
11
12
13
14
15
16
17
18
19
20
21
22
23
24
25
26
27
28
29
30
31
32
33
34
35
36
37
38

Prolonged **portal hypertension** in alcoholic liver disease can cause venous engorgement and dilation (ie, **varices**) at sites of portocaval anastomosis in the esophagus, rectum, umbilicus, and retroperitoneum. Subsequent rupture of esophageal varices can cause rapid blood loss and carries high mortality.

Acute management of variceal hemorrhage requires rapid lowering of portal pressure. **Somatostatin** and **octreotide** (a long-acting somatostatin analog) inhibit the release of endogenous hormones (eg, glucagon, vasoactive intestinal peptide) that induce splanchnic vasodilation, thereby indirectly **reducing portal blood flow**. Vasopressin directly causes splanchnic vasoconstriction and also can lower portal flow in acute variceal hemorrhage, but its use is limited by systemic vasoconstriction.

(Choices A, B, and D) Glucagon causes splanchnic vasodilation, raising portal pressure and worsening variceal bleeding. Cholecystokinin induces contraction of the gallbladder and expulsion of pancreatic exocrine secretions into the duodenum, whereas the primary function of secretin is to alkalinize the duodenal contents; both of these hormones increase glucagon secretion and would therefore be counterproductive in this setting.

(Choice C) Pentagastrin is a synthetic gastrin analog that stimulates secretion of gastric acid. Its primary clinical use is as a diagnostic agent; pentagastrin induces a significant rise in calcitonin secretion in patients with medullary carcinoma of the thyroid and serotonin secretion in patients with carcinoid tumors.

Educational objective:
Acute management of variceal hemorrhage requires rapid lowering of portal pressure. Somatostatin and octreotide (a long-acting somatostatin analog) inhibit the release of hormones that induce splanchnic vasodilation, indirectly causing splanchnic vasoconstriction and reduced portal blood flow.

References

- Portal hypertension and variceal hemorrhage.
- Acute variceal bleeding.

Pathology | Gastrointestinal & Nutrition | Esophageal varices

9
10
11
12
13
14
15
16
17
18
19
20
21
22
23
24
25
26
27
28
29
30
31
32
33
34
35
36
37
38

A 6-month-old Caucasian male undergoes evaluation for persistent constipation and abdominal distention. Barium enema performed shows a relatively-narrow rectum and rectosigmoid area. The rest of the colon is significantly dilated. Biopsy of the colon is scheduled. Sampling from which of the following colon areas would be most useful for making diagnosis?

A. Mucosa of the dilated part

B. Submucosa of the dilated part

C. Muscular layer of the dilated part

D. Mucosa of the narrow part

E. Submucosa of the narrow part

Submit

9
10
11
12
13
14
15
16
17
18
19
20
21
22
23
24
25
26
27
28
29
30
31
32
33
34
35
36
37
38

A 6-month-old Caucasian male undergoes evaluation for persistent constipation and abdominal distention. Barium enema performed shows a relatively-narrow rectum and rectosigmoid area. The rest of the colon is significantly dilated. Biopsy of the colon is scheduled. Sampling from which of the following colon areas would be most useful for making diagnosis?

A. Mucosa of the dilated part (2%)

B. Submucosa of the dilated part (10%)

C. Muscular layer of the dilated part (13%)

D. Mucosa of the narrow part (9%)

✓ E. Submucosa of the narrow part (64%)

Omitted
Correct answer
E

64%
Answered correctly

01 sec
Time Spent

02/03/2020
Last Updated

Explanation

This 6-month-old with Hirschsprung disease demonstrates that symptom severity depends on the extent of colonic involvement. If a large area of the bowel is involved, the disease will manifest during the first few days of life with obstructive symptoms (failure to pass meconium, bilious vomiting, and abdominal distention). If only a short area is affected, the disease may go undetected for months or years. In this case, persistent constipation, abdominal distention, and failure to thrive are typical. Barium enema in such patients shows narrowing in the rectosigmoid area. Proximal to the obstruction, the bowel is dilated and filled with feces.

9
10
11
12
13
14
15
16
17
18
19
20
21
22
23
24
25
26
27
28
29
30
31
32
33
34
35
36
37
38

Explanation

This 6-month-old with Hirschsprung disease demonstrates that symptom severity depends on the extent of colonic involvement. If a large area of the bowel is involved, the disease will manifest during the first few days of life with obstructive symptoms (failure to pass meconium, bilious vomiting, and abdominal distention). If only a short area is affected, the disease may go undetected for months or years. In this case, persistent constipation, abdominal distention, and failure to thrive are typical. Barium enema in such patients shows narrowing in the rectosigmoid area. Proximal to the obstruction, the bowel is dilated and filled with feces.

Rectal biopsy is necessary for the diagnosis of Hirschsprung disease, a condition that results from the failure of neural crest cells to migrate to the intestinal wall. Normally, these cells develop into ganglion cells of the submucosal (Meissner) and myenteric (Auerbach) plexi of the bowel wall. Since those cells migrate caudally, the rectum is always involved. The submucosa of rectum (the narrowed segment) should be biopsied to demonstrate the absence of ganglionic cells.

(Choices A, B and C) Mucosa, submucosa, and muscular layer of the dilated part are histologically unremarkable. Proximal to the aganglionic portion of the bowel, distention occurs only as a result of fecal retention. The distended portion of the bowel is completely normal; however, after years of pressure, the wall of the proximal (distended) colon may become thin and prone to rupture.

(Choice D) Ganglionic cells never occur in the mucosa. Biopsy down to the submucosa is required.

Educational Objective:
Submucosal (Meissner) and myenteric (Auerbach) autonomic plexi are absent in the affected segment of the bowel in Hirschsprung disease. The submucosa of the narrowed area is the most superficial layer where the absence of ganglion cells can be seen.

Pathology	Gastrointestinal & Nutrition	Hirschsprung's disease
Subject	System	Topic

Copyright © UWorld. All rights reserved.

9
10
11
12
13
14
15
16
17
18
19
20
21
22
23
24
25
26
27
28
29
30
31
32
33
34
35
36
37
38

A 10-year-old boy is brought to the hospital for difficulty swallowing. During dinner a few hours ago, a piece of chicken became stuck in the patient's mid-chest region. His parents say that he has previously had the sensation of food becoming stuck, but it has never lasted this long. The patient has vomited multiple times, but the chicken has not dislodged. Medical history is significant for eczema. He is drooling and visibly uncomfortable. An upper endoscopy is performed to remove the chicken from the esophagus, which exhibits multiple stacked, circular, ringlike indentations; linear furrowing; and scattered, small, whitish papules. Which of the following findings is most likely to be seen on biopsy of this patient's esophagus?

- A. Eosinophilic infiltration of the esophageal mucosa
- B. Ganglionic degeneration within the myenteric plexus
- C. Intestinal metaplasia of the esophageal epithelium
- D. Replacement of the esophagus with fibrous tissue
- E. Squamous cells with eosinophilic intranuclear inclusions

Submit

9, 10, 11, 12, 13, 14, 15, 16, 17, 18, 19, 20, 21, 22, 23, 24, 25, 26, 27, 28, 29, 30, 31, 32, 33, 34, 35, 36, 37, 38

A 10-year-old boy is brought to the hospital for difficulty swallowing. During dinner a few hours ago, a piece of chicken became stuck in the patient's mid-chest region. His parents say that he has previously had the sensation of food becoming stuck, but it has never lasted this long. The patient has vomited multiple times, but the chicken has not dislodged. Medical history is significant for eczema. He is drooling and visibly uncomfortable. An upper endoscopy is performed to remove the chicken from the esophagus, which exhibits multiple stacked, circular, ringlike indentations; linear furrowing; and scattered, small, whitish papules. Which of the following findings is most likely to be seen on biopsy of this patient's esophagus?

- ✓ A. Eosinophilic infiltration of the esophageal mucosa (56%)
- B. Ganglionic degeneration within the myenteric plexus (11%)
- C. Intestinal metaplasia of the esophageal epithelium (2%)
- D. Replacement of the esophagus with fibrous tissue (15%)
- E. Squamous cells with eosinophilic intranuclear inclusions (13%)

Omitted
Correct answer
A

56%
Answered correctly

01 sec
Time Spent

03/19/2020
Last Updated

Explanation

Eosinophilic esophagitis	
Pathogenesis	• Chronic Th2 cell–mediated disorder triggered by food antigens

9
10
11
12
13
14
15
16
17
18
19
20
21
22
23
24
25
26
27
28
29
30
31
32
33
34
35
36
37
38

Eosinophilic esophagitis	
Pathogenesis	• Chronic Th2 cell–mediated disorder triggered by food antigens • Eosinophilic infiltration of the esophageal mucosa
Epidemiology	• Men > women • History of atopic conditions
Clinical features	• Intermittent dysphagia • Reflux, vomiting, chest or abdominal pain • Esophageal food impaction

Th2 = T helper 2.

This patient with a history of solid food dysphagia has an esophageal food impaction due to **eosinophilic esophagitis** (EOE). EOE is a chronic Th2 cell−mediated disorder triggered by food antigen exposure. When activated, Th2 cells release chemokines (eg, IL-13, IL-5) that stimulate eosinophilic recruitment to the esophageal mucosa.

EOE is most common in males with a history of **atopic conditions** (eg, eczema, asthma). Patients often have **intermittent solid food dysphagia**. Other symptoms include vomiting, reflux, and chest and upper abdominal pain. When EOE is severe, food can become trapped in the esophagus (ie, **esophageal food impaction**), requiring urgent upper endoscopy to remove the impacted food bolus.

Classic endoscopic findings include stacked, circular, **ringlike indentations**; **linear furrowing**; and scattered, small, whitish papules (ie, **eosinophilic microabscesses**). Biopsies demonstrate **eosinophilic mucosal infiltration**.

(Choice B) Achalasia results from ganglionic degeneration within the esophageal myenteric plexus, leading to the inability to relax the lower esophageal sphincter. It typically causes dysphagia of both solids and liquids and is rare in children. There are no specific endoscopic findings; however, a barium swallow demonstrating a bird-beak appearance of the esophagus is characteristic.

(Choice C) Barrett esophagus is a premalignant condition characterized by intestinal metaplasia of the esophageal epithelium. It typically develops in older patients with uncontrolled gastroesophageal reflux but does not usually cause food impaction.

9
10
11
12
13
14
15
16
17
18
19
20
21
22
23
24
25
26
27
28
29
30
31
32
33
34
35
36
37
38

Th2 cell−mediated disorder triggered by food antigen exposure. When activated, Th2 cells release chemokines (eg, IL-13, IL-5) that stimulate eosinophilic recruitment to the esophageal mucosa.

EOE is most common in males with a history of **atopic conditions** (eg, eczema, asthma). Patients often have **intermittent solid food dysphagia**. Other symptoms include vomiting, reflux, and chest and upper abdominal pain. When EOE is severe, food can become trapped in the esophagus (ie, **esophageal food impaction**), requiring urgent upper endoscopy to remove the impacted food bolus.

Classic endoscopic findings include stacked, circular, **ringlike indentations**; **linear furrowing**; and scattered, small, whitish papules (ie, **eosinophilic microabscesses**). Biopsies demonstrate **eosinophilic mucosal infiltration**.

(Choice B) Achalasia results from ganglionic degeneration within the esophageal myenteric plexus, leading to the inability to relax the lower esophageal sphincter. It typically causes dysphagia of both solids and liquids and is rare in children. There are no specific endoscopic findings; however, a barium swallow demonstrating a bird-beak appearance of the esophagus is characteristic.

(Choice C) Barrett esophagus is a premalignant condition characterized by intestinal metaplasia of the esophageal epithelium. It typically develops in older patients with uncontrolled gastroesophageal reflux but does not usually cause food impaction.

(Choice D) Systemic sclerosis results in esophageal smooth muscle fibrosis, leading to severe gastroesophageal reflux. It occurs more commonly in adult women and usually presents with thickened skin and Raynaud phenomenon. Endoscopy typically demonstrates a dilated esophagus.

(Choice E) Herpes simplex virus esophagitis is characterized histologically by eosinophilic intranuclear inclusions within esophageal squamous cells. It typically occurs in immunocompromised patients and results in severe odynophagia. Endoscopy demonstrates ulcerations with a volcano-like appearance.

Educational objective:
Eosinophilic esophagitis is a Th2 cell−mediated disorder leading to eosinophilic infiltration of the esophageal mucosa. It occurs most commonly in males with a history of atopic conditions and typically presents with solid food dysphagia, reflux, and occasionally food impaction. Classic endoscopic findings include stacked, circular, ringlike indentations; linear furrowing; and scattered, small, whitish papules (ie, eosinophilic microabscesses).

9
10
11
12
13
14
15
16
17
18
19
20
21
22
23
24
25
26
27
28
29
30
31
32
33
34
35
36
37
38

Th2 cell–mediated disorder triggered by food antigen exposure. When activated, Th2 cells release chemokines (eg, IL-13, IL-5) that stimulate

Exhibit Display

Achalasia

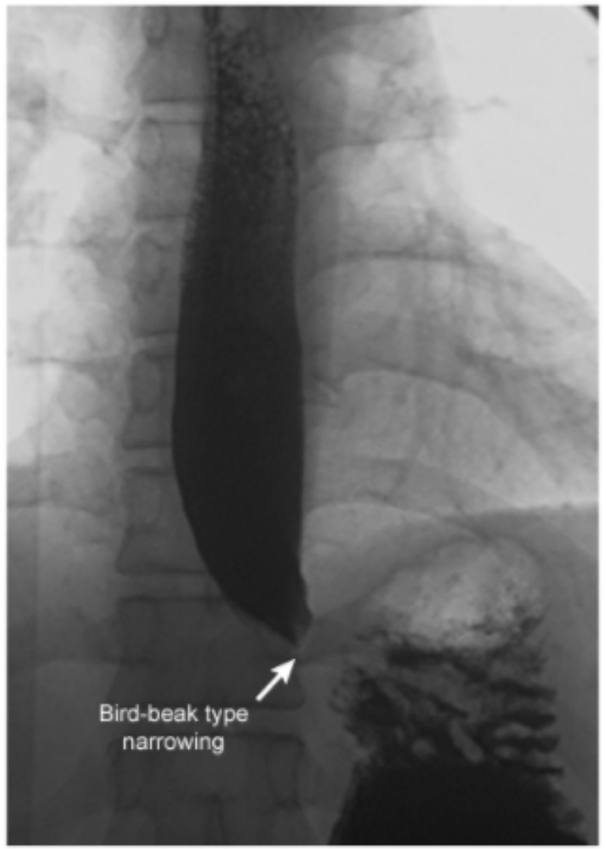

©UWorld

Zoom In | Zoom Out | Reset | Add To New Card | Existing Card

9
10
11
12
13
14
15
16
17
18
19
20
21
22
23
24
25
26
27
28
29
30
31
32
33
34
35
36
37
38

eosinophilic microabscesses). Biopsies demonstrate **eosinophilic mucosal infiltration**.

(Choice B) Achalasia results from ganglionic degeneration within the esophageal myenteric plexus, leading to the inability to relax the lower esophageal sphincter. It typically causes dysphagia of both solids and liquids and is rare in children. There are no specific endoscopic findings; however, a barium swallow demonstrating a bird-beak appearance of the esophagus is characteristic.

(Choice C) Barrett esophagus is a premalignant condition characterized by intestinal metaplasia of the esophageal epithelium. It typically develops in older patients with uncontrolled gastroesophageal reflux but does not usually cause food impaction.

(Choice D) Systemic sclerosis results in esophageal smooth muscle fibrosis, leading to severe gastroesophageal reflux. It occurs more commonly in adult women and usually presents with thickened skin and Raynaud phenomenon. Endoscopy typically demonstrates a dilated esophagus.

(Choice E) Herpes simplex virus esophagitis is characterized histologically by eosinophilic intranuclear inclusions within esophageal squamous cells. It typically occurs in immunocompromised patients and results in severe odynophagia. Endoscopy demonstrates ulcerations with a volcano-like appearance.

Educational objective:
Eosinophilic esophagitis is a Th2 cell−mediated disorder leading to eosinophilic infiltration of the esophageal mucosa. It occurs most commonly in males with a history of atopic conditions and typically presents with solid food dysphagia, reflux, and occasionally food impaction. Classic endoscopic findings include stacked, circular, ringlike indentations; linear furrowing; and scattered, small, whitish papules (ie, eosinophilic microabscesses).

References

- Eosinophilic esophagitis: a 10-year experience in 381 children.
- ACG clinical guideline: Evidenced based approach to the diagnosis and management of esophageal eosinophilia and eosinophilic esophagitis (EoE).

Pathology	Gastrointestinal & Nutrition	Esophagitis
Subject	System	Topic

A cross-section of the right coronary artery of a 34-year-old Caucasian male who died in the cardiac intensive care unit is shown on the slide below.

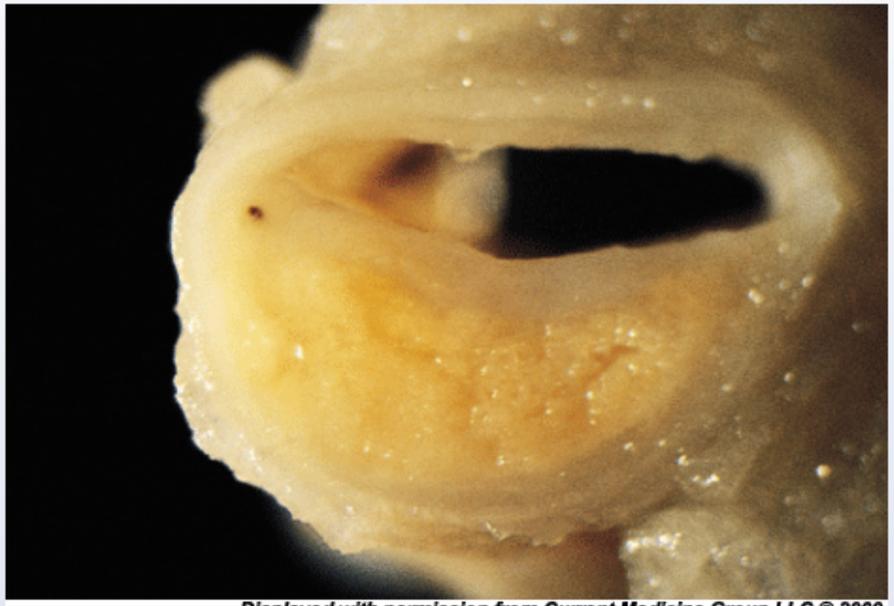

Displayed with permission from Current Medicine Group LLC © 2000.

His father died of a heart attack at the age of 40. Assuming this patient's disease had a genetic basis, poor receptor expression in which of the following organs is most likely responsible for his condition?

A. Small intestine

B. Kidney

C. Liver

D. Heart

9
10
11
12
13
14
15
16
17
18
19
20
21
22
23
24
25
26
27
28
29
30
31
32
33
34
35
36
37
38

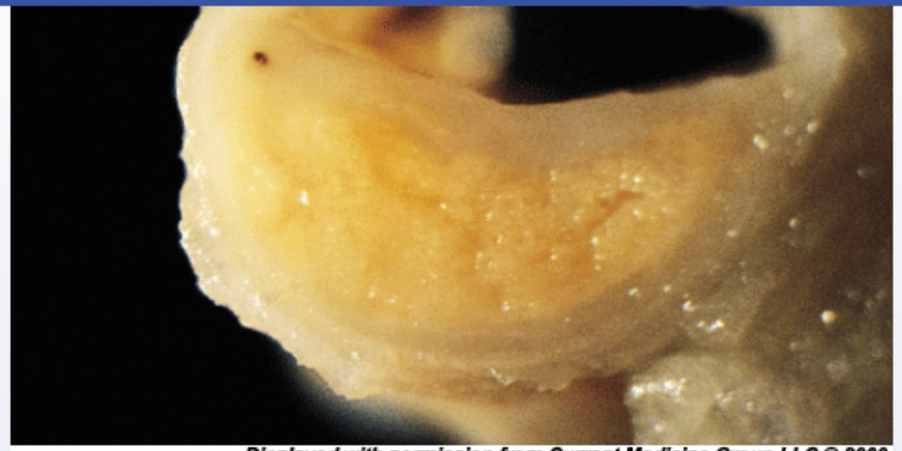

Displayed with permission from Current Medicine Group LLC © 2000.

His father died of a heart attack at the age of 40. Assuming this patient's disease had a genetic basis, poor receptor expression in which of the following organs is most likely responsible for his condition?

- A. Small intestine
- B. Kidney
- C. Liver
- D. Heart
- E. Lung
- F. Pancreas

Submit

9
10
11
12
13
14
15
16
17
18
19
20
21
22
23
24
25
26
27
28
29
30
31
32
33
34
35
36
37
38

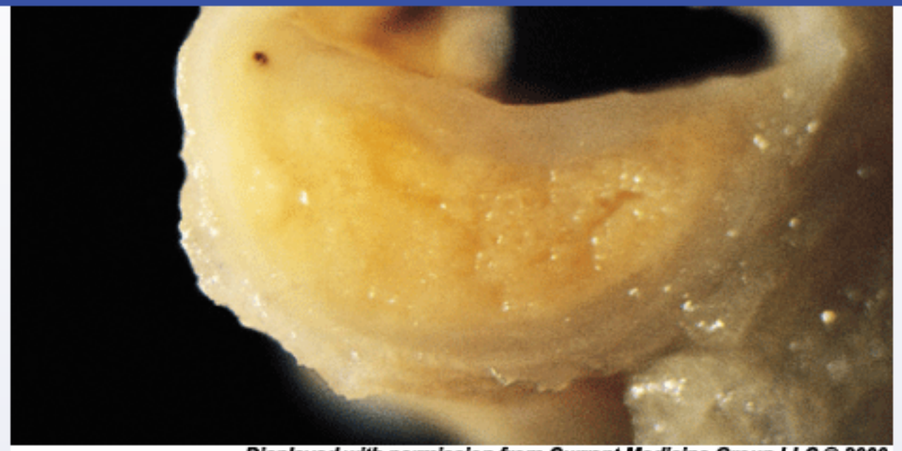

Displayed with permission from Current Medicine Group LLC © 2000.

His father died of a heart attack at the age of 40. Assuming this patient's disease had a genetic basis, poor receptor expression in which of the following organs is most likely responsible for his condition?

- A. Small intestine (3%)
- B. Kidney (2%)
- ✓ C. Liver (87%)
- D. Heart (3%)
- E. Lung (1%)
- F. Pancreas (2%)

Omitted
Correct answer

87%
Answered correctly

04 secs
Time Spent

02/03/2020
Last Updated

9
10
11
12
13
14
15
16
17
18
19
20
21
22
23
24
25
26
27
28
29
30
31
32
33
34
35
36
37
38

Explanation

This patient's right coronary artery (RCA) shows significant occlusion by a large atheromatous plaque with a soft, yellow, lipid core composed mainly of cholesterol and cholesterol esters. Presumably, this patient died from a complication of advanced atherosclerosis, such as a myocardial infarction. His father's similar fate at a young age suggests a familial condition, most likely familial hypercholesterolemia. Familial hypercholesterolemia is one of the most common inherited disorders, and results from autosomal dominant mutations of the LDL receptor gene.

The liver LDL receptor is normally the greatest contributor to the removal of cholesterol-containing IDL and LDL particles from the circulation. Although numerous other cell types, including smooth muscle cells, adrenocortical cells, fibroblasts, and lymphocytes also express high-affinity LDL receptors, approximately 70% of the plasma LDL is normally cleared by the liver. Heterozygotes with one mutant LDL receptor gene have a 2- to 3-fold elevation of plasma cholesterol from birth, due to reduced hepatic IDL and LDL uptake. Homozygotes may have a 5- to 6-fold elevation. In both heterozygotes and homozygotes, the progression of atherosclerosis with aging is accelerated. Complications include coronary artery disease at an unusually young age, as was the case for the patient in the vignette.

(Choices A, B, D, E and F) Although many cell types express the LDL receptor, their rate of LDL uptake from the circulation is usually less than that of hepatocytes. The liver is also the major site of cholesterol catabolism and excretion, making it the most important organ in serum cholesterol level homeostasis.

Educational Objective:
Familial hypercholesterolemia, one of the most common autosomal dominant disorders, is the result of heterozygous or homozygous LDL receptor gene mutations, which cause hepatocyte under-expression of functional LDL receptors. This condition can lead to accelerated atherosclerosis and early-onset coronary artery disease.

Pathology	Gastrointestinal & Nutrition	Atherosclerosis
Subject	System	Topic

Copyright © UWorld. All rights reserved.

9
10
11
12
13
14
15
16
17
18
19
20
21
22
23
24
25
26
27
28
29
30
31
32
33
34
35
36
37
38

A 43-year-old man is evaluated in the hospital for a medical illness. He has traveled to various countries on missionary trips and recently returned from South America. The patient has no prior medical history and takes no medications. His father has a history of alcohol dependence complicated by cirrhosis and portal hypertension. A liver biopsy is performed, and light microscopy of the tissue demonstrates spotty hepatocyte necrosis and inflammatory cell infiltration, as shown in the image below.

Settings

Item 30 of 38
Question Id: 366

Mark | Previous | Next | Full Screen | Tutorial | Lab Values | Notes | Calculator | Reverse Color | Text Zoom | Settings

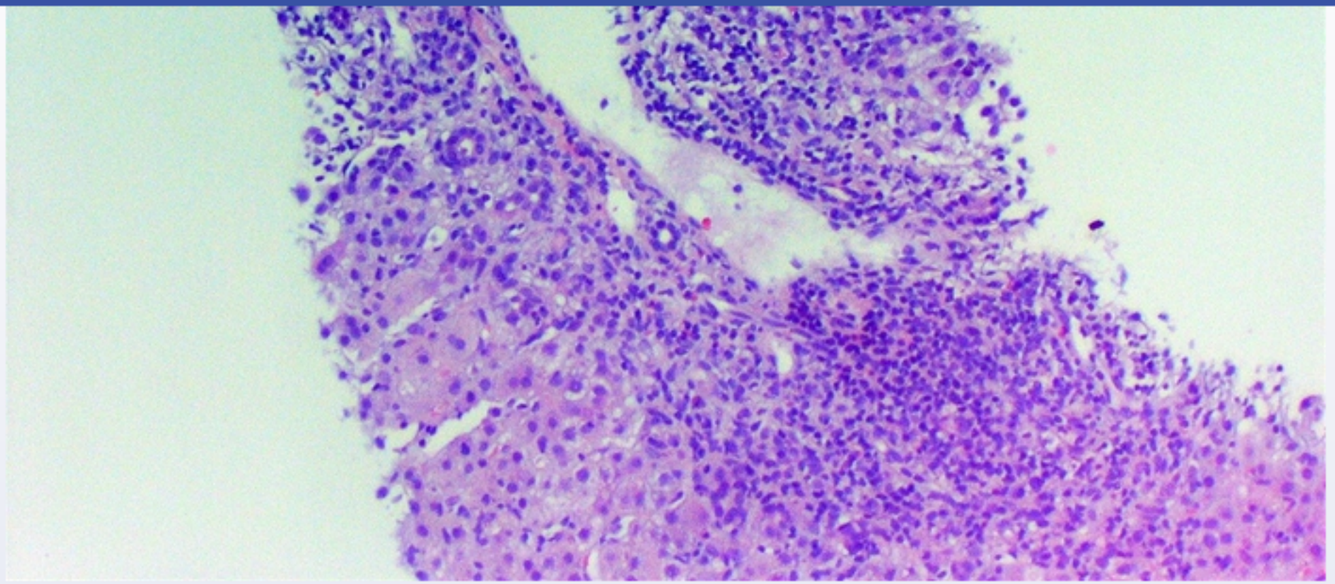

Which of the following is the most likely initial clinical presentation of this patient?

- A. Clay-colored stools and osteoporosis
- B. Fever, anorexia, and dark-colored urine
- C. Prolonged pruritus and fatigue
- D. Skin pigmentation and diabetes mellitus
- E. Upper gastrointestinal bleeding and ascites

Submit

Block Time Remaining: 00:01:01
TUTOR

5 | Feedback | Suspend | End Block

9, 10, 11, 12, 13, 14, 15, 16, 17, 18, 19, 20, 21, 22, 23, 24, 25, 26, 27, 28, 29, 30, 31, 32, 33, 34, 35, 36, 37, 38

Settings

9
10
11
12
13
14
15
16
17
18
19
20
21
22
23
24
25
26
27
28
29
30
31
32
33
34
35
36
37
38

Item 30 of 38
Question Id: 366

Mark | Previous | Next | Full Screen | Tutorial | Lab Values | Notes | Calculator | Reverse Color | Text Zoom | Settings

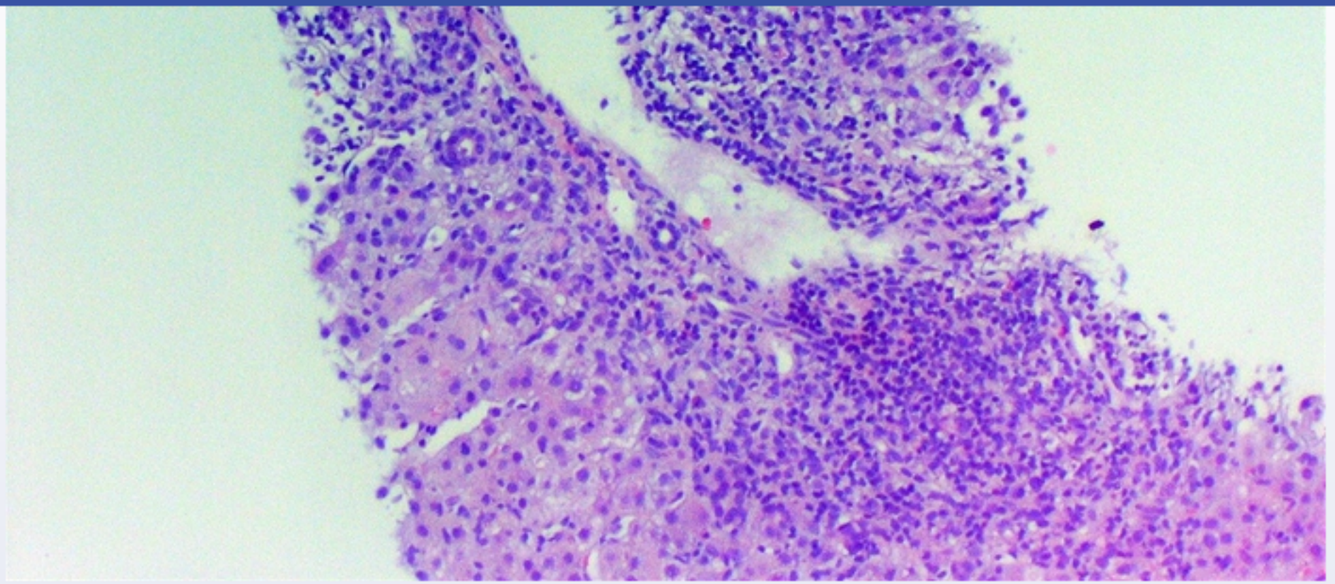

Which of the following is the most likely initial clinical presentation of this patient?

- A. Clay-colored stools and osteoporosis (3%)
- ✓ B. Fever, anorexia, and dark-colored urine (62%)
- C. Prolonged pruritus and fatigue (19%)
- D. Skin pigmentation and diabetes mellitus (5%)
- E. Upper gastrointestinal bleeding and ascites (8%)

Omitted
Correct answer

62%
Answered correctly

03 secs
Time Spent

02/05/2020
Last Updated

Block Time Remaining: 00:01:02
TUTOR

5 | Feedback | Suspend | End Block

9
10
11
12
13
14
15
16
17
18
19
20
21
22
23
24
25
26
27
28
29
30
31
32
33
34
35
36
37
38

This patient's liver biopsy findings and recent travel to an endemic region suggest **acute hepatitis A infection**. Acute viral hepatitis is characterized histologically by the presence of "spotty necrosis" with ballooning degeneration (hepatocyte swelling with wispy/clear cytoplasm), Councilman bodies (eosinophilic apoptotic hepatocytes), and mononuclear cell infiltrates.

Patients typically present acutely with a prodrome of **fever**, malaise, **anorexia**, nausea/vomiting, and right upper quadrant abdominal pain. After several days (up to 1 week), prodromal symptoms lessen as patients develop signs of cholestasis such as jaundice, pruritus, **dark-colored urine** (due to increased conjugated bilirubin levels), and acholic stool (lacks bilirubin pigment). The illness is self-limited and does not progress to chronic hepatitis, cirrhosis, or hepatocellular carcinoma.

(Choices A and C) Chronic cholestatic processes (eg, primary biliary cirrhosis, primary sclerosing cholangitis) may present initially with prolonged pruritus and fatigue. As these conditions progress, patients can develop acholic stools and malabsorption of fat-soluble vitamins (due to reduced bile flow to the small intestine). This can lead to vitamin D deficiency and metabolic bone disease (eg, osteoporosis, osteomalacia).

(Choice D) Skin pigmentation and diabetes mellitus are more suggestive of hemochromatosis, an inherited disease associated with iron overload in the liver, pancreas, heart, and other organs.

(Choice E) Upper gastrointestinal bleeding and ascites are more suggestive of portal hypertension, a condition that typically develops secondary to liver cirrhosis.

Educational objective:
Acute hepatitis A is a self-limited infection that typically presents acutely with prodromal symptoms (eg, fever, malaise, anorexia, nausea/vomiting, right upper quadrant pain) followed by signs of cholestasis (eg, jaundice, pruritus, dark-colored urine, clay-colored stool).

References

- Pathology of acute hepatitis A in humans. Comparison with acute hepatitis B.
- Hepatitis A.

Pathology	Gastrointestinal & Nutrition	Hepatitis a
Subject	System	Topic

Settings

9
10
11
12
13
14
15
16
17
18
19
20
21
22
23
24
25
26
27
28
29
30
31
32
33
34
35
36
37
38

Item 30 of 38
Question Id: 366

Mark | Previous | Next | Full Screen | Tutorial | Lab Values | Notes | Calculator | Reverse Color | Text Zoom | Settings

This patient's liver biopsy findings and recent travel to an endemic region suggest **acute hepatitis A infection**. Acute viral hepatitis is

Exhibit Display

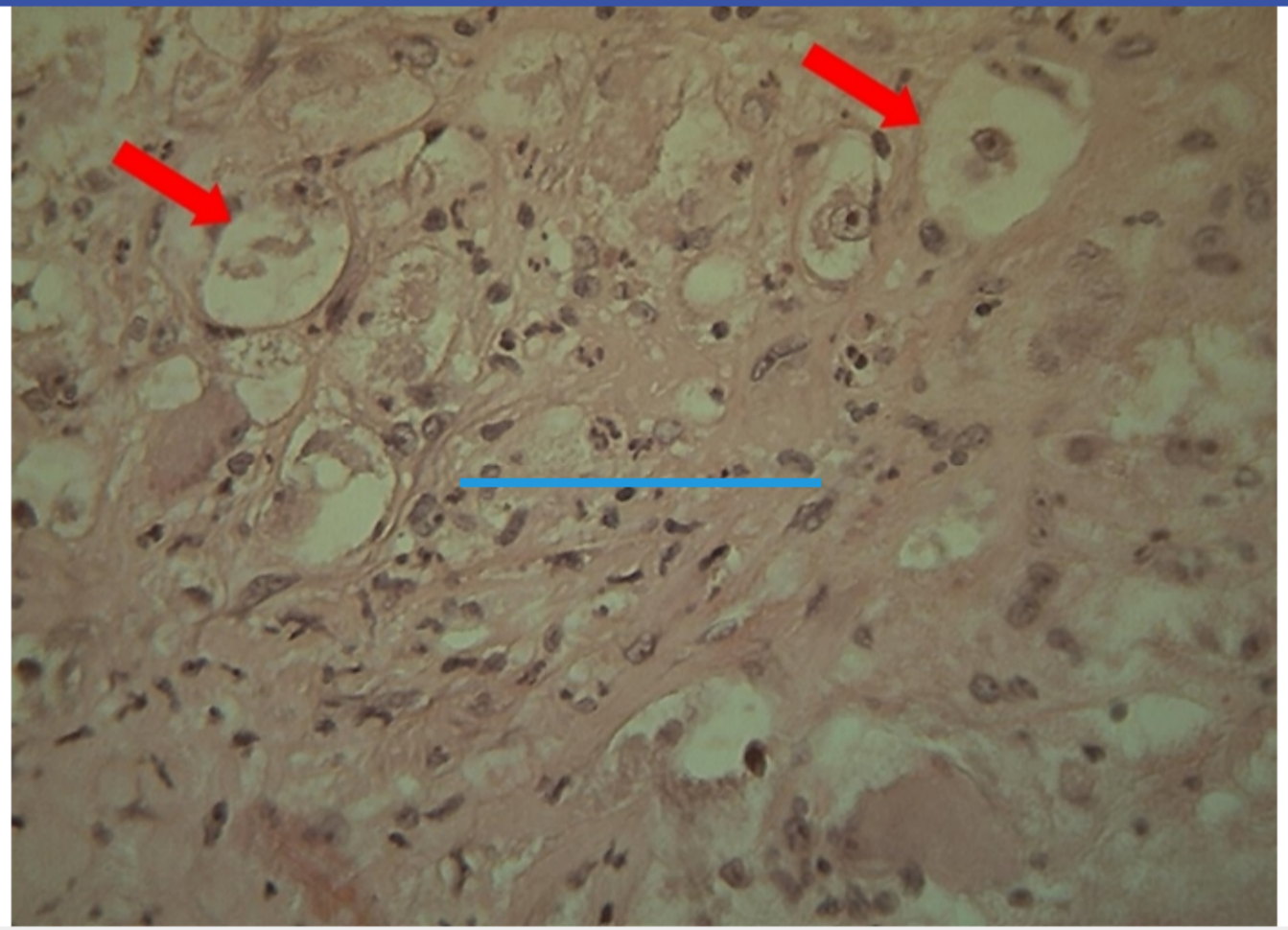

Zoom In | Zoom Out | Reset | Add To New Card | Existing Card

Block Time Remaining: 00:01:02
TUTOR

5 | Feedback | Suspend | End Block

Settings

9
10
11
12
13
14
15
16
17
18
19
20
21
22
23
24
25
26
27
28
29
30
31
32
33
34
35
36
37
38

Item 30 of 38
Question Id: 366

Mark | Previous | Next | Full Screen | Tutorial | Lab Values | Notes | Calculator | Reverse Color | Text Zoom | Settings

This patient's liver biopsy findings and recent travel to an endemic region suggest **acute hepatitis A infection**. Acute viral hepatitis is

Exhibit Display

Acute hepatitis Acute hepatitis

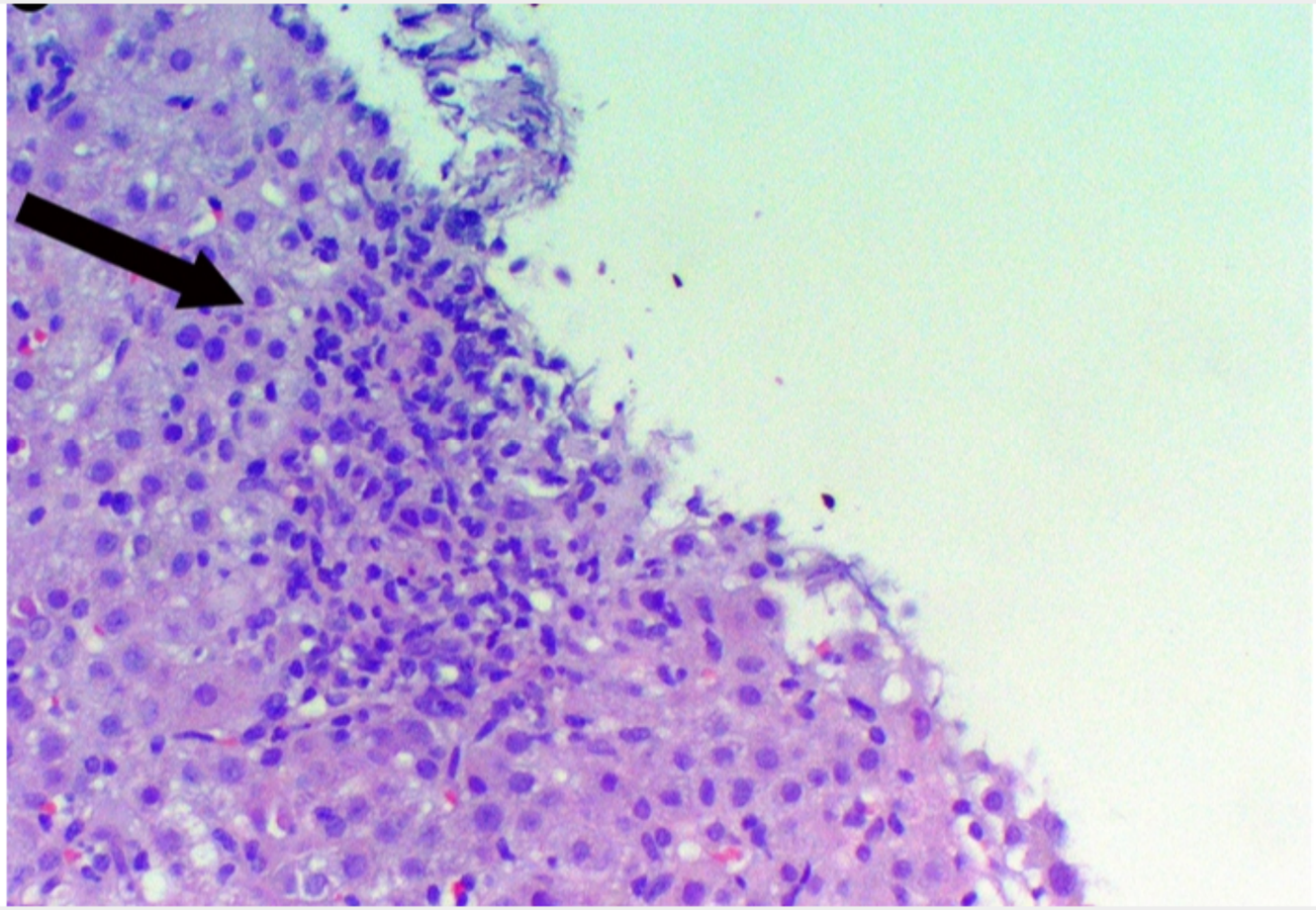

Zoom In | Zoom Out | Reset | Add To New Card | Existing Card

Block Time Remaining: 00:01:02
TUTOR

5 | Feedback | Suspend | End Block

Settings

9
10
11
12
13
14
15
16
17
18
19
20
21
22
23
24
25
26
27
28
29
30
31
32
33
34
35
36
37
38

Item 30 of 38
Question Id: 366

Mark | Previous | Next | Full Screen | Tutorial | Lab Values | Notes | Calculator | Reverse Color | Text Zoom | Settings

This patient's liver biopsy findings and recent travel to an endemic region suggest **acute hepatitis A infection**. Acute viral hepatitis is

Exhibit Display

Acute hepatitis Acute hepatitis

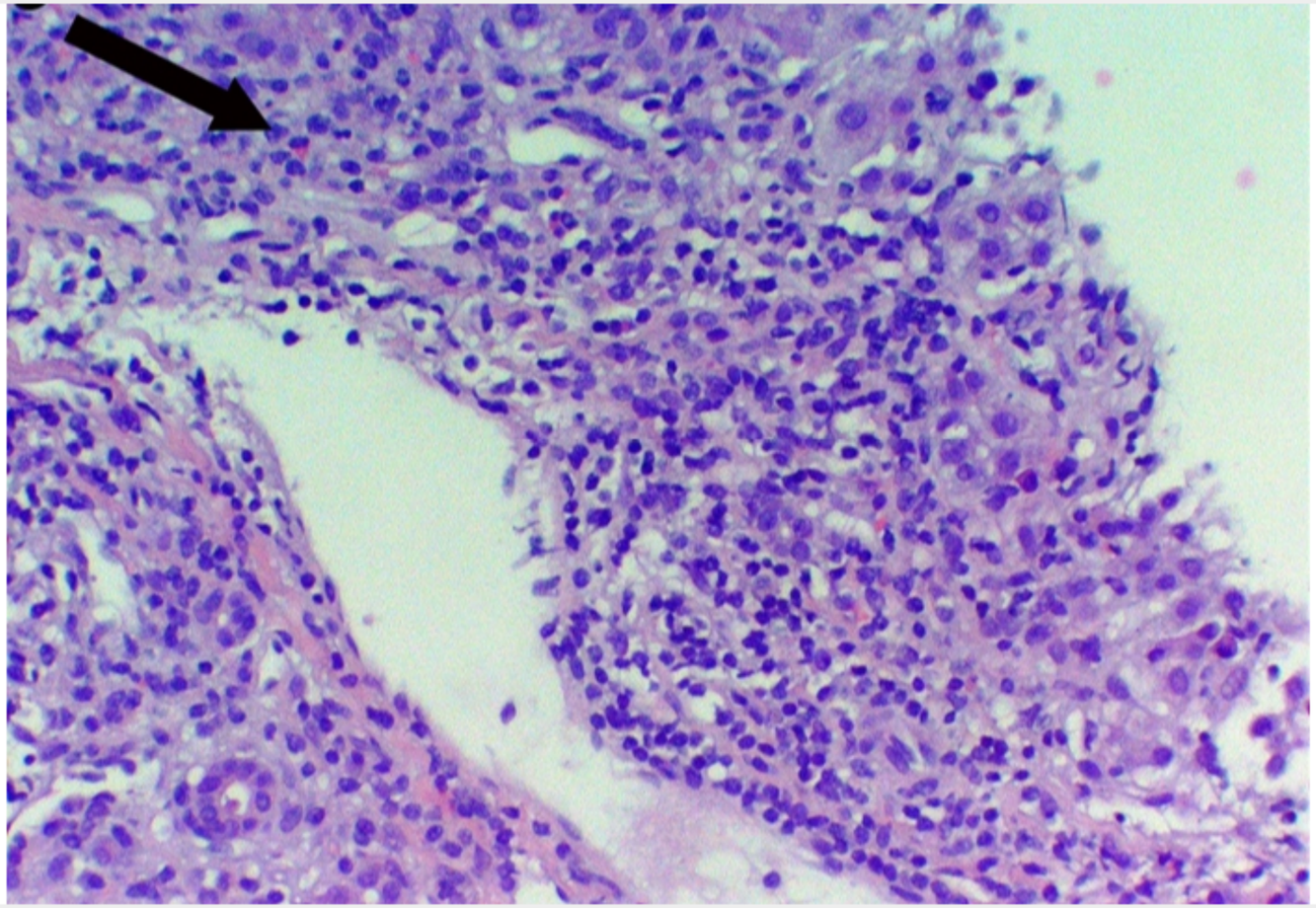

Zoom In | Zoom Out | Reset | Add To New Card | Existing Card

Block Time Remaining: 00:01:02
TUTOR

5 | Feedback | Suspend | End Block

Settings

9
10
11
12
13
14
15
16
17
18
19
20
21
22
23
24
25
26
27
28
29
30
31
32
33
34
35
36
37
38

Item 31 of 38
Question Id: 281

Mark | Previous | Next | Full Screen | Tutorial | Lab Values | Notes | Calculator | Reverse Color | Text Zoom | Settings

A 35-year-old alcoholic male is brought to the ER with hematemesis. Prior to this, he has had three episodes of vomiting. His BP is 110/80 mmHg and pulse is 98/min. He has no jaundice. Lungs are clear to auscultation. Abdomen is soft, non tender, and non-distended. There is no hepatomegaly. Endoscopy shows longitudinal mucosal tears at the gastroesophageal junction. This patient's condition is most likely related to which of the following?

A. Intraabdominal pressure

B. Venous pressure

C. Local inflammation

D. Acid reflux

E. Mucosal ischemia

Submit

Block Time Remaining: 00:01:02
TUTOR

2 | Feedback | Suspend | End Block

9, 10, 11, 12, 13, 14, 15, 16, 17, 18, 19, 20, 21, 22, 23, 24, 25, 26, 27, 28, 29, 30, 31, 32, 33, 34, 35, 36, 37, 38

A 35-year-old alcoholic male is brought to the ER with hematemesis. Prior to this, he has had three episodes of vomiting. His BP is 110/80 mmHg and pulse is 98/min. He has no jaundice. Lungs are clear to auscultation. Abdomen is soft, non tender, and non-distended. There is no hepatomegaly. Endoscopy shows longitudinal mucosal tears at the gastroesophageal junction. This patient's condition is most likely related to which of the following?

- ✓ A. Intraabdominal pressure (60%)
- B. Venous pressure (11%)
- C. Local inflammation (4%)
- D. Acid reflux (19%)
- E. Mucosal ischemia (3%)

Omitted
Correct answer
A

60%
Answered correctly

01 sec
Time Spent

02/03/2020
Last Updated

Explanation

Longitudinal mucosal tears at the esophagogastric-squamocolumnar junction describe Mallory-Weiss syndrome. Most commonly, these tears occur secondary to rapid increase of intraabdominal and intraluminal gastric pressure, as when happens during retching and vomiting. Other precipitating factors include coughing, hiccupping, other repeated abdominal straining, and abdominal trauma. Additionally, hiatal hernias are found in about half of patients with Mallory-Weiss syndrome and are considered a strong predisposing factor. Mallory-Weiss syndrome is very commonly associated with alcoholism

9
10
11
12
13
14
15
16
17
18
19
20
21
22
23
24
25
26
27
28
29
30
31
32
33
34
35
36
37
38

Longitudinal mucosal tears at the esophagogastric-squamocolumnar junction describe Mallory-Weiss syndrome. Most commonly, these tears occur secondary to rapid increase of intraabdominal and intraluminal gastric pressure, as when happens during retching and vomiting. Other precipitating factors include coughing, hiccupping, other repeated abdominal straining, and abdominal trauma. Additionally, hiatal hernias are found in about half of patients with Mallory-Weiss syndrome and are considered a strong predisposing factor. Mallory-Weiss syndrome is very commonly associated with alcoholism.

Mallory-Weiss tears can be asymptomatic or can lead to gastrointestinal hemorrhage that manifests as hematemesis. About 10% of all upper gastrointestinal bleeds are from Mallory-Weiss syndrome. The intensity of hemorrhage and amount of blood loss varies widely according to the length and depth of the tears, but is almost never life-threatening.

(Choice B) Increased venous pressure is associated with potentially life-threatening hemorrhage from esophageal varices. Esophageal varices occur in patients with cirrhosis who often have other symptoms of chronic liver disease−such as jaundice, spider nevi, palmar erythema, gynecomastia, and a history of alcohol abuse. Endoscopy is diagnostic.

(Choices C and D) Local inflammation plays a role in the development of chronic gastritis and esophagitis. Acid reflux is characteristic of gastrointestinal reflux disease (GERD). Neither condition is known for significant upper GI bleeding.

(Choice E) Diminished blood perfusion to the small bowel and colon may result from arterial occlusion by embolus, thrombosis of the venous system, or low cardiac output. Ischemic bowel is the result, and it is a very dangerous condition. Ischemic bowel occurs most often in older patients.

Educational Objective:
Mallory-Weiss tears account for about 10% of cases of upper GI hemorrhage. They occur due to increased intraluminal gastric pressure due to retching, vomiting, or other abdominal straining.

Pathology	Gastrointestinal & Nutrition	Mallory-weiss syndrome
Subject	System	Topic

Copyright © UWorld. All rights reserved.

9
10
11
12
13
14
15
16
17
18
19
20
21
22
23
24
25
26
27
28
29
30
31
32
33
34
35
36
37
38

A 58-year-old man with a history of chronic liver disease due to hepatitis C infection comes to the office due to progressive fatigue and abdominal discomfort. He has no other medical conditions, and a recent colonoscopy was normal. Physical examination shows ascites and jaundice. Ultrasonography of the abdomen reveals a solid mass within the liver parenchyma. Surgical resection of the liver lesion is performed. Histopathology reveals large pleomorphic cells with prominent nucleoli and surrounding dense, fibrous bands as shown below.

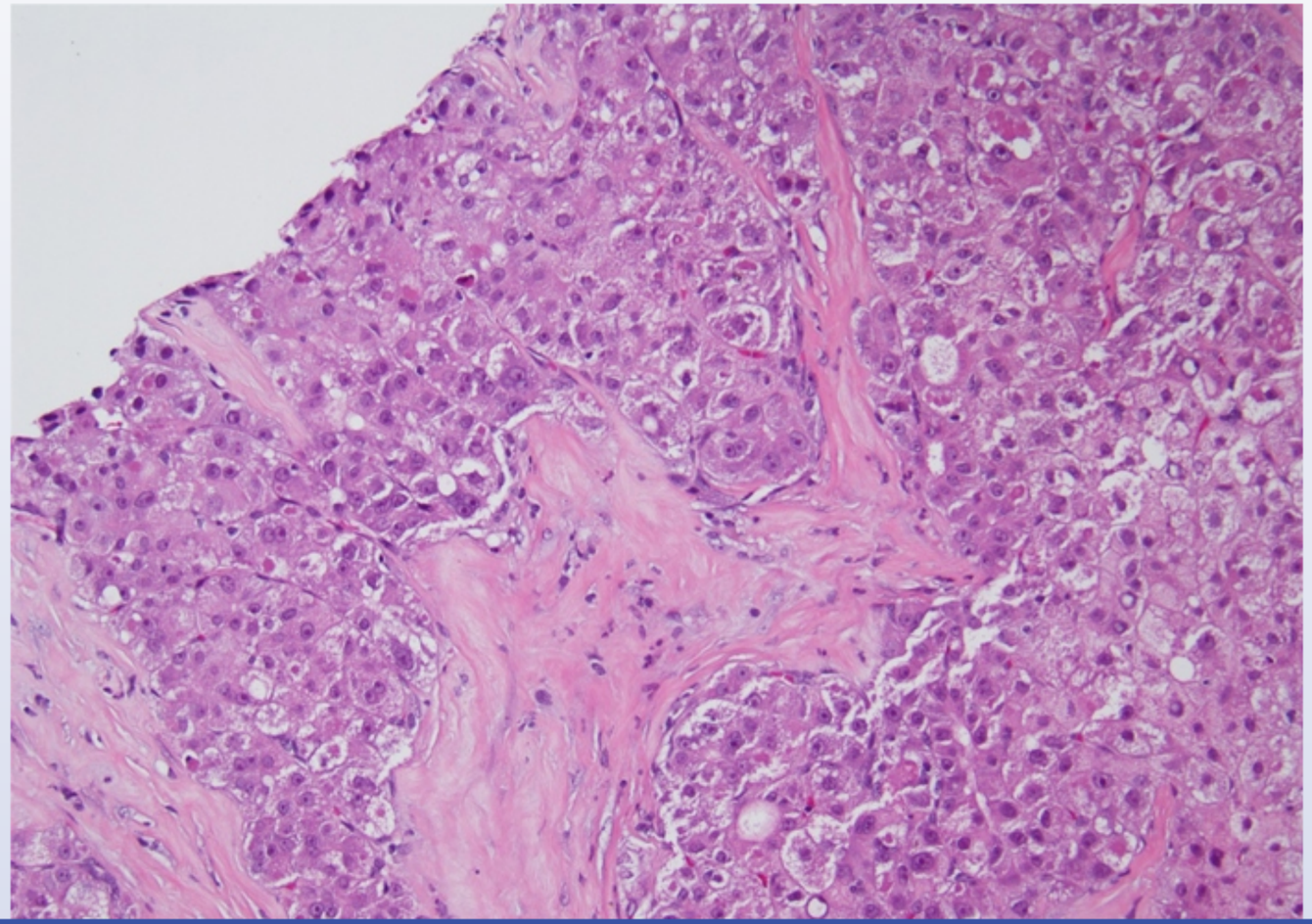

9
10
11
12
13
14
15
16
17
18
19
20
21
22
23
24
25
26
27
28
29
30
31
32
33
34
35
36
37
38

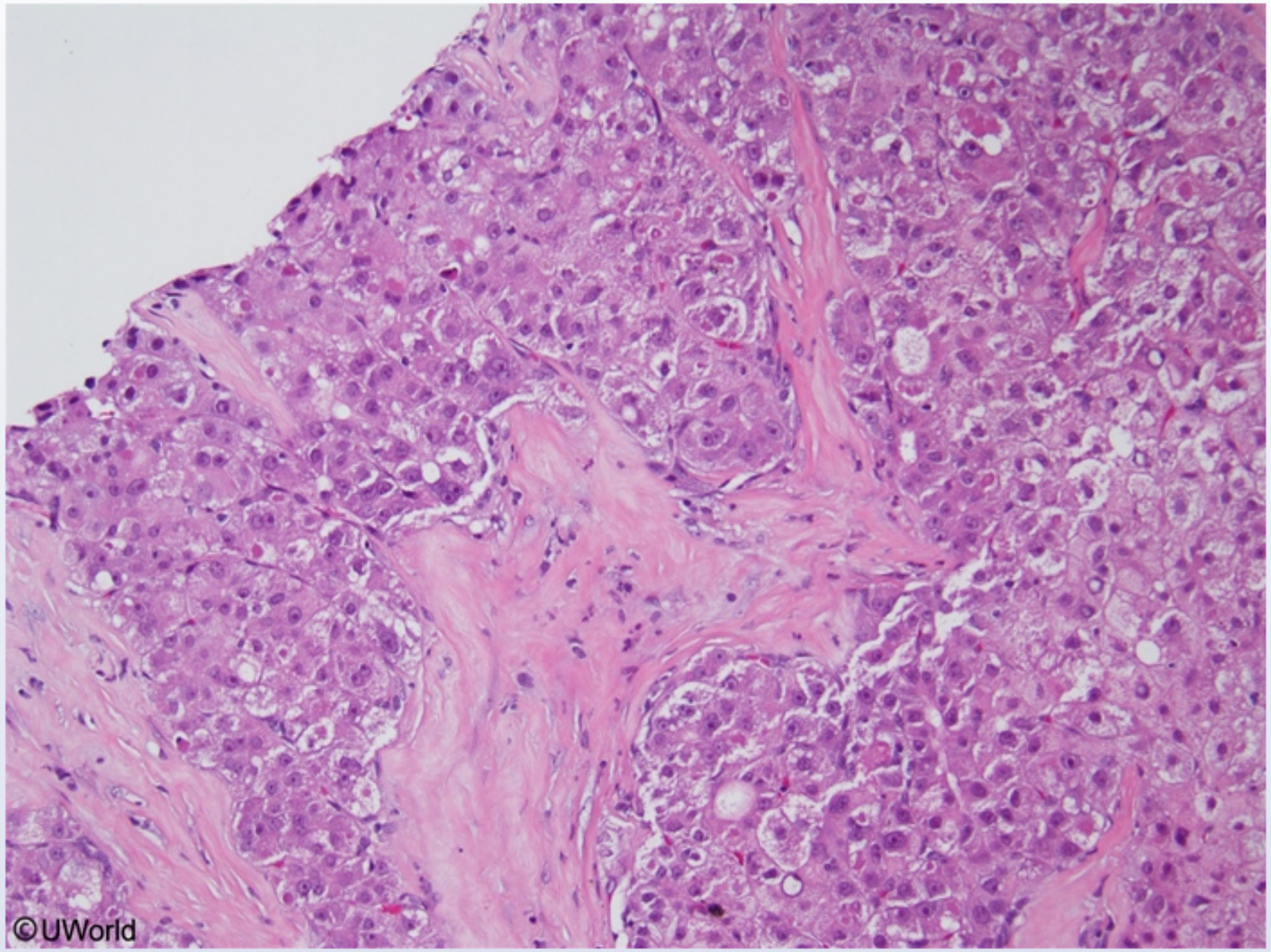

Which of the following serum markers would be the most useful for monitoring this patient for disease recurrence?

A. 5-Hydroxyindoleacetic acid

9
10
11
12
13
14
15
16
17
18
19
20
21
22
23
24
25
26
27
28
29
30
31
32
33
34
35
36
37
38

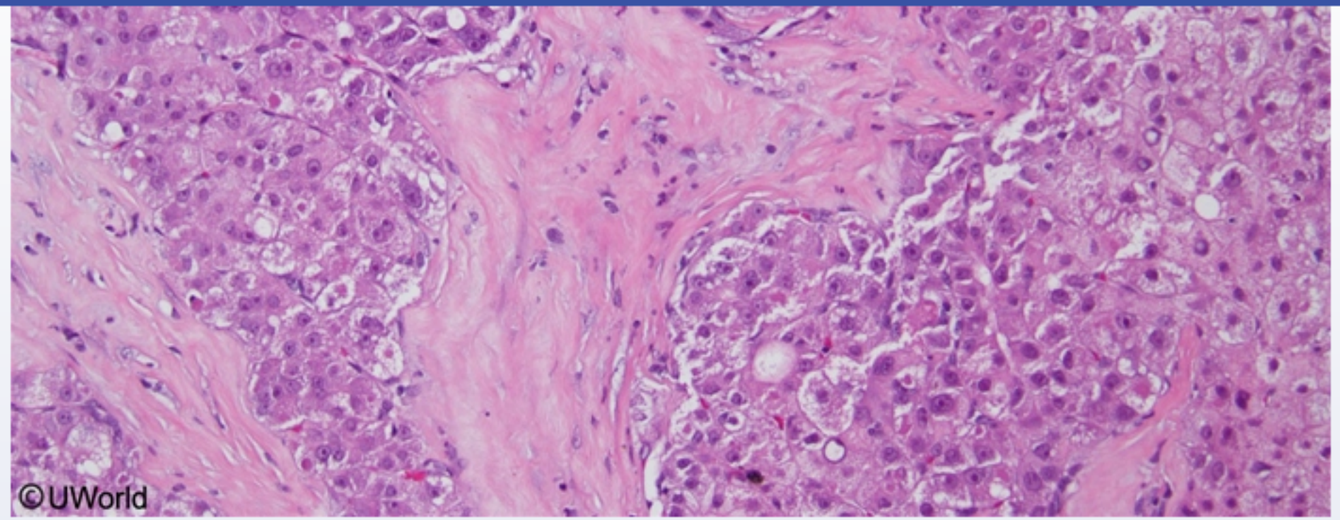

Which of the following serum markers would be the most useful for monitoring this patient for disease recurrence?

- A. 5-Hydroxyindoleacetic acid
- B. Alpha-fetoprotein
- C. CA 125
- D. CA 19-9
- E. Carcinoembryonic antigen
- F. Human chorionic gonadotropin

Submit

9
10
11
12
13
14
15
16
17
18
19
20
21
22
23
24
25
26
27
28
29
30
31
32
33
34
35
36
37
38

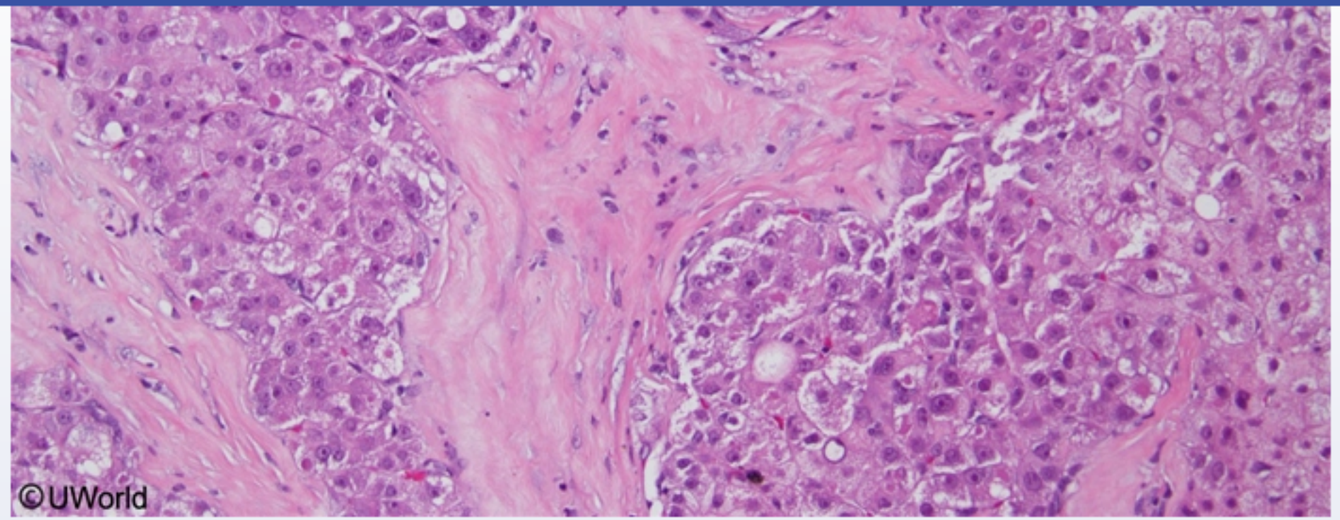

Which of the following serum markers would be the most useful for monitoring this patient for disease recurrence?

- A. 5-Hydroxyindoleacetic acid (2%)
- ✓ B. Alpha-fetoprotein (74%)
- C. CA 125 (5%)
- D. CA 19-9 (4%)
- E. Carcinoembryonic antigen (12%)
- F. Human chorionic gonadotropin (0%)

Omitted
Correct answer

74%
Answered correctly

07 secs
Time Spent

01/11/2020
Last Updated

9
10
11
12
13
14
15
16
17
18
19
20
21
22
23
24
25
26
27
28
29
30
31
32
33
34
35
36
37
38

Explanation

Common serum tumor markers	
Marker	**Tumor associations**
Alpha-fetoprotein	• Hepatocellular carcinoma • Germ cell
CA 19-9	• Pancreatic
CA 125	• Ovarian
Carcinoembryonic antigen	• Gastrointestinal (eg, colorectal)
Human chorionic gonadotropin	• Choriocarcinoma • Germ cell
Prostate-specific antigen	• Prostate

Hepatocellular carcinoma (HCC) occurs in up to 25% of patients with chronic **hepatitis C virus** (HCV). HCV increases hepatocyte turnover and generates local proinflammatory cytokines, which causes hepatocyte damage and fibrosis. Over time, damaged hepatocytes can proliferate into dysplastic nodules and undergo malignant transformation into HCC.

Suspicion for HCC is often raised when patients with chronic HCV develop worsened underlying cirrhotic symptoms such as fatigue, ascites, variceal bleeding, abdominal discomfort, or jaundice. Abdominal imaging will show a liver mass; biopsy usually reveals significant **hepatic fibrosis** with clusters of malignant cells (eg, pleomorphic, prominent nucleoli, high nuclear-to-cytoplasmic ratio).

Serum **alpha-fetoprotein** (AFP) **level** is often used to aid diagnosis and screen for disease recurrence following treatment. AFP is a glycoprotein produced by the fetal liver and yolk sac during gestation. Although levels of AFP are often mildly or moderately elevated in patients with chronic

9
10
11
12
13
14
15
16
17
18
19
20
21
22
23
24
25
26
27
28
29
30
31
32
33
34
35
36
37
38

Hepatocellular carcinoma (HCC) occurs in up to 25% of patients with chronic **hepatitis C virus** (HCV). HCV increases hepatocyte turnover and generates local proinflammatory cytokines, which causes hepatocyte damage and fibrosis. Over time, damaged hepatocytes can proliferate into dysplastic nodules and undergo malignant transformation into HCC.

Suspicion for HCC is often raised when patients with chronic HCV develop worsened underlying cirrhotic symptoms such as fatigue, ascites, variceal bleeding, abdominal discomfort, or jaundice. Abdominal imaging will show a liver mass; biopsy usually reveals significant **hepatic fibrosis** with clusters of malignant cells (eg, pleomorphic, prominent nucleoli, high nuclear-to-cytoplasmic ratio).

Serum **alpha-fetoprotein** (AFP) **level** is often used to aid diagnosis and screen for disease recurrence following treatment. AFP is a glycoprotein produced by the fetal liver and yolk sac during gestation. Although levels of AFP are often mildly or moderately elevated in patients with chronic liver disease, **dramatic elevations** or **sudden rises** in AFP should prompt an investigation for HCC. AFP levels do not correlate with the size or stage of the tumor and are not elevated in all cases of HCC.

(Choice A) 5-Hydroxyindoleacetic acid is the major breakdown product of serotonin. Elevated urine levels are seen in carcinoid tumors and certain neuroendocrine tumors.

(Choice C) CA 125 is a serum marker associated with ovarian cancer. It may also be elevated in other malignancies (eg, endometrial) and certain benign conditions (eg, endometriosis).

(Choice D) CA 19-9 is primarily used as a marker for pancreatic cancer or other tumors of the biliary tract.

(Choice E) Carcinoembryonic antigen is a serum marker that is primarily used to monitor response to treatment in patients with colorectal cancer. This patient's clinical features (ie, chronic hepatitis C, negative colonoscopy) are consistent with HCC rather than colorectal cancer.

(Choice F) Human chorionic gonadotropin is elevated in choriocarcinoma and may also be elevated in germ cell tumors (eg, testicular). However, it is most commonly used as a marker for pregnancy.

Educational objective:
Alpha-fetoprotein is a serum tumor marker that is often moderately elevated in patients with chronic viral hepatitis. However, it can be strikingly elevated in those with hepatocellular carcinoma, and a sudden rise can be a sign that a patient with chronic liver disease is harboring hepatocellular carcinoma.

Settings

Item 32 of 38
Question Id: 56

Mark | Previous | Next | Full Screen | Tutorial | Lab Values | Notes | Calculator | Reverse Color | Text Zoom | Settings

Exhibit Display

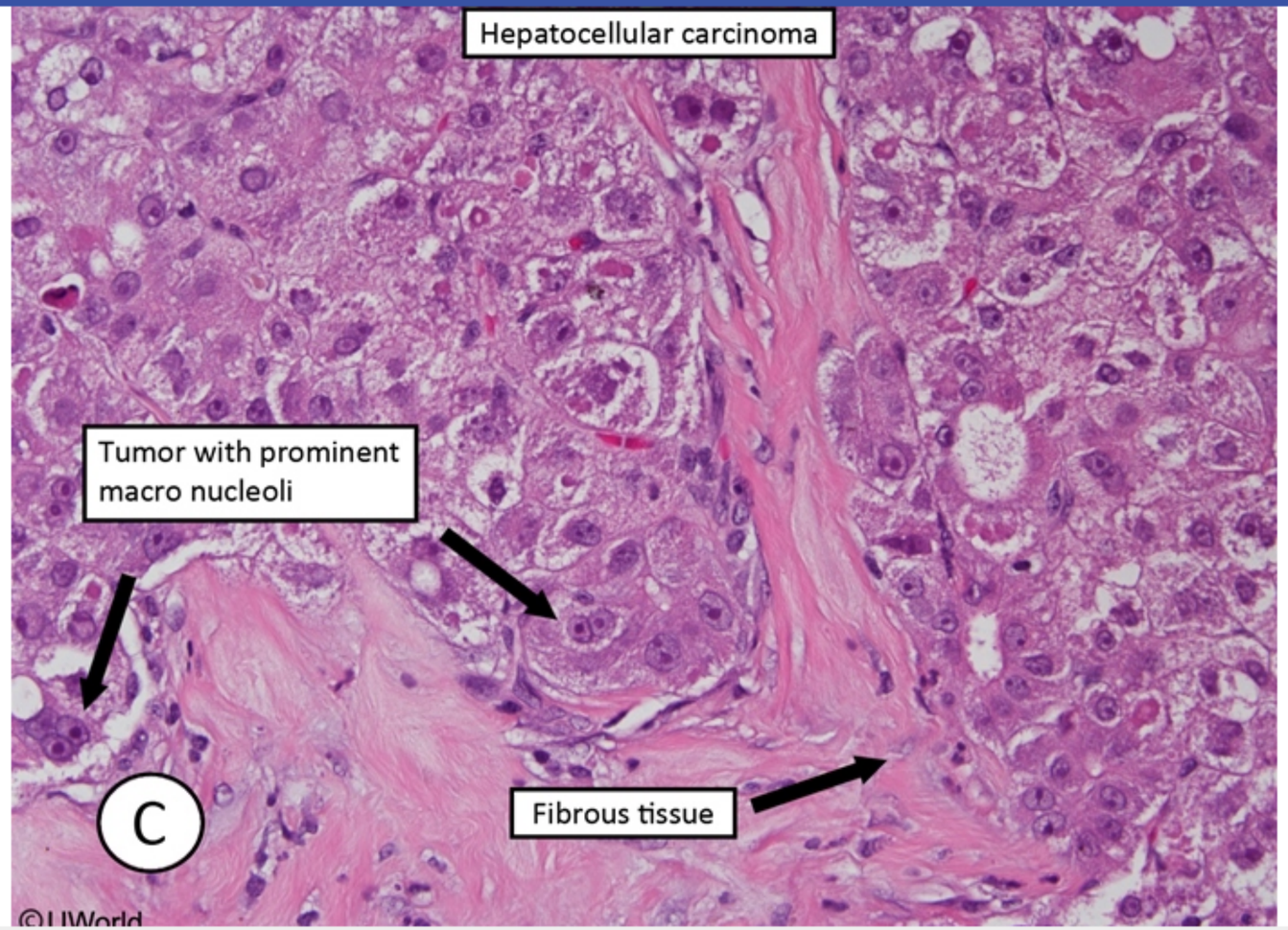

Zoom In | Zoom Out | Reset | Add To New Card | Existing Card

hepatocellular carcinoma

Block Time Remaining: 00:01:11
TUTOR

Feedback | Suspend | End Block

Settings

9
10
11
12
13
14
15
16
17
18
19
20
21
22
23
24
25
26
27
28
29
30
31
32
33
34
35
36
37
38

Item 33 of 38
Question Id: 131

Mark | Previous | Next | Full Screen | Tutorial | Lab Values | Notes | Calculator | Reverse Color | Text Zoom | Settings

A 45-year-old Caucasian male presents to your office with a two year history of abdominal discomfort, greasy stool and weight loss. He has been treated for joint pain with ibuprofen. After initial work-up, an intestinal biopsy shows multiple macrophages loaded with PAS-positive granules in the lamina propria. This patient should be treated with:

A. Enzyme supplementation
B. Antibiotics
C. Special diet
D. Parenteral nutrition
E. Aminosalicylic acid derivates
F. Surgical resection

Submit

Block Time Remaining: 00:01:12
TUTOR

2 | Feedback | Suspend | End Block

9
10
11
12
13
14
15
16
17
18
19
20
21
22
23
24
25
26
27
28
29
30
31
32
33
34
35
36
37
38

A 45-year-old Caucasian male presents to your office with a two year history of abdominal discomfort, greasy stool and weight loss. He has been treated for joint pain with ibuprofen. After initial work-up, an intestinal biopsy shows multiple macrophages loaded with PAS-positive granules in the lamina propria. This patient should be treated with:

- A. Enzyme supplementation (7%)
- ✓ B. Antibiotics (64%)
- C. Special diet (16%)
- D. Parenteral nutrition (1%)
- E. Aminosalicylic acid derivates (5%)
- F. Surgical resection (4%)

Omitted
Correct answer
B

64%
Answered correctly

02 secs
Time Spent

02/03/2020
Last Updated

Explanation

Caused by the gram-positive actinomycete *Tropheryma whippelii*, Whipple disease is a rare systemic illness that involves the small intestine, joints, and central nervous system. The actinomycete proliferates only within the macrophages of these tissues, provoking no inflammatory response as a consequence. Classic histologic findings include small intestine mucosa containing enlarged, foamy macrophages packed with both rod-shaped bacilli and PAS-positive, diastase-resistant granules (which consist of lysosomes and partially digested bacteria).

9
10
11
12
13
14
15
16
17
18
19
20
21
22
23
24
25
26
27
28
29
30
31
32
33
34
35
36
37
38

Explanation

Caused by the gram-positive actinomycete *Tropheryma whippelii,* Whipple disease is a rare systemic illness that involves the small intestine, joints, and central nervous system. The actinomycete proliferates only within the macrophages of these tissues, provoking no inflammatory response as a consequence. Classic histologic findings include small intestine mucosa containing enlarged, foamy macrophages packed with both rod-shaped bacilli and PAS-positive, diastase-resistant granules (which consist of lysosomes and partially digested bacteria).

Clinically, Whipple disease is most commonly seen in middle-aged Caucasian males, presenting as malabsorption with diarrhea and weight loss. Arthropathy, polyarthritis, and psychiatric and cardiac abnormalities may also be observed. Antibiotic therapy is usually successful in quickly resolving the illness.

(Choice A) Digestive enzyme supplementation is appropriate for patients with diminished exocrine pancreatic function.

(Choice C) A special diet is appropriate for patients with celiac sprue or other food-sensitive conditions.

(Choice D) Parenteral nutrition is appropriate for all patients in need of prolonged bowel rest, such as those suffering from acute pancreatitis.

(Choice E) Aminosalicylic acid derivates are appropriate in treating ulcerative colitis.

(Choice F) Surgery is appropriate for patients with bowel conditions not responsive to medical treatment (eg, severe diverticulitis, ischemic bowel).

Educational Objective:
Caused by the gram-positive actinomycete *Tropheryma whippelii,* Whipple disease is a rare systemic illness that involves the small intestine, joints, and central nervous system. Classic histologic findings include small intestine mucosa containing enlarged, foamy macrophages packed with both rod-shaped bacilli and PAS-positive, diastase-resistant granules.

Pathology	Gastrointestinal & Nutrition	Whipple disease
Subject	System	Topic

Copyright © UWorld. All rights reserved.

A 2-year-old girl is brought to the emergency department with intermittent pain in the abdomen that began several hours ago. The patient also had a bowel movement that appeared tinged with blood. Ultrasound shows an area along the ileum in which the proximal small intestine is telescoped into the distal small intestine. Reduction via enema is unsuccessful, and the patient undergoes laparotomy with resultant resection of the involved intestine. The pathologic finding at the lead point is shown in the following image:

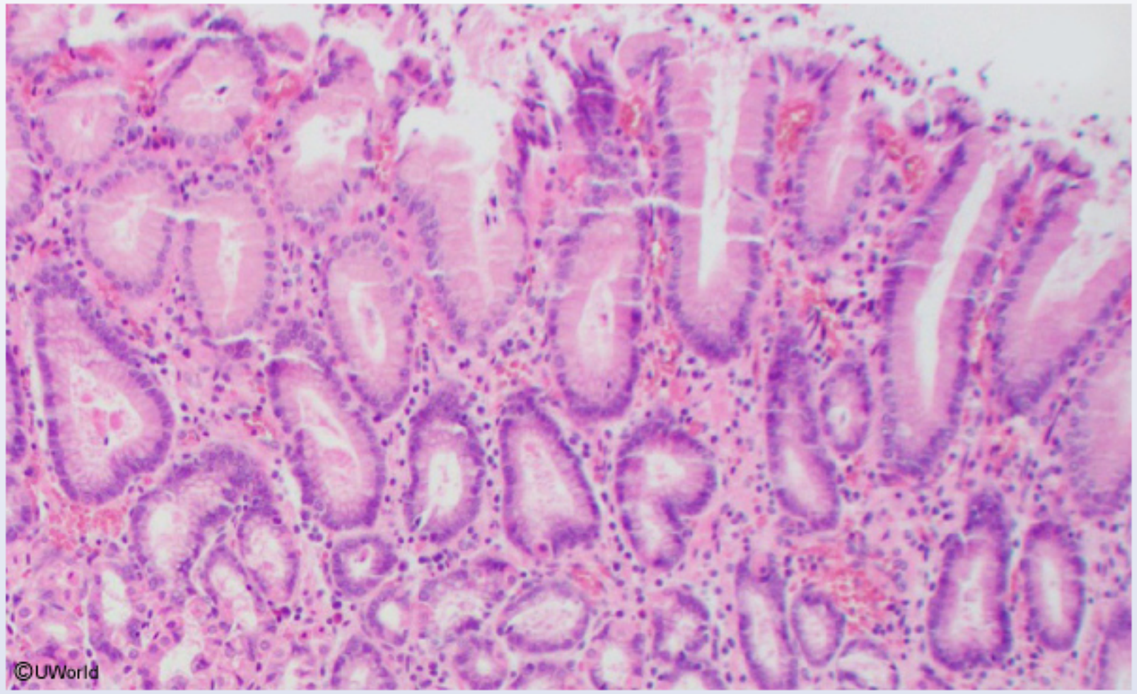

Which of the following is the most likely underlying diagnosis in this patient?

- A. Burkitt lymphoma
- B. Henoch-Schönlein purpura
- C. Inflammatory bowel disease

Settings

9
10
11
12
13
14
15
16
17
18
19
20
21
22
23
24
25
26
27
28
29
30
31
32
33
34
35
36
37
38

Item 34 of 38
Question Id: 19295

Mark | Previous | Next | Full Screen | Tutorial | Lab Values | Notes | Calculator | Reverse Color | Text Zoom | Settings

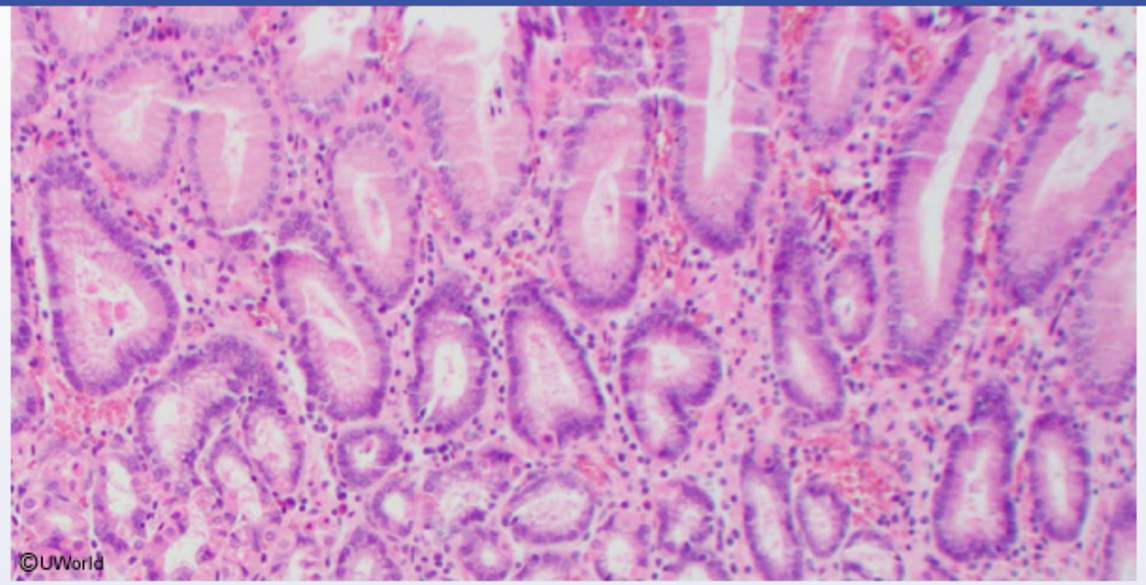

Which of the following is the most likely underlying diagnosis in this patient?

A. Burkitt lymphoma
B. Henoch-Schönlein purpura
C. Inflammatory bowel disease
D. Meckel diverticulum
E. Pseudomembranous colitis

Submit

Block Time Remaining: 00:01:16
TUTOR

0 | Feedback | Suspend | End Block

9
10
11
12
13
14
15
16
17
18
19
20
21
22
23
24
25
26
27
28
29
30
31
32
33
34
35
36
37
38

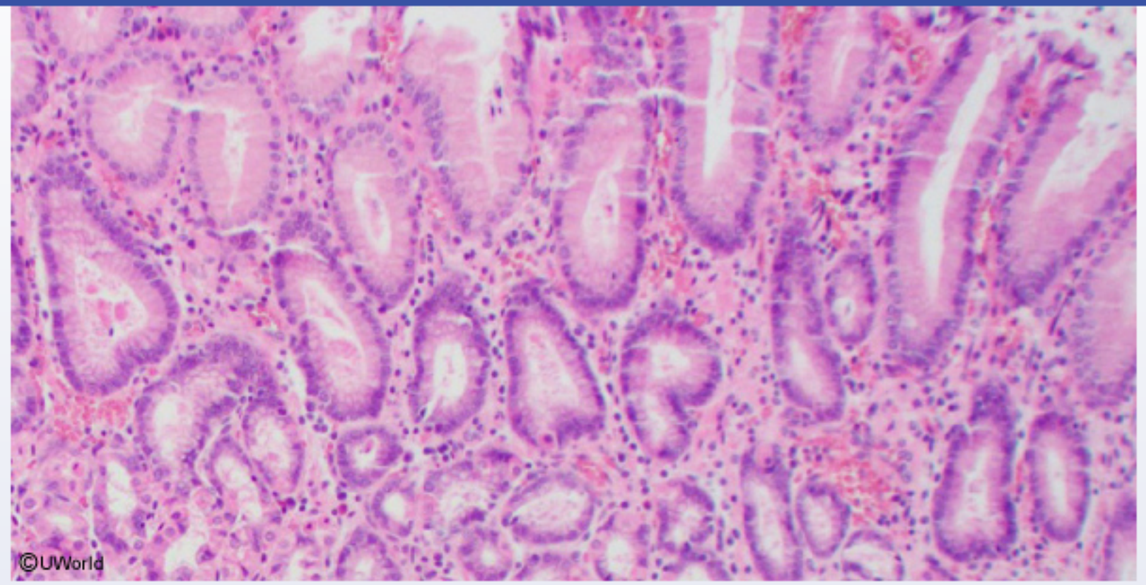

Which of the following is the most likely underlying diagnosis in this patient?

- A. Burkitt lymphoma (3%)
- B. Henoch-Schönlein purpura (12%)
- C. Inflammatory bowel disease (11%)
- ✓ D. Meckel diverticulum (67%)
- E. Pseudomembranous colitis (4%)

Omitted
Correct answer

67%
Answered correctly

04 secs
Time Spent

06/22/2020
Last Updated

9
10
11
12
13
14
15
16
17
18
19
20
21
22
23
24
25
26
27
28
29
30
31
32
33
34
35
36
37
38

Explanation

Normal gastric mucosa

©UWorld

Intussusception occurs when a proximal segment of intestine telescopes into a distal segment, causing episodes of severe abdominal pain. Progressive intestinal obstruction can also lead to bowel wall ischemia and bloody, currant jelly stools. Most cases are idiopathic in young children; however, 25% have a **pathologic lead point** for bowel invagination. The lead point is generally an anatomic abnormality (eg, polyp, mass) within the intestinal lumen that is entrapped during peristalsis and forced into distal bowel.

Meckel diverticulum is the **most common** pathologic lead point for intussusception and is a congenital anomaly of the gastrointestinal (GI) tract

9
10
11
12
13
14
15
16
17
18
19
20
21
22
23
24
25
26
27
28
29
30
31
32
33
34
35
36
37
38

Intussusception occurs when a proximal segment of intestine telescopes into a distal segment, causing episodes of severe abdominal pain. Progressive intestinal obstruction can also lead to bowel wall ischemia and bloody, currant jelly stools. Most cases are idiopathic in young children; however, 25% have a **pathologic lead point** for bowel invagination. The lead point is generally an anatomic abnormality (eg, polyp, mass) within the intestinal lumen that is entrapped during peristalsis and forced into distal bowel.

Meckel diverticulum is the **most common** pathologic lead point for intussusception and is a congenital anomaly of the gastrointestinal (GI) tract caused by incomplete obliteration of the vitelline duct. Most Meckel diverticula are clinically silent; symptomatic diverticula often contain **ectopic gastric mucosa**, which ulcerates and causes painless lower GI bleeding. Patients can also have complications such as diverticulitis, bowel obstruction, perforation, and intussusception.

In some cases, Meckel diverticulum may be identified incidentally during laparotomy based on histologic evidence of gastric tissue within the small intestine. Distinct features of gastric mucosa include gastric glands and pits with chief cells and parietal cells. Meckel scan is a nuclear study that can be used to detect the presence of ectopic gastric mucosa and diagnose Meckel diverticulum.

(Choice A) Burkitt lymphoma can serve as a pathologic lead point for intussusception, but microscopy would show a lymphoid infiltrate in a starry sky pattern.

(Choice B) Intestinal edema and hemorrhage associated with Henoch-Schönlein purpura can trigger intussusception; however, leukocytoclastic vasculitis (perivascular neutrophils with fibrin deposits and nuclear debris) would be expected on microscopy.

(Choices C and E) Inflammatory bowel disease (eg, Crohn disease) and pseudomembranous colitis (ie, *Clostridioides difficile* infection) cause GI tract inflammation that could trigger intussusception, but the incidence is rare, particularly in a child age 2. In addition, microscopic findings of Crohn disease include transmural inflammation with noncaseating granulomas, and pseudomembranous colitis is characterized by pseudomembranes composed of fibrin, neutrophils, and acellular debris.

Educational objective:
Meckel diverticulum is the most common pathologic lead point for intussusception, a condition in which a portion of the intestine telescopes into itself. Meckel diverticula frequently contain ectopic gastric mucosa, which can aid in diagnosis.

References

Settings

9
10
11
12
13
14
15
16
17
18
19
20
21
22
23
24
25
26
27
28
29
30
31
32
33
34
35
36
37
38

Item 34 of 38
Question Id: 19295

Mark | Previous | Next | Full Screen | Tutorial | Lab Values | Notes | Calculator | Reverse Color | Text Zoom | Settings

Exhibit Display

Intussusception

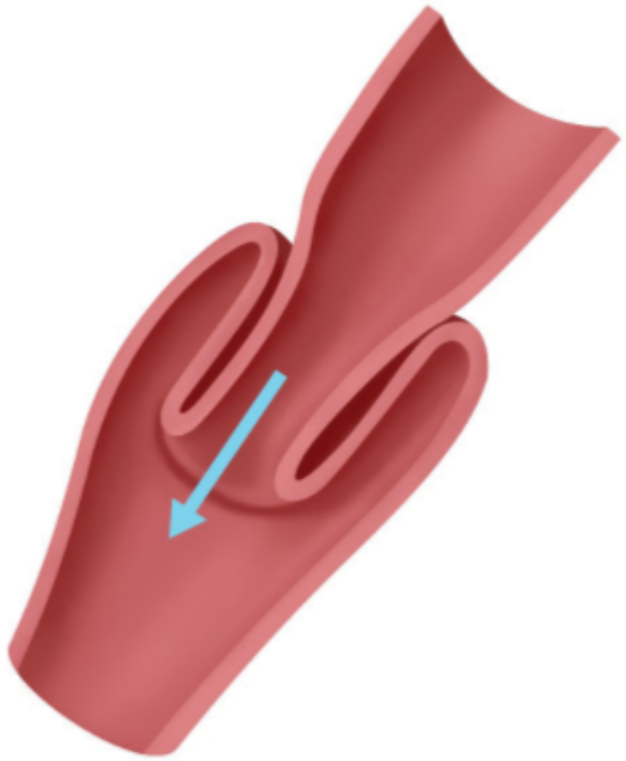

©UWorld

Zoom In | Zoom Out | Reset | Add To Flash Card

References

Block Time Remaining: 00:01:17
TUTOR

0 | Feedback | Suspend | End Block

Settings

9
10
11
12
13
14
15
16
17
18
19
20
21
22
23
24
25
26
27
28
29
30
31
32
33
34
35
36
37
38

Item 34 of 38
Question Id: 19295

Mark | Previous | Next | Full Screen | Tutorial | Lab Values | Notes | Calculator | Reverse Color | Text Zoom | Settings

Exhibit Display

Vitelline duct abnormalities

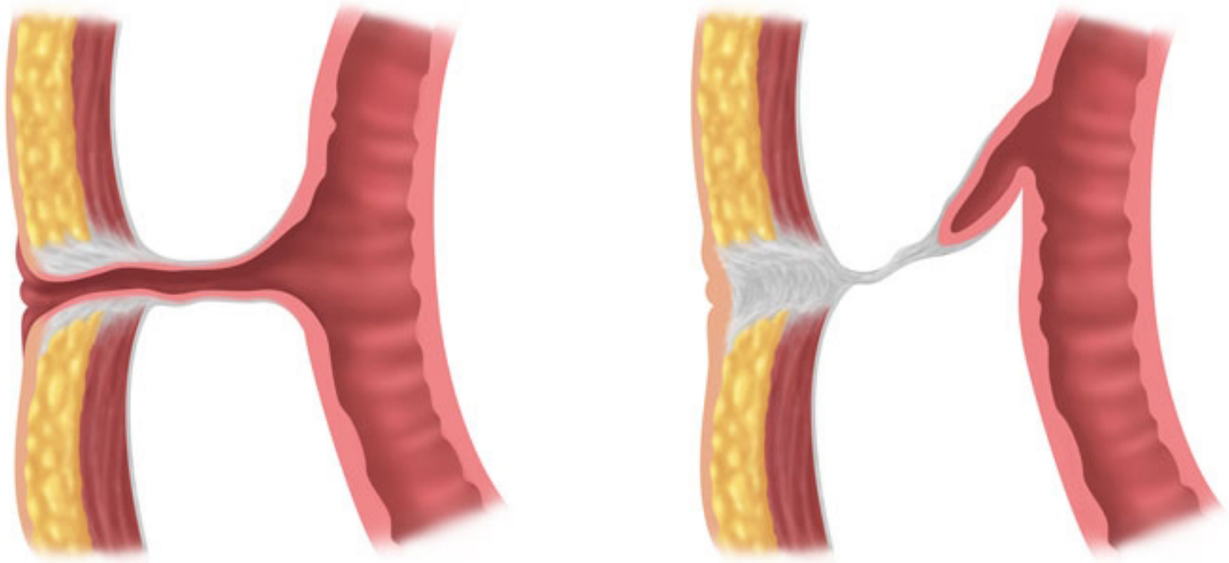

Persistent vitelline duct

Meckel diverticulum

©UWorld

Zoom In | Zoom Out | Reset | Add To Flash Card

References

Block Time Remaining: 00:01:17
TUTOR

0 | Feedback | Suspend | End Block

Settings

9
10
11
12
13
14
15
16
17
18
19
20
21
22
23
24
25
26
27
28
29
30
31
32
33
34
35
36
37
38

Item 34 of 38
Question Id: 19295

Mark | Previous | Next | Full Screen | Tutorial | Lab Values | Notes | Calculator | Reverse Color | Text Zoom | Settings

Exhibit Display

Normal gastric mucosa

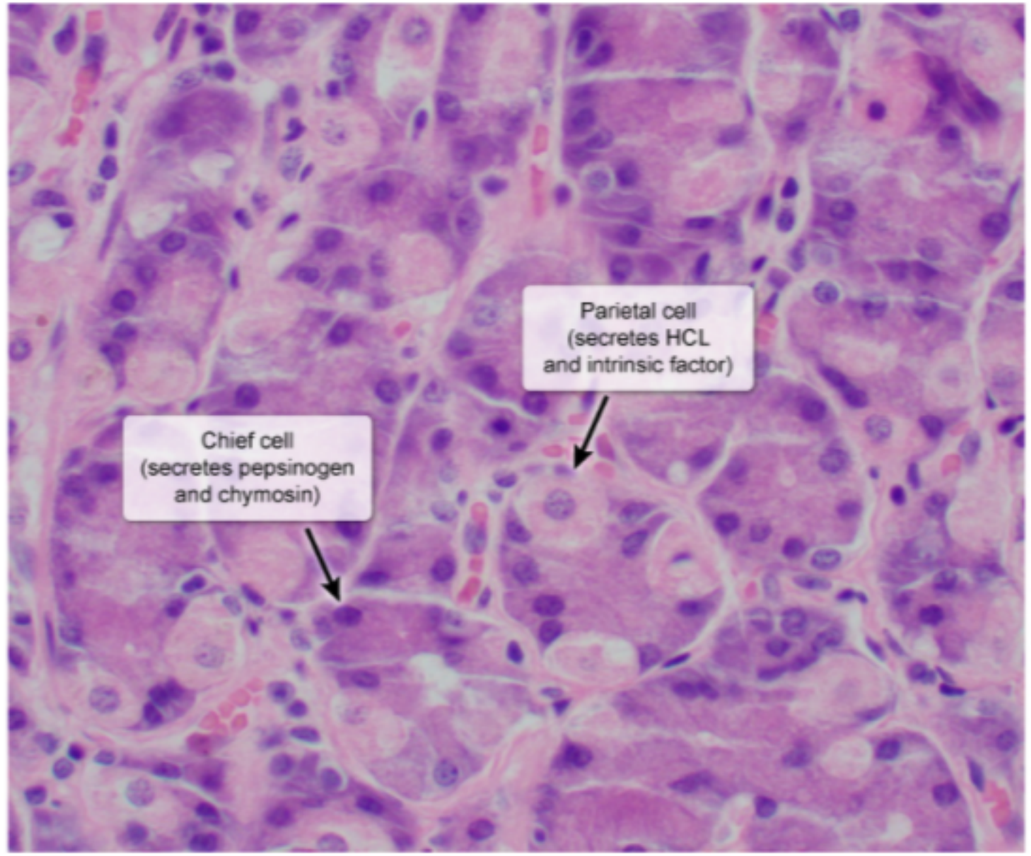

©UWorld

Zoom In | Zoom Out | Reset | Add To Flash Card

References

Block Time Remaining: 00:01:17
TUTOR

0 | Feedback | Suspend | End Block

9
10
11
12
13
14
15
16
17
18
19
20
21
22
23
24
25
26
27
28
29
30
31
32
33
34
35
36
37
38

Exhibit Display

Burkitt lymphoma

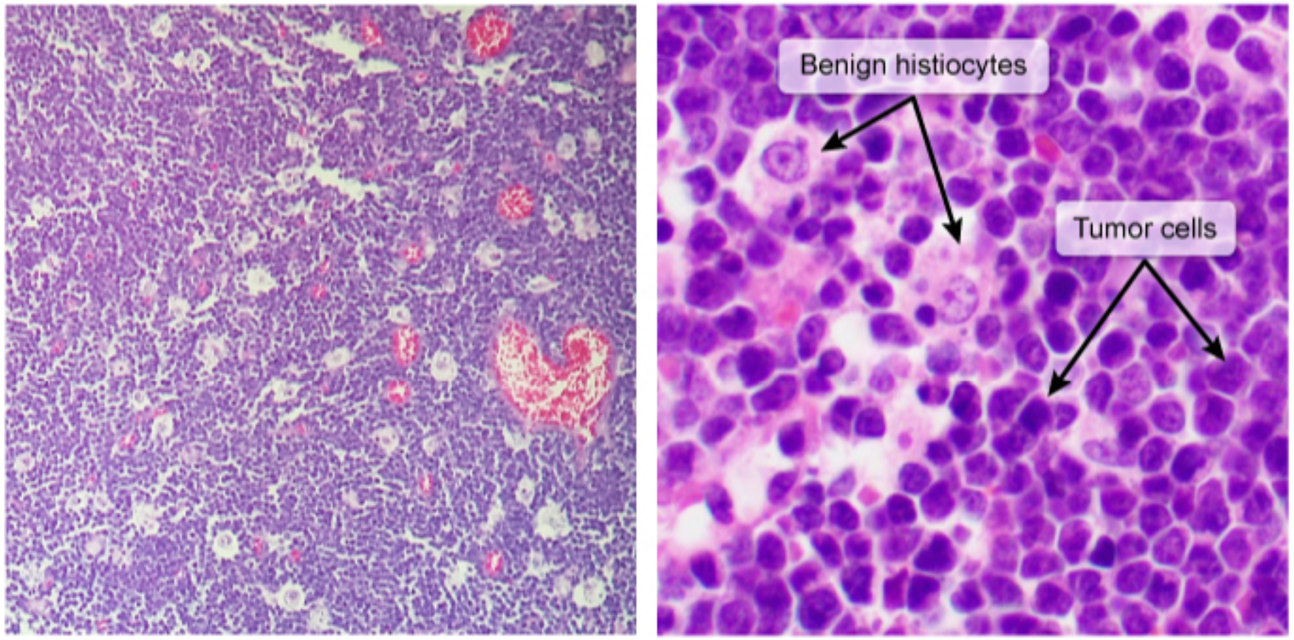

Lighter histiocytes in a field of darker tumor cells; "starry sky" appearance

©UWorld

Zoom In | Zoom Out | Reset | Add To Flash Card

References

9
10
11
12
13
14
15
16
17
18
19
20
21
22
23
24
25
26
27
28
29
30
31
32
33
34
35
36
37
38

Exhibit Display

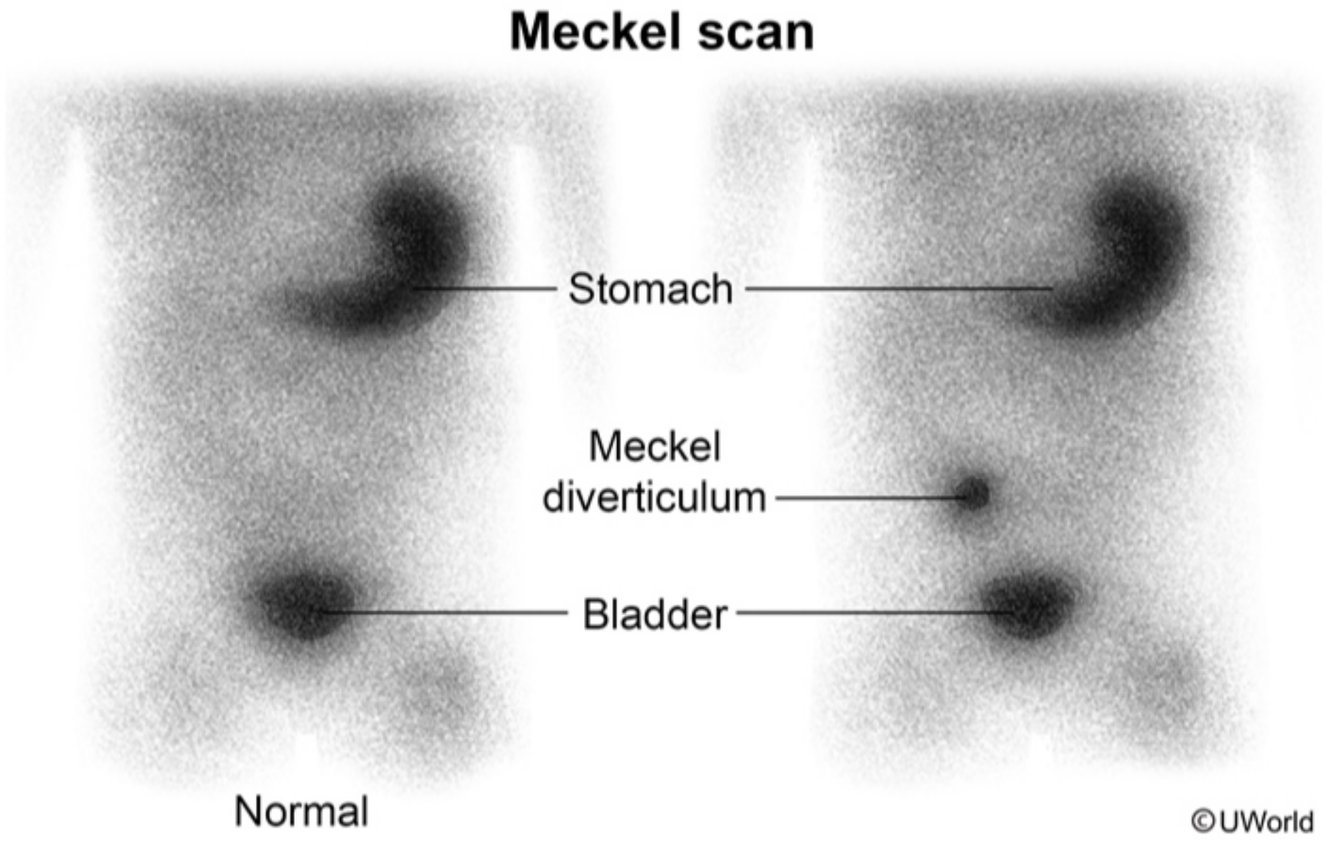

Zoom In | Zoom Out | Reset | Add To Flash Card

References

9
10
11
12
13
14
15
16
17
18
19
20
21
22
23
24
25
26
27
28
29
30
31
32
33
34
35
36
37
38

Meckel diverticulum is the **most common** pathologic lead point for intussusception and is a congenital anomaly of the gastrointestinal (GI) tract

Exhibit Display

Crohn disease

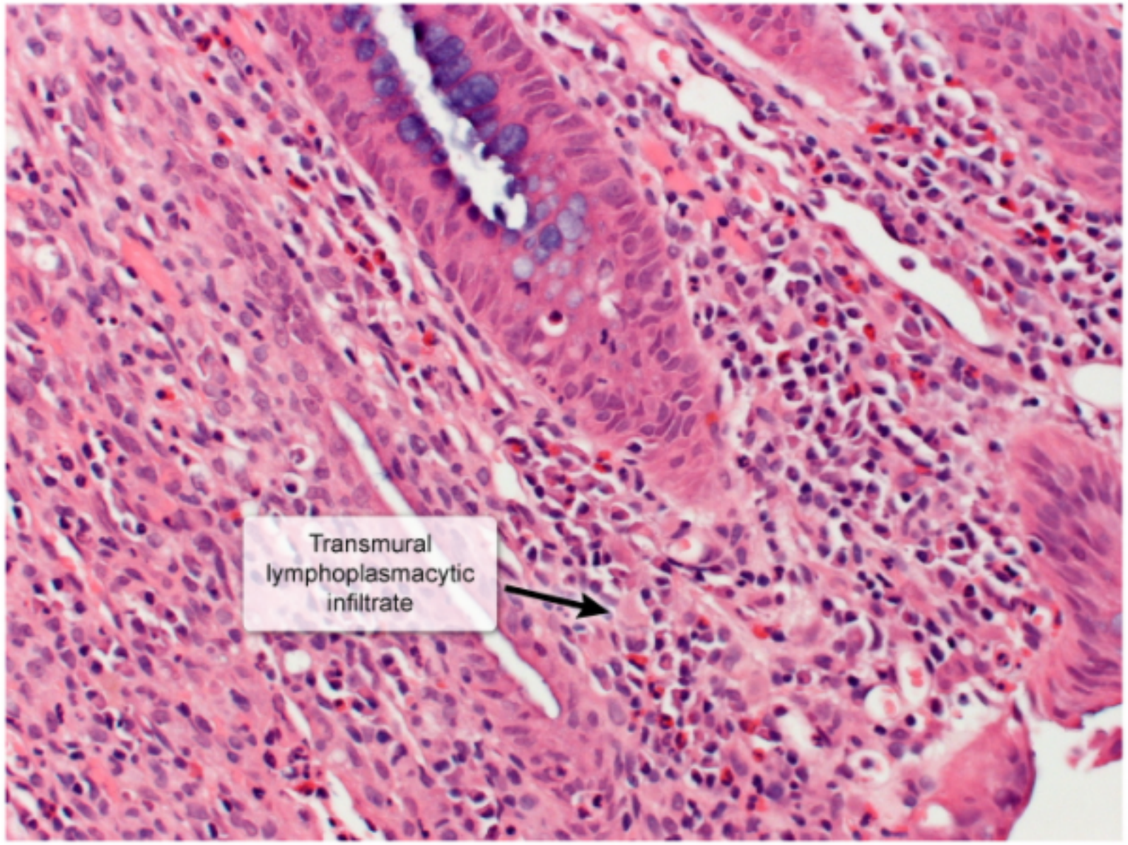

©UWorld

Zoom In | Zoom Out | Reset | Add To Flash Card

Copyright © UWorld. All rights reserved.

9
10
11
12
13
14
15
16
17
18
19
20
21
22
23
24
25
26
27
28
29
30
31
32
33
34
35
36
37
38

Meckel diverticulum is the **most common** pathologic lead point for intussusception and is a congenital anomaly of the gastrointestinal (GI) tract

Exhibit Display

Pseudomembranous colitis

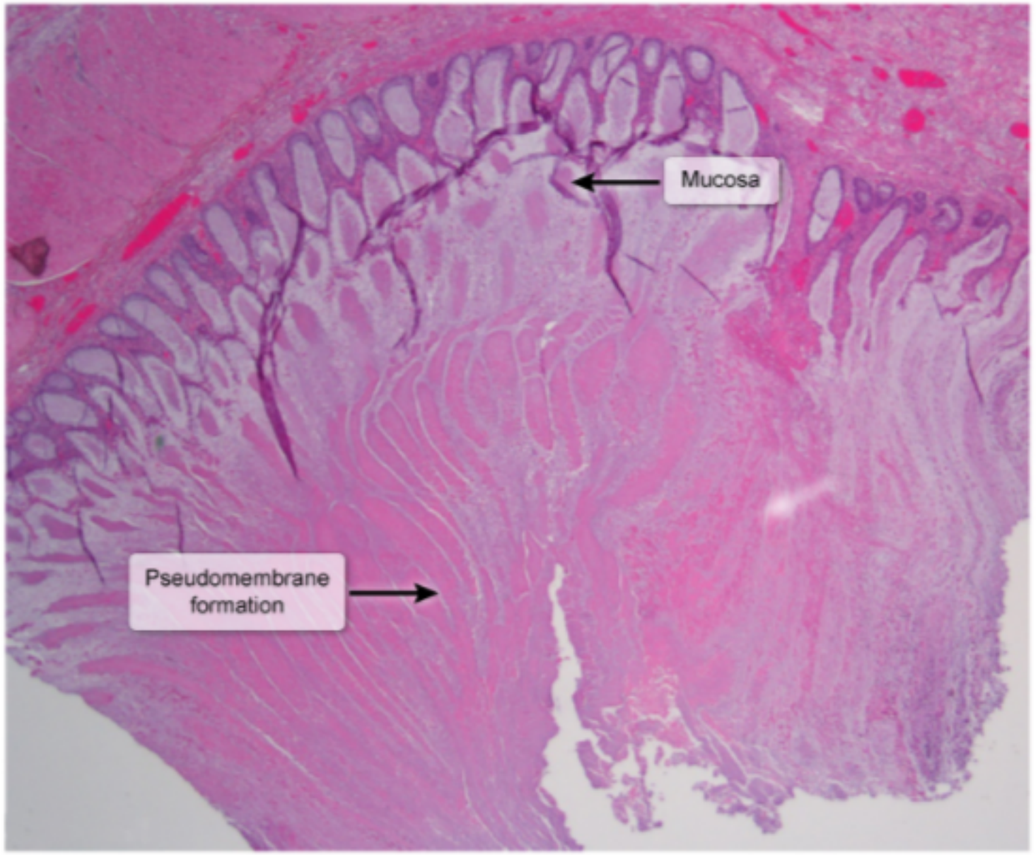

©UWorld

Zoom In | Zoom Out | Reset | Add To Flash Card

Copyright © UWorld. All rights reserved.

9, 10, 11, 12, 13, 14, 15, 16, 17, 18, 19, 20, 21, 22, 23, 24, 25, 26, 27, 28, 29, 30, 31, 32, 33, 34, 35, 36, 37, 38

A 45-year-old woman recently diagnosed with Sjögren's syndrome complains of severe pruritus that slowly progressed over the last year. She says that pruritus is especially prominent over palms and soles and is unbearable during the night. Laboratory testing shows:

Total bilirubin	1.0 mg/dL
Direct bilirubin	0.8 mg/dL
Alkaline phosphatase	720 U/L
Aspartate aminotransferase (SGOT)	48 U/L
Alanine aminotransferase (SGPT)	40 U/L

This patient most likely has which of the following conditions?

- A. Viral hepatitis B
- B. Viral hepatitis C
- C. Alcoholic hepatitis
- D. Budd-Chiari syndrome
- E. Primary biliary cholangitis
- F. Hemochromatosis
- G. Wilson's disease

Submit

9
10
11
12
13
14
15
16
17
18
19
20
21
22
23
24
25
26
27
28
29
30
31
32
33
34
35
36
37
38

Direct bilirubin	0.8 mg/dL
Alkaline phosphatase	720 U/L
Aspartate aminotransferase (SGOT)	48 U/L
Alanine aminotransferase (SGPT)	40 U/L

This patient most likely has which of the following conditions?

- A. Viral hepatitis B (0%)
- B. Viral hepatitis C (0%)
- C. Alcoholic hepatitis (2%)
- D. Budd-Chiari syndrome (3%)
- ✓ E. Primary biliary cholangitis (90%)
- F. Hemochromatosis (1%)
- G. Wilson's disease (0%)

Omitted
Correct answer
E

90%
Answered correctly

02 secs
Time Spent

04/06/2020
Last Updated

Explanation

9
10
11
12
13
14
15
16
17
18
19
20
21
22
23
24
25
26
27
28
29
30
31
32
33
34
35
36
37
38

Primary biliary cholangitis

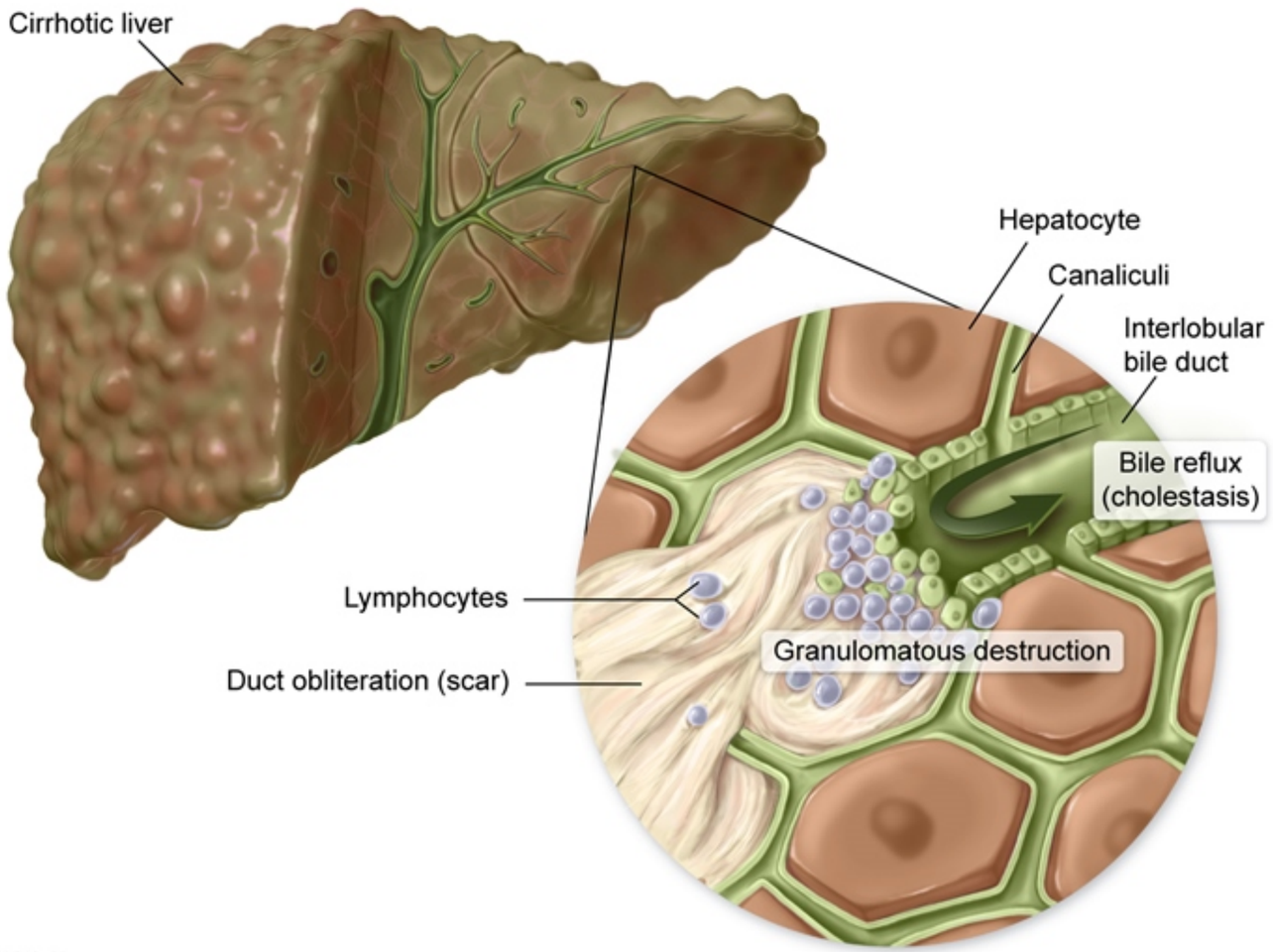

©UWorld

This patient is suffering from **primary biliary cholangitis** (PBC), a chronic liver disease characterized by autoimmune destruction of the intrahepatic bile ducts and cholestasis. The condition presents most commonly in **middle-aged women** and is insidious in onset. **Pruritus** is

9
10
11
12
13
14
15
16
17
18
19
20
21
22
23
24
25
26
27
28
29
30
31
32
33
34
35
36
37
38

This patient is suffering from **primary biliary cholangitis** (PBC), a chronic liver disease characterized by autoimmune destruction of the intrahepatic bile ducts and cholestasis. The condition presents most commonly in **middle-aged women** and is insidious in onset. **Pruritus** is usually the first symptom and may be very severe, especially at night. Fatigue is also often reported. Physical findings typically include hepatosplenomegaly and xanthomatous lesions in the eyelids or in the skin and tendons. As the disease progresses, jaundice, steatorrhea, and portal hypertension may develop.

Abnormalities on laboratory testing are consistent with cholestasis and include **elevated alkaline phosphatase** cholesterol, and bile acids (causing pruritus) due to spillage of bile into the blood. Diagnosis is confirmed with demonstration of **anti-mitochondrial antibodies** in the serum. Associated conditions include **autoimmune diseases** such as Sjögren's syndrome, Raynaud's syndrome, systemic sclerosis, and Hashimoto's thyroiditis.

(Choices A and B) Expected laboratory findings in a patient with acute viral hepatitis include significant elevations in ALT and AST (with ALT > AST), followed by rises in bilirubin.

(Choice C) Alcoholic hepatitis is typically associated with a significant drinking history and is commonly characterized by an AST:ALT ratio greater than 2:1.

(Choice D) Budd-Chiari syndrome arises secondary to thrombotic occlusion of the hepatic veins and/or the intra- or suprahepatic inferior vena cava. The venous occlusion causes the sinusoidal pressure to increase, ultimately leading to portal hypertension, ascites, hepatomegaly, and splenomegaly.

(Choices F and G) Hemochromatosis and Wilson's disease cause hepatocellular injury and thus are associated with elevated ALT and AST rather than cholestatic picture.

Educational objective:
Primary biliary cholangitis is a chronic liver disease characterized by autoimmune destruction of the intrahepatic bile ducts and cholestasis (elevated alkaline phosphatase). The condition is most common in middle-aged women, with severe pruritus (especially at night) often one of the first reported symptoms.

Pathology | Gastrointestinal & Nutrition | Primary biliary cholangitis

9
10
11
12
13
14
15
16
17
18
19
20
21
22
23
24
25
26
27
28
29
30
31
32
33
34
35
36
37
38

hepatosplenomegaly and xanthomatous lesions in the eyelids or in the skin and tendons. As the disease progresses, jaundice, steatorrhea, and portal hypertension may develop.

Abnormalities on laboratory testing are consistent with cholestasis and include **elevated alkaline phosphatase** cholesterol, and bile acids (causing pruritus) due to spillage of bile into the blood. Diagnosis is confirmed with demonstration of **anti-mitochondrial antibodies** in the serum. Associated conditions include **autoimmune diseases** such as Sjögren's syndrome, Raynaud's syndrome, systemic sclerosis, and Hashimoto's thyroiditis.

(Choices A and B) Expected laboratory findings in a patient with acute viral hepatitis include significant elevations in ALT and AST (with ALT > AST), followed by rises in bilirubin.

(Choice C) Alcoholic hepatitis is typically associated with a significant drinking history and is commonly characterized by an AST:ALT ratio greater than 2:1.

(Choice D) Budd-Chiari syndrome arises secondary to thrombotic occlusion of the hepatic veins and/or the intra- or suprahepatic inferior vena cava. The venous occlusion causes the sinusoidal pressure to increase, ultimately leading to portal hypertension, ascites, hepatomegaly, and splenomegaly.

(Choices F and G) Hemochromatosis and Wilson's disease cause hepatocellular injury and thus are associated with elevated ALT and AST rather than cholestatic picture.

Educational objective:
Primary biliary cholangitis is a chronic liver disease characterized by autoimmune destruction of the intrahepatic bile ducts and cholestasis (elevated alkaline phosphatase). The condition is most common in middle-aged women, with severe pruritus (especially at night) often one of the first reported symptoms.

Pathology	Gastrointestinal & Nutrition	Primary biliary cholangitis
Subject	System	Topic

Copyright © UWorld. All rights reserved.

9
10
11
12
13
14
15
16
17
18
19
20
21
22
23
24
25
26
27
28
29
30
31
32
33
34
35
36
37
38

A 30-year-old man comes to the emergency department with a 4-day history of progressively worsening abdominal pain and bloody diarrhea. He was started on mesalamine therapy 6 months ago after being diagnosed with ulcerative colitis but has been noncompliant with treatment. His temperature is 38.8 C (102 F), blood pressure is 100/70 mm Hg, and pulse is 130/min. The patient is lethargic and has dry mucous membranes. There is marked abdominal distension and tenderness without rebound or guarding. Rectal examination shows guaiac-positive, maroon-colored, liquid stool. Which of the following is the best next step in this patient's workup?

A. Abdominal ultrasonography

B. Barium enema

C. Colonoscopy

D. Plain abdominal x-ray

E. Small-bowel contrast study

Submit

9
10
11
12
13
14
15
16
17
18
19
20
21
22
23
24
25
26
27
28
29
30
31
32
33
34
35
36
37
38

A 30-year-old man comes to the emergency department with a 4-day history of progressively worsening abdominal pain and bloody diarrhea. He was started on mesalamine therapy 6 months ago after being diagnosed with ulcerative colitis but has been noncompliant with treatment. His temperature is 38.8 C (102 F), blood pressure is 100/70 mm Hg, and pulse is 130/min. The patient is lethargic and has dry mucous membranes. There is marked abdominal distension and tenderness without rebound or guarding. Rectal examination shows guaiac-positive, maroon-colored, liquid stool. Which of the following is the best next step in this patient's workup?

- A. Abdominal ultrasonography (10%)
- B. Barium enema (8%)
- C. Colonoscopy (42%)
- ✓ D. Plain abdominal x-ray (35%)
- E. Small-bowel contrast study (4%)

Omitted
Correct answer
D

35%
Answered correctly

01 sec
Time Spent

01/28/2020
Last Updated

Explanation

Toxic megacolon

Settings

9
10
11
12
13
14
15
16
17
18
19
20
21
22
23
24
25
26
27
28
29
30
31
32
33
34
35
36
37
38

Item 36 of 38
Question Id: 410

Mark | Previous | Next | Full Screen | Tutorial | Lab Values | Notes | Calculator | Reverse Color | Text Zoom | Settings

Toxic megacolon

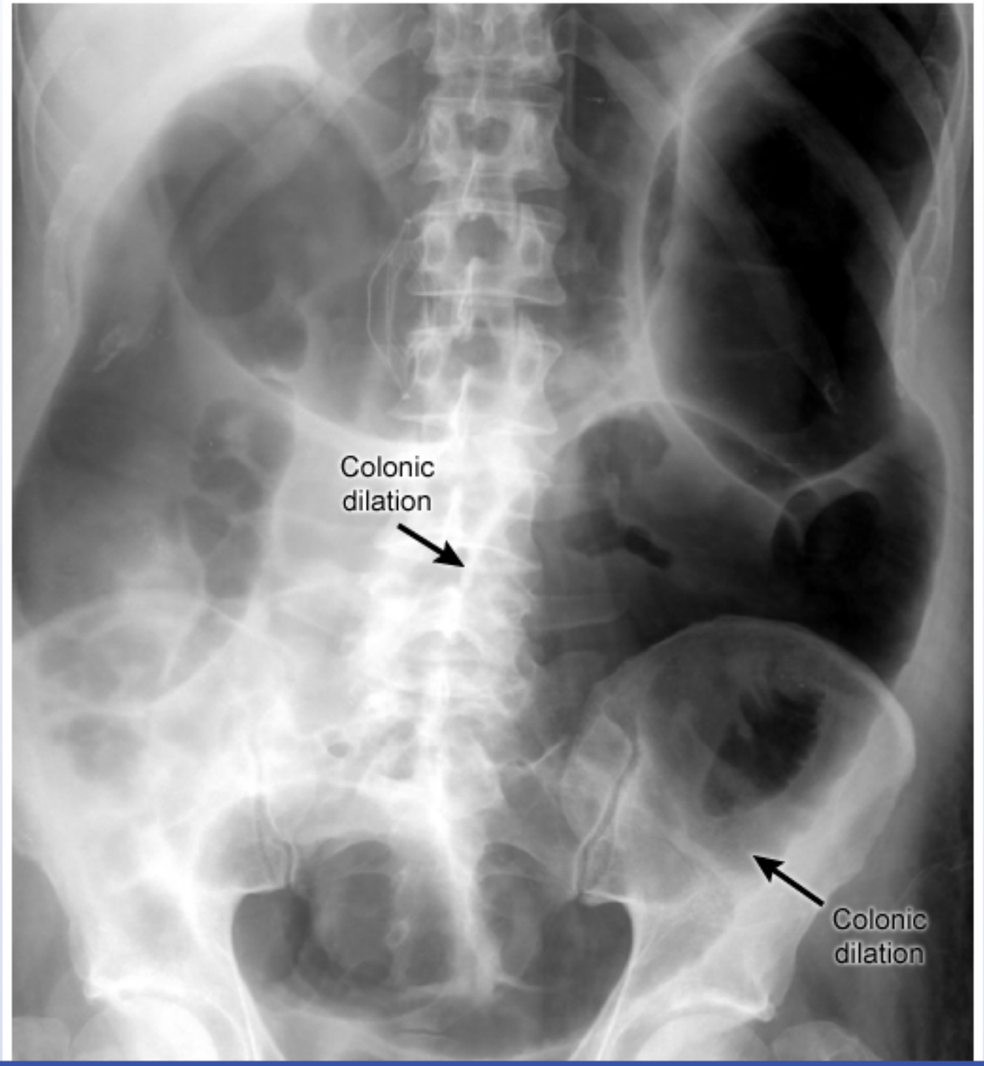

Block Time Remaining: 00:01:21
TUTOR

3 | Feedback | Suspend | End Block

9
10
11
12
13
14
15
16
17
18
19
20
21
22
23
24
25
26
27
28
29
30
31
32
33
34
35
36
37
38

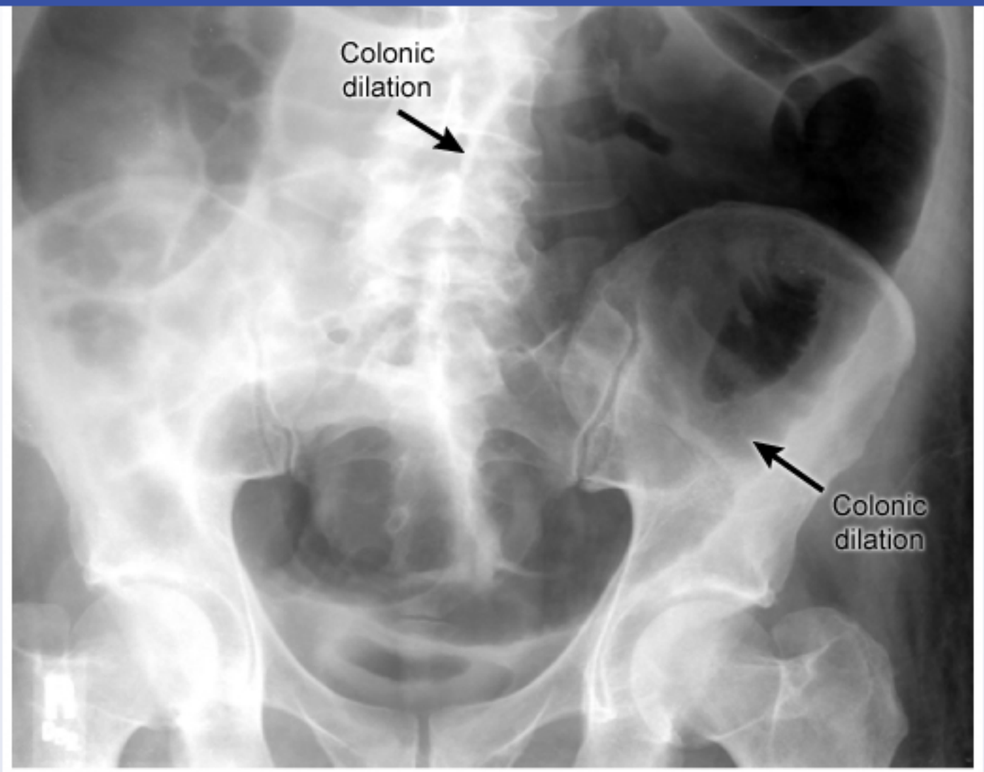

©UWorld

This patient with abdominal pain/distension, bloody diarrhea, fever, and signs of shock (eg, hypotension, tachycardia) in the setting of untreated ulcerative colitis likely has **toxic megacolon**. This is a common life-threatening complication of inflammatory bowel disease and is seen more frequently in **ulcerative colitis** than in Crohn disease. Toxic megacolon can also be associated with *Clostridium difficile* infection and other forms of infectious colitis.

Severe, occasionally transmural inflammation causes release of inflammatory mediators, bacterial products, and increased nitric oxide, which contribute to colonic smooth muscle paralysis. Rapid colonic distension ensues, thinning the intestinal wall and making it prone to perforation. Plain **abdominal x-ray** is the preferred diagnostic imaging study as it may show **colonic dilation** (as seen above) with multiple air-fluid levels (not seen in this image). Free air may also be visualized in the setting of intestinal rupture, which presents with generalized peritonitis (eg, abdominal

9
10
11
12
13
14
15
16
17
18
19
20
21
22
23
24
25
26
27
28
29
30
31
32
33
34
35
36
37
38

This patient with abdominal pain/distension, bloody diarrhea, fever, and signs of shock (eg, hypotension, tachycardia) in the setting of untreated ulcerative colitis likely has **toxic megacolon**. This is a common life-threatening complication of inflammatory bowel disease and is seen more frequently in **ulcerative colitis** than in Crohn disease. Toxic megacolon can also be associated with *Clostridium difficile* infection and other forms of infectious colitis.

Severe, occasionally transmural inflammation causes release of inflammatory mediators, bacterial products, and increased nitric oxide, which contribute to colonic smooth muscle paralysis. Rapid colonic distension ensues, thinning the intestinal wall and making it prone to perforation. Plain **abdominal x-ray** is the preferred diagnostic imaging study as it may show **colonic dilation** (as seen above) with multiple air-fluid levels (not seen in this image). Free air may also be visualized in the setting of intestinal rupture, which presents with generalized peritonitis (eg, abdominal rebound tenderness/guarding).

(Choice A) Abdominal ultrasonography is not typically performed to diagnose toxic megacolon. It is usually obtained in patients with acute right upper quadrant abdominal pain (eg, due to cholecystitis, ascending cholangitis) or suspected nephrolithiasis. It is also helpful in the setting of acute abdominal trauma to identify intraperitoneal free fluid.

(Choices B and C) Barium enema and colonoscopy are normally contraindicated in patients with suspected toxic megacolon as these may cause perforation.

(Choice E) Small-bowel contrast studies can be useful in the evaluation of small-bowel obstruction (eg, abdominal pain/distension, nausea, vomiting). However, this patient's history of untreated ulcerative colitis and bloody diarrhea is more consistent with toxic megacolon, which involves the large intestine.

Educational objective:
Toxic megacolon is a well-recognized complication of ulcerative colitis. Patients typically present with abdominal pain/distension, bloody diarrhea, fever, and signs of shock. Plain abdominal x-ray is the preferred diagnostic imaging study. Barium contrast studies and colonoscopy are contraindicated due to the risk of perforation.

References

- Toxic megacolon.
- A new look at toxic megacolon: an update and review of incidence, etiology, pathogenesis, and management.

9
10
11
12
13
14
15
16
17
18
19
20
21
22
23
24
25
26
27
28
29
30
31
32
33
34
35
36
37
38

Severe, occasionally transmural inflammation causes release of inflammatory mediators, bacterial products, and increased nitric oxide, which contribute to colonic smooth muscle paralysis. Rapid colonic distension ensues, thinning the intestinal wall and making it prone to perforation. Plain **abdominal x-ray** is the preferred diagnostic imaging study as it may show **colonic dilation** (as seen above) with multiple air-fluid levels (not seen in this image). Free air may also be visualized in the setting of intestinal rupture, which presents with generalized peritonitis (eg, abdominal rebound tenderness/guarding).

(Choice A) Abdominal ultrasonography is not typically performed to diagnose toxic megacolon. It is usually obtained in patients with acute right upper quadrant abdominal pain (eg, due to cholecystitis, ascending cholangitis) or suspected nephrolithiasis. It is also helpful in the setting of acute abdominal trauma to identify intraperitoneal free fluid.

(Choices B and C) Barium enema and colonoscopy are normally contraindicated in patients with suspected toxic megacolon as these may cause perforation.

(Choice E) Small-bowel contrast studies can be useful in the evaluation of small-bowel obstruction (eg, abdominal pain/distension, nausea, vomiting). However, this patient's history of untreated ulcerative colitis and bloody diarrhea is more consistent with toxic megacolon, which involves the large intestine.

Educational objective:
Toxic megacolon is a well-recognized complication of ulcerative colitis. Patients typically present with abdominal pain/distension, bloody diarrhea, fever, and signs of shock. Plain abdominal x-ray is the preferred diagnostic imaging study. Barium contrast studies and colonoscopy are contraindicated due to the risk of perforation.

References

- Toxic megacolon.
- A new look at toxic megacolon: an update and review of incidence, etiology, pathogenesis, and management.

Pathology	Gastrointestinal & Nutrition	Toxic megacolon
Subject	System	Topic

Which of the following is most likely responsible for this patient's symptoms?

A. Altered enterohepatic circulation of bilirubin

B. Biliary stasis due to lack of enteral stimulation

C. Decreased gallbladder motility due to denervation

D. Impaired bile acid synthesis

E. Increased cholesterol synthesis

9
10
11
12
13
14
15
16
17
18
19
20
21
22
23
24
25
26
27
28
29
30
31
32
33
34
35
36
37
38

Which of the following is most likely responsible for this patient's symptoms?

A. Altered enterohepatic circulation of bilirubin

B. Biliary stasis due to lack of enteral stimulation

C. Decreased gallbladder motility due to denervation

D. Impaired bile acid synthesis

E. Increased cholesterol synthesis

F. Increased efflux of bilirubin into bile

Submit

Which of the following is most likely responsible for this patient's symptoms?

- A. Altered enterohepatic circulation of bilirubin (14%)
- B. Biliary stasis due to lack of enteral stimulation (5%)
- C. Decreased gallbladder motility due to denervation (2%)
- D. Impaired bile acid synthesis (5%)
- E. Increased cholesterol synthesis (3%)
- ✓ F. Increased efflux of bilirubin into bile (68%)

Omitted
Correct answer

68%
Answered correctly

06 secs
Time Spent

06/05/2020
Last Updated

Pathogenesis of pigment stones

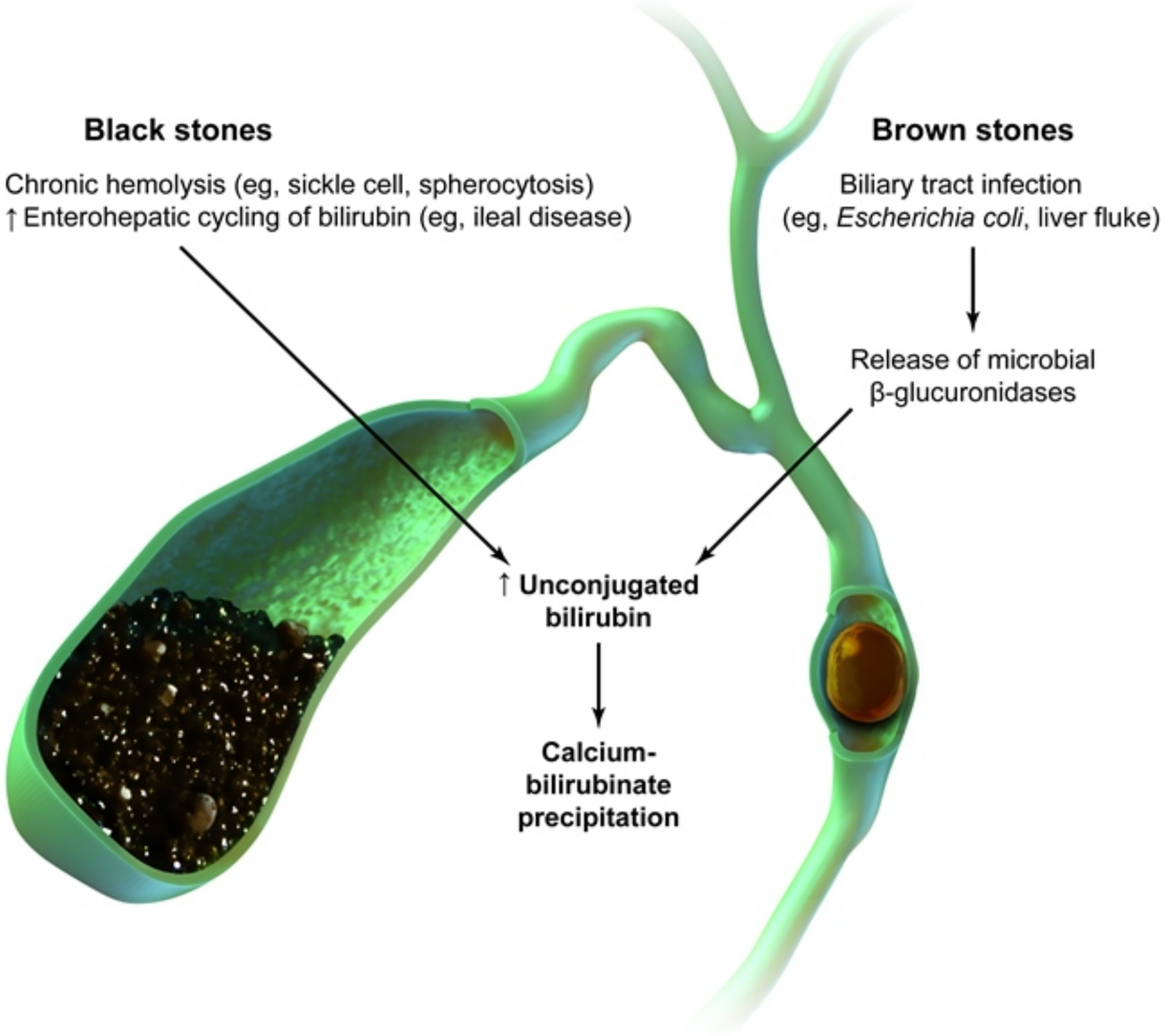

©UWorld

This patient with fever, right upper quadrant pain, and leukocytosis has **acute cholecystitis**. Cholecystitis is inflammation of the gallbladder that usually occurs when gallstones obstruct the cystic duct. Gallstones form due to supersaturation of bile constituents (eg, cholesterol, bilirubin), which then crystalize out of solution with other bile components (eg, mucin, calcium, proteins) to produce stones.

Black gallstones, as seen in this patient, form due to the **supersaturation of bilirubin**, which precipitates with calcium to form multiple small calcium bilirubinate stones. Bilirubin supersaturation occurs through the following mechanisms:

- **Increased bilirubin production:** Chronic hemolysis, as seen in **sickle cell anemia**, hereditary spherocytosis, and thalassemia, increases circulating levels of free bilirubin, which is taken up by the liver and **excreted into bile**.
- **Altered enterohepatic circulation** of bilirubin: Ileal disease (eg, Crohn disease) or resection allows bile acids, which are normally reabsorbed in the ileum, to spill into the colon. There, bile acids solubilize unconjugated bilirubin, allowing its reabsorption and concentration within the bile **(Choice A)**.

This patient with sickle cell anemia most likely has chronic hemolysis, which has increased bilirubin efflux into the bile, promoting formation of black stones.

(Choices B and C) Biliary stasis promotes gallstone formation by providing a favorable environment for crystal nucleation and aggregation. Stasis can occur due to gallbladder denervation (eg, transection of the nerves that control gallbladder contraction) or decreased stimulation by enterocytes during prolonged fasting (cholecystokinin is released in response to food). However, stasis usually promotes the formation of yellow cholesterol stones, and this patient did not have prolonged fasting or surgery prior to developing her symptoms.

(Choice D) Cirrhosis can also occasionally promote the formation of black stones due to impaired bile acid synthesis and hyperbilirubinemia (due to cholestasis). However, this patient does not have a history of cirrhosis or stigmata of chronic liver disease (eg, jaundice).

(Choice E) Increased cholesterol synthesis results in the formation of yellow cholesterol gallstones. This typically occurs in the setting of obesity, diabetes mellitus, or certain medications (eg, estrogen-containing oral contraceptives).

Educational objective:
Black gallstones form due to supersaturation of the bile with bilirubin, which precipitates with calcium to form calcium bilirubinate stones. This

Black gallstones, as seen in this patient, form due to the **supersaturation of bilirubin**, which precipitates with calcium to form multiple small calcium bilirubinate stones. Bilirubin supersaturation occurs through the following mechanisms:

- **Increased bilirubin production:** Chronic hemolysis, as seen in **sickle cell anemia**, hereditary spherocytosis, and thalassemia, increases circulating levels of free bilirubin, which is taken up by the liver and **excreted into bile**.
- **Altered enterohepatic circulation** of bilirubin: Ileal disease (eg, Crohn disease) or resection allows bile acids, which are normally reabsorbed in the ileum, to spill into the colon. There, bile acids solubilize unconjugated bilirubin, allowing its reabsorption and concentration within the bile **(Choice A)**.

This patient with sickle cell anemia most likely has chronic hemolysis, which has increased bilirubin efflux into the bile, promoting formation of black stones.

(Choices B and C) Biliary stasis promotes gallstone formation by providing a favorable environment for crystal nucleation and aggregation. Stasis can occur due to gallbladder denervation (eg, transection of the nerves that control gallbladder contraction) or decreased stimulation by enterocytes during prolonged fasting (cholecystokinin is released in response to food). However, stasis usually promotes the formation of yellow cholesterol stones, and this patient did not have prolonged fasting or surgery prior to developing her symptoms.

(Choice D) Cirrhosis can also occasionally promote the formation of black stones due to impaired bile acid synthesis and hyperbilirubinemia (due to cholestasis). However, this patient does not have a history of cirrhosis or stigmata of chronic liver disease (eg, jaundice).

(Choice E) Increased cholesterol synthesis results in the formation of yellow cholesterol gallstones. This typically occurs in the setting of obesity, diabetes mellitus, or certain medications (eg, estrogen-containing oral contraceptives).

Educational objective:
Black gallstones form due to supersaturation of the bile with bilirubin, which precipitates with calcium to form calcium bilirubinate stones. This typically occurs in the setting of chronic hemolysis (eg, sickle cell disease) or altered enterohepatic circulation of bilirubin (eg, Crohn disease, ileal resection).

References

- Gallstones.

- **Altered enterohepatic circulation** of bilirubin: Ileal disease (eg, Crohn disease) or resection allows bile acids, which are normally reabsorbed in the ileum, to spill into the colon. There, bile acids solubilize unconjugated bilirubin, allowing its reabsorption and concentration within the bile **(Choice A)**.

This patient with sickle cell anemia most likely has chronic hemolysis, which has increased bilirubin efflux into the bile, promoting formation of black stones.

(Choices B and C) Biliary stasis promotes gallstone formation by providing a favorable environment for crystal nucleation and aggregation. Stasis can occur due to gallbladder denervation (eg, transection of the nerves that control gallbladder contraction) or decreased stimulation by enterocytes during prolonged fasting (cholecystokinin is released in response to food). However, stasis usually promotes the formation of yellow cholesterol stones, and this patient did not have prolonged fasting or surgery prior to developing her symptoms.

(Choice D) Cirrhosis can also occasionally promote the formation of black stones due to impaired bile acid synthesis and hyperbilirubinemia (due to cholestasis). However, this patient does not have a history of cirrhosis or stigmata of chronic liver disease (eg, jaundice).

(Choice E) Increased cholesterol synthesis results in the formation of yellow cholesterol gallstones. This typically occurs in the setting of obesity, diabetes mellitus, or certain medications (eg, estrogen-containing oral contraceptives).

Educational objective:
Black gallstones form due to supersaturation of the bile with bilirubin, which precipitates with calcium to form calcium bilirubinate stones. This typically occurs in the setting of chronic hemolysis (eg, sickle cell disease) or altered enterohepatic circulation of bilirubin (eg, Crohn disease, ileal resection).

References

- Gallstones.

Pathology	Gastrointestinal & Nutrition	Gallstone disease
Subject	System	Topic

Copyright © UWorld. All rights reserved.

A 58-year-old woman comes to the office due to a week of pain with swallowing. Her symptoms have progressively worsened, and now she cannot eat comfortably. The patient has a history of hypertension, osteoporosis, and primary biliary cholangitis progressing to cirrhosis. She underwent a liver transplant 2 years ago and is on immunosuppressive therapy. She does not use tobacco, alcohol, or illicit drugs. Vital signs are within normal limits. The oropharynx is normal in appearance. Cardiopulmonary examination is unremarkable. The patient has epigastric tenderness with no abdominal distension or guarding. Upper endoscopy shows several small esophageal ulcerations with distinct borders located in the middle and lower portions of the esophagus. A biopsy taken at the edge of an ulcer shows giant cells and intranuclear eosinophilic inclusions. Which of the following is the most appropriate treatment for this patient?

A. Acyclovir
B. Alendronate
C. Azithromycin
D. Fluconazole
E. Misoprostol
F. Omeprazole
G. Tenofovir

Submit

9
10
11
12
13
14
15
16
17
18
19
20
21
22
23
24
25
26
27
28
29
30
31
32
33
34
35
36
37
38

A 58-year-old woman comes to the office due to a week of pain with swallowing. Her symptoms have progressively worsened, and now she cannot eat comfortably. The patient has a history of hypertension, osteoporosis, and primary biliary cholangitis progressing to cirrhosis. She underwent a liver transplant 2 years ago and is on immunosuppressive therapy. She does not use tobacco, alcohol, or illicit drugs. Vital signs are within normal limits. The oropharynx is normal in appearance. Cardiopulmonary examination is unremarkable. The patient has epigastric tenderness with no abdominal distension or guarding. Upper endoscopy shows several small esophageal ulcerations with distinct borders located in the middle and lower portions of the esophagus. A biopsy taken at the edge of an ulcer shows giant cells and intranuclear eosinophilic inclusions. Which of the following is the most appropriate treatment for this patient?

- ✓ A. Acyclovir (70%)
- B. Alendronate (1%)
- C. Azithromycin (2%)
- D. Fluconazole (4%)
- E. Misoprostol (2%)
- F. Omeprazole (8%)
- G. Tenofovir (10%)

Omitted
Correct answer
A

70%
Answered correctly

02 secs
Time Spent

02/12/2020
Last Updated

Explanation

9
10
11
12
13
14
15
16
17
18
19
20
21
22
23
24
25
26
27
28
29
30
31
32
33
34
35
36
37
38

Esophagitis in an immunocompromised patient			
Pathogen	**Endoscopic findings**	**Microscopic findings**	**Treatment**
Candida albicans	Patches of adherent, grey/white pseudomembranes on erythematous mucosa	Yeast cells & pseudohyphae invading mucosal cells	Fluconazole
HSV	Small vesicles → "punched-out" ulcers	Eosinophilic intranuclear inclusions (Cowdry type A) in multinuclear squamous cells at ulcer margins	Acyclovir
CMV	Large, linear ulcerations	Intranuclear & cytoplasmic inclusions	Ganciclovir

CMV = cytomegalovirus; **HSV** = herpes simplex virus.

Esophagitis is usually the result of a noninfectious process such as gastroesophageal reflux disease. However, patients with impaired cell-mediated immunity (eg, chemotherapy, **post-transplantation**, AIDS) are also at risk for esophageal infections. The leading causes are *Candida*, cytomegalovirus, and herpes simplex virus (HSV).

HSV esophagitis usually presents with significant pain and discomfort with swallowing. Endoscopy typically reveals small vesicles or "**punched-out**" ulcers on the esophageal mucosa. Classic HSV findings on biopsy include multinucleated giant cells and eosinophilic intranuclear inclusion bodies (Cowdry type A). Treatment with oral **acyclovir** usually resolves the active infection, but latent virus can reactivate in the future, leading to recurrent symptoms.

(Choice B) Alendronate is a bisphosphonate used in the treatment of osteoporosis. Bisphosphonates can cause medication-induced esophagitis and could worsen this patient's symptoms.

(Choice C) Azithromycin can be used as part of the treatment for disseminated mycobacterium avium complex, which often involves the gastrointestinal tract. However, this condition usually occurs in those with advanced AIDS; the esophagus is affected less commonly than the intestine; and endoscopy typically reveals whitish-yellow nodules on the mucosa.

(Choice D) Fluconazole is used for candidal esophagitis. Endoscopy would reveal white pseudomembranes on the esophageal mucosa, and

Esophagitis is usually the result of a noninfectious process such as gastroesophageal reflux disease. However, patients with impaired cell-mediated immunity (eg, chemotherapy, **post-transplantation**, AIDS) are also at risk for esophageal infections. The leading causes are *Candida*, cytomegalovirus, and herpes simplex virus (HSV).

HSV esophagitis usually presents with significant pain and discomfort with swallowing. Endoscopy typically reveals small vesicles or "**punched-out**" ulcers on the esophageal mucosa. Classic HSV findings on biopsy include multinucleated giant cells and eosinophilic intranuclear inclusion bodies (Cowdry type A). Treatment with oral **acyclovir** usually resolves the active infection, but latent virus can reactivate in the future, leading to recurrent symptoms.

(Choice B) Alendronate is a bisphosphonate used in the treatment of osteoporosis. Bisphosphonates can cause medication-induced esophagitis and could worsen this patient's symptoms.

(Choice C) Azithromycin can be used as part of the treatment for disseminated mycobacterium avium complex, which often involves the gastrointestinal tract. However, this condition usually occurs in those with advanced AIDS; the esophagus is affected less commonly than the intestine; and endoscopy typically reveals whitish-yellow nodules on the mucosa.

(Choice D) Fluconazole is used for candidal esophagitis. Endoscopy would reveal white pseudomembranes on the esophageal mucosa, and histopathology would show yeasts with pseudohyphae.

(Choice E) Misoprostol is a prostaglandin analogue that significantly reduces gastric acid secretion and is sometimes used to prevent ulcers due to nonsteroidal antiinflammatory medication.

(Choice F) Proton pump inhibitors (eg, omeprazole) are used to treat erosive esophagitis from chronic reflux. Erosive esophagitis typically causes irregular ulcers along the esophageal mucosa, and biopsy would demonstrate inflammatory exudates and fibrinoid necrosis.

(Choice G) Tenofovir is an antiviral agent that can be used for HIV and chronic hepatitis B infections. Although tenofovir is an antiviral medication, it is not effective against HSV.

Educational objective:
Herpes simplex virus esophagitis is most common in those with impaired cell-mediated immunity. Endoscopy typically reveals small vesicles and "punched-out" ulcers. Findings on biopsy usually include multinucleated giant cells and eosinophilic intranuclear inclusions (Cowdry type A

Settings

9
10
11
12
13
14
15
16
17
18
19
20
21
22
23
24
25
26
27
28
29
30
31
32
33
34
35
36
37
38

Item 38 of 38
Question Id: 14891

Mark | Previous | Next | Full Screen | Tutorial | Lab Values | Notes | Calculator | Reverse Color | Text Zoom | Settings

Esophagitis is usually the result of a noninfectious process such as gastroesophageal reflux disease. However, patients with impaired cell-

Exhibit Display

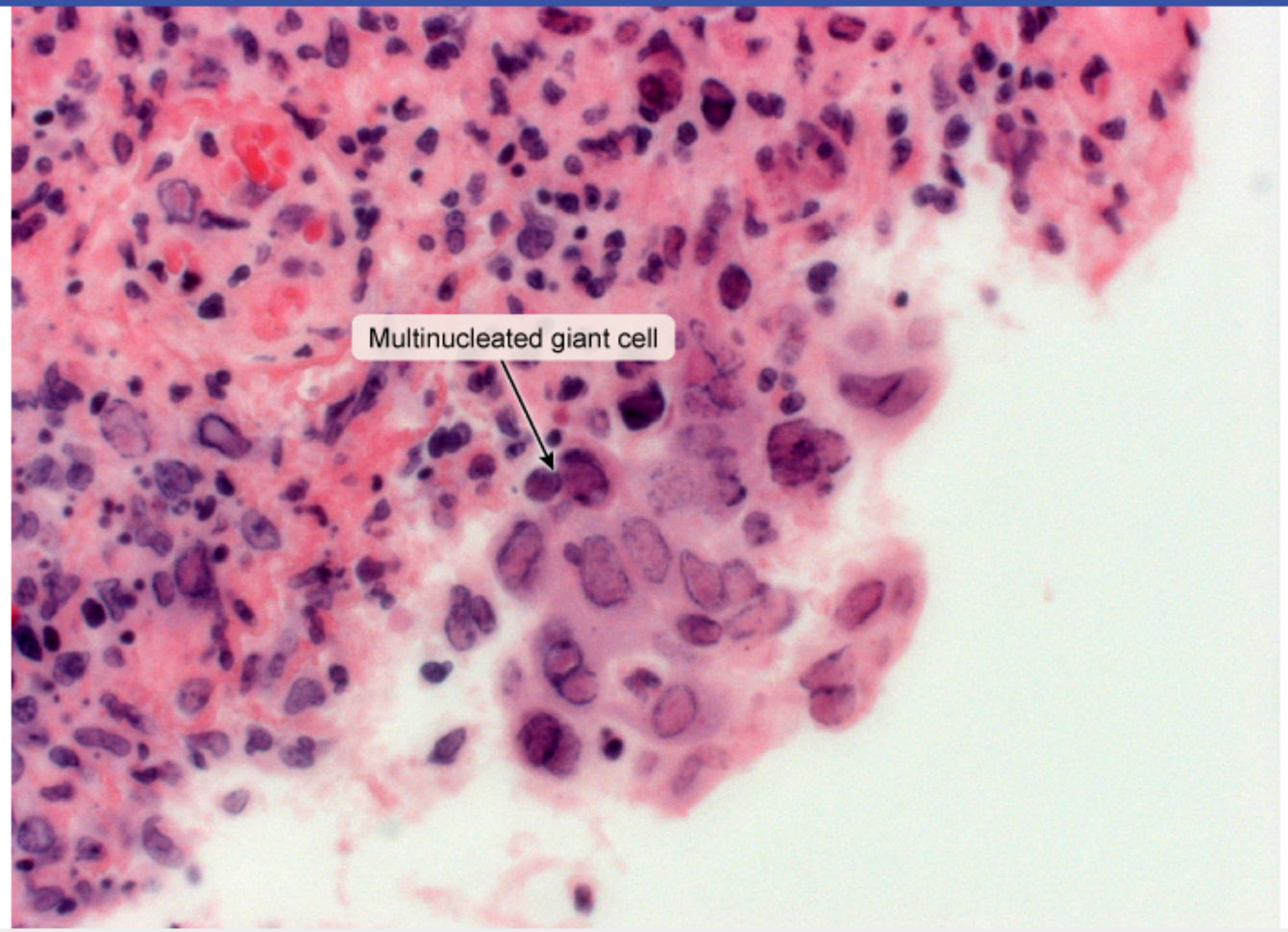

Zoom In | Zoom Out | Reset | Add To New Card | Existing Card

punched out ulcers. Findings on biopsy usually include multinucleated giant cells and eosinophilic intranuclear inclusions (Cowdry type A

Block Time Remaining: 00:01:29
TUTOR

3 | Feedback | Suspend | End Block

9
10
11
12
13
14
15
16
17
18
19
20
21
22
23
24
25
26
27
28
29
30
31
32
33
34
35
36
37
38

Exhibit Display

Candida Candida Esophagitis Candida esophagitis

Zoom In | Zoom Out | Reset | Add To New Card | Existing Card

Copyright © UWorld. All rights reserved.

Settings

9
10
11
12
13
14
15
16
17
18
19
20
21
22
23
24
25
26
27
28
29
30
31
32
33
34
35
36
37
38

Item 38 of 38
Question Id: 14891

Mark | Previous | Next | Full Screen | Tutorial | Lab Values | Notes | Calculator | Reverse Color | Text Zoom | Settings

Exhibit Display

Candida Candida Esophagitis Candida esophagitis

Zoom In | Zoom Out | Reset | Add To New Card | Existing Card

Copyright © UWorld. All rights reserved.

Block Time Remaining: 00:01:29
TUTOR

3 | Feedback | Suspend | End Block

9
10
11
12
13
14
15
16
17
18
19
20
21
22
23
24
25
26
27
28
29
30
31
32
33
34
35
36
37
38

Exhibit Display

Candida Candida Esophagitis Candida esophagitis

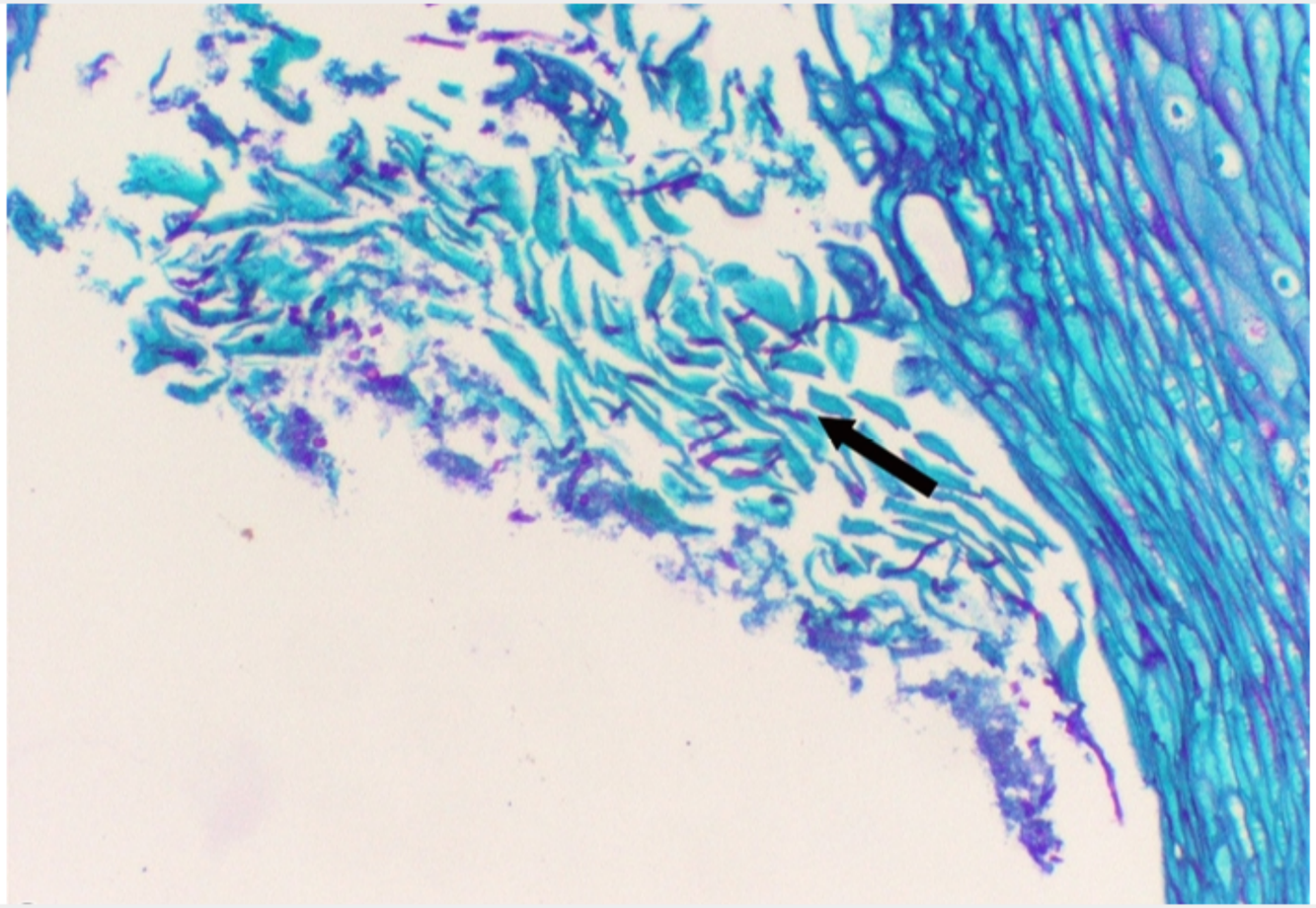

Zoom In | Zoom Out | Reset | Add To New Card | Existing Card

Copyright © UWorld. All rights reserved.